



PATIENT

Harry Shook

SPECIES

Feline

BREED

Domesetic longhair

SEX

Neutered male

AGE

8 years

WEIGHT

9.2 lbs

INTERPRETED BY

Eric Lindquist, DMV
DABVP, Cert. IVUSS

IMAGING PERFORMED BY

Dr. Harris

HOSPITAL NAME

TotalBond VH

REFERRING VET

Dr. Shook

INVOICE

42840

DATE

2/15/23

PRESENTING CLINICAL SIGNS

History: 9 yo MN DLH feline, unknown history prior to September 2021. Chronic low BCS 2-3/9 with good appetite, no vomiting or diarrhea. Patient does not groom himself. GI Panel in August 2022 shows mild increase in Folate (26.4, normal interval 9.7 -21.6), all other WNL. Bloodwork performed today

ULTRASONOGRAPHIC EXAMINATION OF THE ABDOMEN

Urinary System

The **urinary bladder**, trigone, and pelvic urethra presented normal thicknesses and normal tone. The ureters were not visible which is normal. A minor amount of debris was noted. No evidence of inflammatory or neoplastic changes was noted. Ureteral papillae were normal.

The **kidneys** revealed largely normal size and structure, corticomedullary definition and ratio (cortex 1/3 of medulla) were essentially maintained with some age-related loss of curvilinear patterns regarding the capsule and C/M junction. The cortices presented largely uniform texture with some increased echogenicity expected for his age patient. Medullary structure differed distinctly from that of the cortex and no evidence of pelvic dilation was present. The left kidney measured 3.52 cm.

Adrenal Glands

Both **adrenal glands** were visualized and recognized as having normal shape, size, position and echogenicity for this breed. The phrenic vasculature, glandular echogenicity and detail were unremarkable. Capsule, cortex, and medullary definition were normal for this age patient. The left adrenal gland measured 0.9 cm.

Spleen

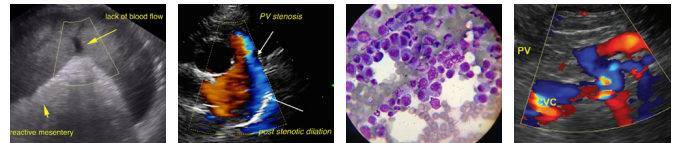
The **spleen** was moderately enlarged in this patient and measured 1.5 cm. The spleen revealed uniform parenchyma.

Liver

The **liver** images submitted revealed subjectively normal liver size, contour, and structure. Parenchymal echogenicity was naturally coarse and hypoechoic to the spleen. Vascular and biliary tracts were of normal volume with no evidence of congestion. The gallbladder presented acceptably thin walls with primarily anechoic content. The cystic and common bile ducts were normal. No pathological hepatic lymphadenopathy was evident. No overt structural evidence of inflammatory, infiltrative or regenerative pathology was evident.

Gastrointestinal

Examination of the **gastrointestinal tract** revealed a stomach and intestine free of stasis, of normal wall thickness, acceptable curvilinear mural detail, and peristaltic activity. Small and large intestine



PATIENT

Harry Shook

demonstrated normal luminal chyme and stool consistency respectively. No obstructive or overt infiltrative disease was noted. No associated abnormal lymphatic activity was noted.

SPECIES

Feline

Pancreas

The base and limbs of the **pancreas** were observed to be largely isoechoic to surrounding omental fat. Pancreatic duct and capsular contour were acceptably normal and parenchyma respected normal curvilinear patterns. No overt evidence of active inflammatory or neoplastic disease was noted.

BREED

Domesetic longhair

ULTRASONOGRAPHIC FINDINGS

SEX

Neutered male

Unremarkable abdomen with splenomegaly.

AGE

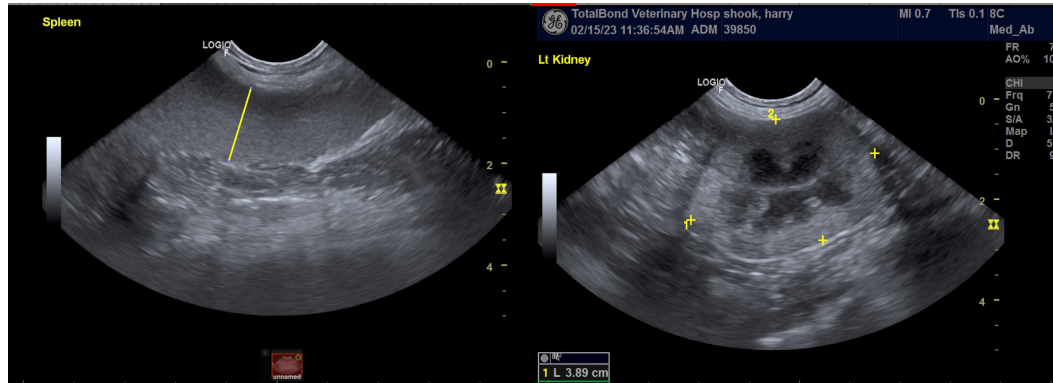
8 years

INTERPRETATION OF THE FINDINGS & FURTHER RECOMMENDATIONS

FNA of the spleen is warranted to assess for reactive spleen versus splenitis or emerging round cell neoplasia.

WEIGHT

9.2 lbs



INTERPRETED BY

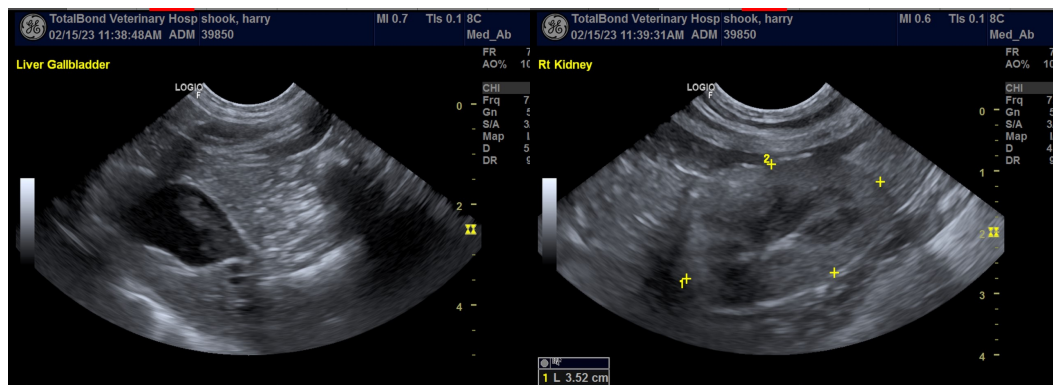
Eric Lindquist, DMV
DABVP, Cert. IVUSS

IMAGING PERFORMED BY

Dr. Harris

HOSPITAL NAME

TotalBond VH



REFERRING VET

Dr. Shook

INVOICE

42840

DATE

2/15/23



PATIENT

Harry Shook

SPECIES

Feline

BREED

Domesetic longhair

SEX

Neutered male

AGE

8 years

WEIGHT

9.2 lbs

INTERPRETED BY

Eric Lindquist, DMV
DABVP, Cert. IVUSS

**IMAGING
PERFORMED BY**

Dr. Harris

HOSPITAL NAME

TotalBond VH

REFERRING VET

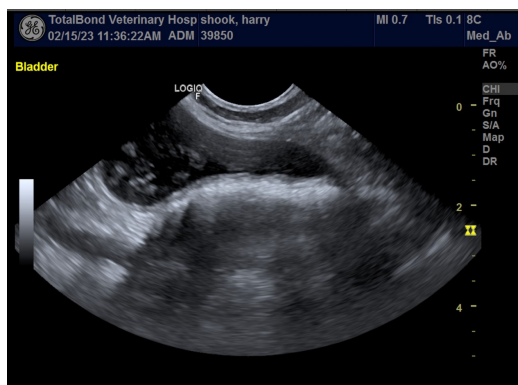Dr. Shook

INVOICE

42840

DATE

2/15/23



The information and recommendations provided are based on the images presented by the referring veterinarian/sonographer. No evaluation can be communicated regarding pathology that was not visible in the image/video clips provided.

Thank you for this referral. If the clinical or image interpretation does not parallel your findings or if I can be of any further assistance please contact me.

Eric Lindquist, DMV, DABVP, Cert. IVUSS, CEO of SonoPath.com
info@SonoPath.com