



## PATIENT

Reyden Brick City Kitty

## SPECIES

Feline

## BREED

DSH

## SEX

Neutered Male

## AGE

7

## WEIGHT

5.8

## INTERPRETED BY

Eric Lindquist, DMV,  
DABVP (CFM), Cert.  
IVUSS

## IMAGING PERFORMED BY

Jenn

## HOSPITAL NAME

Rockaway Animal  
Hospital

## REFERRING VET

Dr. Dubos

## INVOICE

72985

## DATE

2/14/26

## PRESENTING CLINICAL SIGNS

Hypothermic hypoglycemic emaciated dehydrated Current meds IVF dextrose as needed Metro Unasyn Cerenia Pepcid

Abnormal PE/Chem/CBC/UA Results: HCT 20% WBC 45K Neutrophils 34 Bands Lymphocytosis Monocytosis Creat 2.2 BUN 72 Phos 10.9 Glob 5.3 GGT 6 FELV/FIV neg USG 1.018

## ULTRASONOGRAPHIC EXAMINATION OF THE ABDOMEN

### Urinary System

The **urinary bladder**, trigone, and pelvic urethra presented normal thicknesses and normal tone. The ureters were not visible which is normal. No uroliths or sediment were visualized and anechoic urine was present. No evidence of inflammatory or neoplastic changes were noted. Ureteral papillae were normal.

The **kidneys** presented a moderate amount of echogenic remodeling and corticomedullary mineralization, non-obstructive. The right kidney measured 3.45 cm. The left kidney measured 3.55 cm.

### Adrenal Glands

The regions of the **adrenal glands** were unremarkable.

### Spleen

The **spleen** presented a smooth homogeneous parenchyma hyperechoic to liver and renal cortical parenchyma. The capsule was smooth without noticeable expansion or deviation from within the spleen or adjacent pathology. The splenic vasculature demonstrated normal volume without signs of congestion or thrombosis. No sonographic evidence of acute or chronic inflammatory, neoplastic, or infarctual changes were noted.

### Liver

The **liver** revealed slight increased portal markings. The gallbladder and common bile duct were unremarkable.

### Gastrointestinal

The **stomach** was unremarkable. Variable small intestinal thickening noted with muscularis hypertrophy, and mesenteric lymph node enlargement. The lymph nodes were enlarged and rounded, an example measured up to 2.1 cm x 1.3 cm. The colon was empty.

### Pancreas

The **pancreas** was hypoechoic and irregular with undulating contour.

### Free Abdomen

Minimal amount of abdominal fat noted in this patient.

Slight free fluid noted.



## PATIENT

Reyden Brick City Kitty

## SPECIES

Feline

## BREED

DSH

## SEX

Neutered Male

## AGE

7

## WEIGHT

5.8

## INTERPRETED BY

Eric Lindquist, DMV,  
DABVP (CFM), Cert.  
IVUSS

## IMAGING PERFORMED BY

Jenn

## HOSPITAL NAME

Rockaway Animal  
Hospital

## REFERRING VET

Dr. Dubos

## INVOICE

72985

## DATE

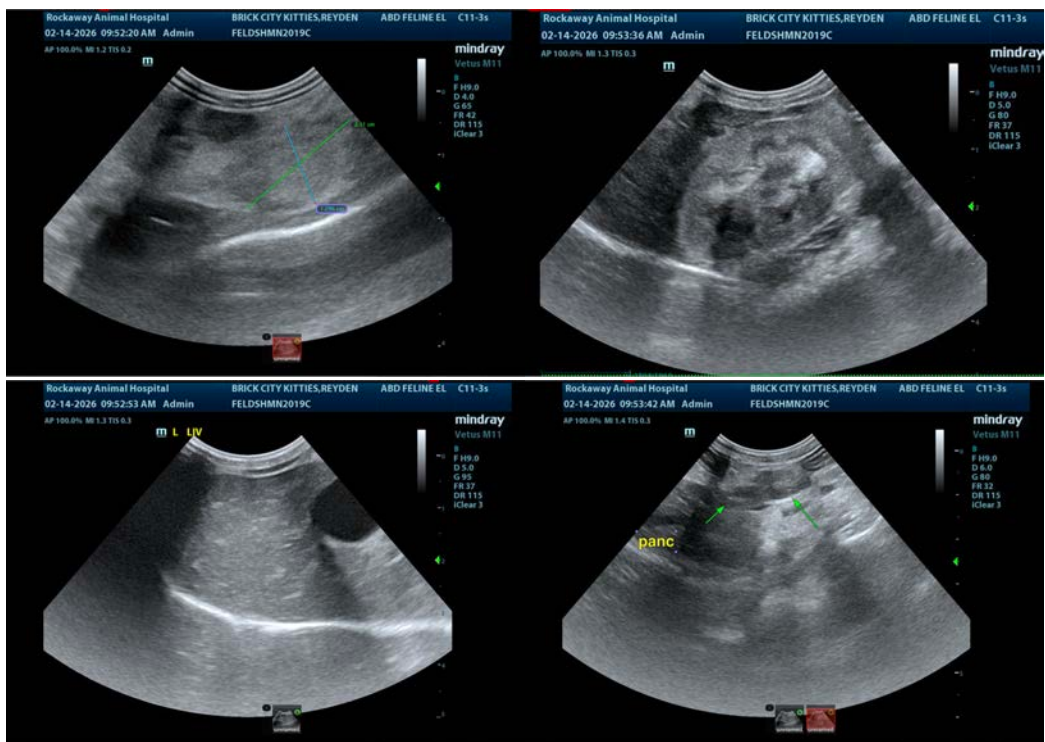
2/14/26

## ULTRASONOGRAPHIC FINDINGS

- Diffuse intestinal thickening with mesenteric lymphadenopathy and slight free fluid.
- Moderate chronic degenerative renal changes with mineralization.
- Hepatic and pancreatic remodeling.

## INTERPRETATION OF THE FINDINGS & FURTHER RECOMMENDATIONS

Chronic triad disease with maldigestion or round cell neoplasia. The kidneys do appear near end stage. FNA of the mesenteric lymph nodes, CBC path review, bone marrow aspirates all indicated. Prognosis is guarded.



The information and recommendations provided are based on the images presented by the referring veterinarian/sonographer. No evaluation can be communicated regarding pathology that was not visible in the image/video clips provided.

Thank you for this referral. If the clinical or image interpretation does not parallel your findings or if I can be of any further assistance please contact me.

**Eric Lindquist, DMV, DABVP(CFM), Cert. IVUSS,**  
CEO, Owner, Founder -- SonoPath.com  
[info@SonoPath.com](mailto:info@SonoPath.com)