



PATIENT

Oscar Hobbs

SPECIES

Canine

BREED

Shih Tzu X

SEX

Intact Male

AGE

11 Years

WEIGHT

6.5

INTERPRETED BY

Eric Lindquist, DMV

DABVP, Cert. IVUSS

IMAGING PERFORMED BY

Dr. Valentina Fresta

HOSPITAL NAME

The Veterinary Surgery

REFERRING VET

Dr. Valentina Fresta

INVOICE

45140

DATE

2/14/23

PRESENTING CLINICAL SIGNS

Presented for Cardiac Ultrasound. The dog has been diagnosed by another colleague with MVD and therefore being on treatment with; Fortekor 2.5 mg 1 tab once a day. Pimobendan 1.25 half tablet BID. No cough or intolerance to the exercise has been noticed since the treatment. The dog is very happy in himself. At the clinical presentation BAR. mmc are pink .HR 140 and RR 32. Heart murmur audible on the left side of the thorax first graded. Prostate slightly enlarged at the rectal examination. The rest of the examination is unremarkable.

Abnormal PE/Chem/CBC/UA Results: The CBC reveals thrombocytosis, the comprehensive ALP are increased

ULTRASONOGRAPHIC EXAMINATION OF THE HEART

CANINE CARDIAC PARAMETERS	MR VMAX (m/s)	TR VMAX (m/s)	LA/AO (Boon method)	LA/AO (Heart Base; Swe)	FS (%)	EF (%)	EPSS (cm)
NORMAL PARAMETER	4.5-5.5	<2.7	1.3	<1.6	28-40	40-100	<0.6
PATIENT			1.15	--	45	--	NM
CANINE CARDIAC PARAMETERS	HR (BPM)	AV VMAX (m/s)	PV MAX (m/s)	BODY WEIGHT (kg)	LA 2D short axis Base view (cm)	LVIDd Avg; 2D and m-mode short axis (cm)	LVIDs Avg; 2D and m-mode short axis (cm)
NORMAL PARAMETER	50-100	0.7-1.7	0.7-1.6	BELOW	BELOW	BELOW	BELOW
PATIENT	--	--	--		2.8	2.3	

Cardiac Presentation

Views submitted of the heart revealed normal volumes and contractility in all four chambers. The mitral valve was mildly thickened, presumed to be source of the murmur. No pericardial or pleural effusion noted. No evidence of volume overload. Hepatic veins were not dilated.

ULTRASONOGRAPHIC FINDINGS

- Stage B1 valvular disease, compensated at this time

INTERPRETATION OF THE FINDINGS & FURTHER RECOMMENDATIONS

It is debatable on whether the cardiac medications are necessary at this time, depending on how the case presentation as prior to initiating medications, as at this time there is normal volume and contractility and appears stable.



PATIENT

Oscar Hobbs

SPECIES

Canine

BREED

Shih Tzu X

SEX

Intact Male

AGE

11 Years

WEIGHT

6.5

INTERPRETED BY

Eric Lindquist, DMV
DABVP, Cert. IVUSS

IMAGING PERFORMED BY

Dr. Valentina Fresta

HOSPITAL NAME

The Veterinary Surgery

REFERRING VET

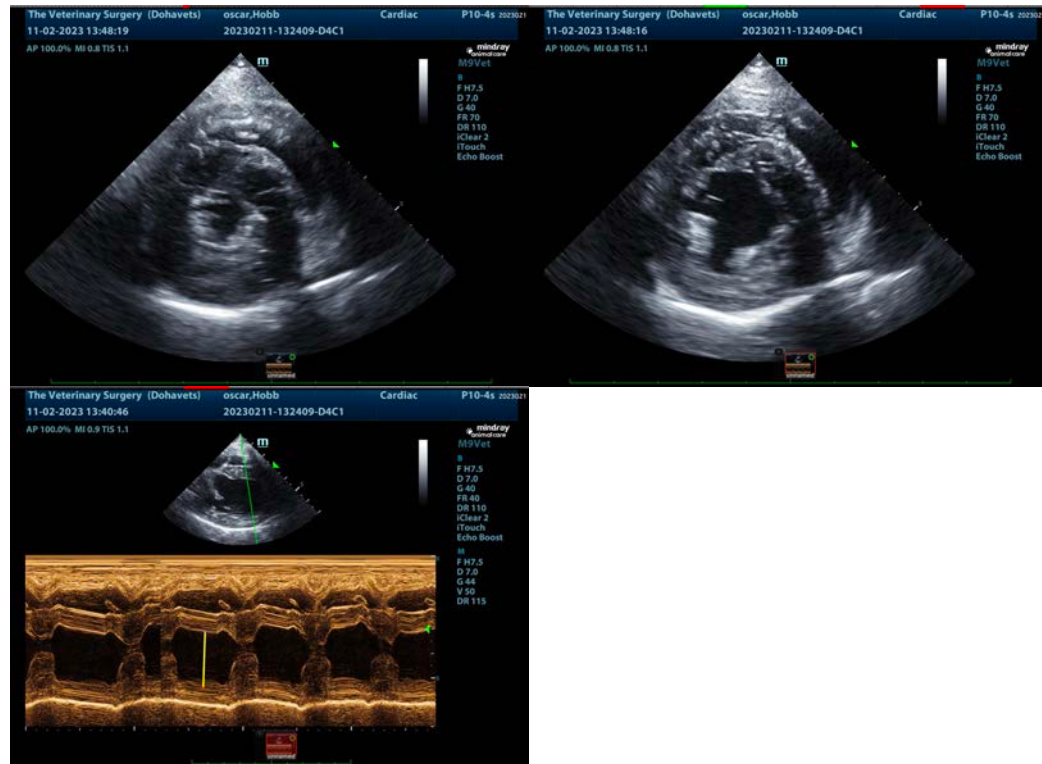
Dr. Valentina Fresta

INVOICE

45140

DATE

2/14/23



The information and recommendations provided are based on the images presented by the referring veterinarian/sonographer. No evaluation can be communicated regarding pathology that was not visible in the image/video clips provided.

Thank you for this referral. If the clinical or image interpretation does not parallel your findings or if I can be of any further assistance please contact me.

Eric Lindquist, DMV, DABVP, Cert. IVUSS, CEO of SonoPath.com

info@SonoPath.com