



PATIENT

Oliver Flasher

SPECIES

Canine

BREED

Boston Terrier

SEX

Neutered Male

AGE

10 Years

WEIGHT

24.3 pounds

INTERPRETED BY

Eric Lindquist, DMV,
DABVP(CFM), Cert.
IVUSS

IMAGING PERFORMED BY

Brandon

HOSPITAL NAME

Dillsburg Veterinary
Center

REFERRING VET

Dr. Pryor

INVOICE

13757

DATE

02/13/26

PRESENTING CLINICAL SIGNS

- hx of heart murmur (prev grade III/VI). previous echo showed mild mitral and mild tricuspid valvular endocardiosis. Oliver was seen on 1/28 due to episodes of hyporexia. Heart murmur auscultated at grade IV-V/VI. only current medication is Theophylline 50mg every 24 hours. Was previously on Lasix and Pimobendan from another vet but was discontinued 6/2025. hx of chronic hematuria (benign essential hematuria vs patent ductus urachus). p having possible seizure/syncopal episodes. systolic BP 138, 130, 128, 122.

Abnormal PE/Chem/CBC/UA Results: UA WBC 0-3/hpf, RBC 10-20/hpf, Epithelial cells 0-2/hpf, crystals 0/hpf. ALKP 338, PHOS 2.2, CPK 48, rest WNL. CBC PLT 437, rest WNL.

ULTRASONOGRAPHIC EXAMINATION OF THE HEART

CANINE CARDIAC PARAMETERS	MR VMAX (m/s)	TR VMAX (m/s)	LA/AO (M-Mode)	LA/AO (Heart Base; Swe)	FS (%)	EF (%)	EPSS (cm)
NORMAL PARAMETER	4.5-5.5	<2.7	1.3	Up to 1.6	28-40	40-100	<0.6
PATIENT	<5.0	--	1.1	1.3	50	--	0.1
CANINE CARDIAC PARAMETERS	HR (BPM)	AV VMAX (m/s)	PV MAX (m/s)	BODY WEIGHT (lbs)	LAD LA MAX 4 Chamber	LVIDd Avg; 2D and m-mode short axis (cm)	LVIDs Avg; 2D and m-mode short axis (cm)
NORMAL PARAMETER	50-100	0.7-1.7	0.7-1.6				
PATIENT	90	--	0.5	24.3	3.1	3.0	--

Cardiac Presentation

The echocardiogram in this patient demonstrated normal **left atrial** size based on 3 different LA measurement methods. Chamber volumes and echogenicity were normal. The cranial and caudal **mitral** valve leaflets presented vegetative thickening consistent with endocardiosis. Doppler indicated measurable insufficiency. The **left ventricle** presented normal thicknesses with linear contour and was not dilated nor restricted. The **myocardium** presented normal echogenicity without subjective evidence of significant fibrotic or ischemic disease. **Contractility** of the ventricular walls was adequate and in normal range for this patient evidenced by the fractional shortening measurement and subjective evaluation of the different regions of the myocardium. The **left ventricular outflow** tract demonstrated normal laminar flow and subjective structural integrity. The **right atrium** and auricle revealed normal size, structure and content. No evidence of masses was noted or chamber overload. **Tricuspid** valvular assessment demonstrated adequate linear morphology. The **right ventricle** was of normal size (1/3 diameter of LV), chordae structure, myocardial echogenicity and thickness. **Pulmonic** tract assessment revealed normal valve structure, laminar flow, and diameter (approx.1:1 pa/ao ratio). No visible **pericardial** or free pleura fluid was noted. No echographically detectable evidence of



PATIENT

Oliver Flasher

SPECIES

Canine

BREED

Boston Terrier

SEX

Neutered Male

AGE

10 Years

WEIGHT

24.3 pounds

INTERPRETED BY

Eric Lindquist, DMV,
DABVP(CFM), Cert.
IVUSS

IMAGING PERFORMED BY

Brandon

HOSPITAL NAME

Dillsburg Veterinary
Center

REFERRING VET

Dr. Pryor

INVOICE

13757

DATE

02/13/26

infiltrative disease was visible. The cranial mediastinum and pericardial regions were free of masses in the visible window.

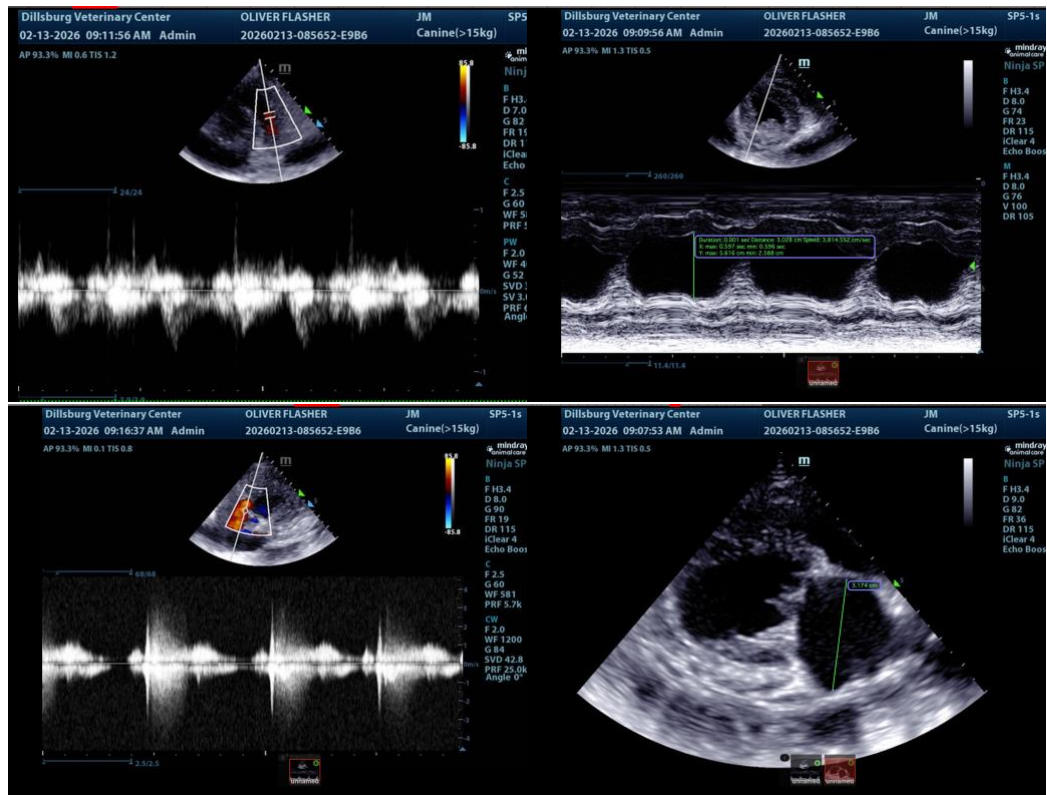
ULTRASONOGRAPHIC FINDINGS

- Stage B1 valvular disease.

INTERPRETATION OF THE FINDINGS & FURTHER RECOMMENDATIONS

The heart is stable without clinical disease. No overt contraindication for anesthesia of brief to moderate duration. I suggest Torbutrol premed, Propofol induction, Isoflo maintenance or similar protocol if anesthesia is desired. Blood pressure, EKG and chest radiographs are recommended if not already performed. Target white coat negative systolic pressure of < 160 mmHg. If higher than this ACE-inhibitor is suggested to reach this level. Recheck echocardiogram is recommended in 6-12 months, earlier if murmur grade increases or clinical signs initiate.

The hyporexia does not appear to be cardiac in origin. AN abdominal sonogram is recommended. I do not feel there is any necessity for cardiac medications at this time based on the echocardiogram provided.



The information and recommendations provided are based on the images presented by the referring veterinarian/sonographer. No evaluation can be communicated regarding pathology that was not visible in the image/video clips provided.

Thank you for this referral. If the clinical or image interpretation does not parallel your findings or if I



PATIENT

Oliver Flasher

SPECIES

Canine

BREED

Boston Terrier

SEX

Neutered Male

AGE

10 Years

WEIGHT

24.3 pounds

INTERPRETED BY

Eric Lindquist, DMV,
DABVP(CFM), Cert.
IVUSS

IMAGING PERFORMED BY

Brandon

HOSPITAL NAME

Dillsburg Veterinary
Center

REFERRING VET

Dr. Pryor

INVOICE

13757

DATE

02/13/26

can be of any further assistance, please contact me.

Eric Lindquist, DMV, DABVP(CFM), Cert. IVUSS,

CEO, Owner, Founder -- SonoPath.com

info@SonoPath.com