



PATIENT

Lulu Shermister

SPECIES

Canine

BREED

Chihuahua/Pomeranian
Mix

SEX

Spayed Female

AGE

10 Years 9 Months

WEIGHT

13.6 pounds

INTERPRETED BY

Eric Lindquist, DMV,
DABVP(CFM), Cert.
IVUSS

IMAGING PERFORMED BY

Carla

HOSPITAL NAME

Animal Care Clinic of
Flanders

REFERRING VET

Dr. Hallihan

INVOICE

13765

DATE

02/13/26

PRESENTING CLINICAL SIGNS

- Grade 3/6 systolic murmur
- Pre-Dental work up
- Last echocardiogram done 1/2024 - Stage B1 valvular disease
- Heart murmur has increased from 2/6 from last year
- Medications: Trazodone 50mg - 1-tab po 2 hours prior to drop off

Abnormal PE/Chem/CBC/UA Results: Fecal = Positive for Hookworms - Panacur treatment for 3 days given at 2/2/26 annual visit. BP = AVG 111 systolic

ULTRASONOGRAPHIC EXAMINATION OF THE HEART

CANINE CARDIAC PARAMETERS	MR VMAX (m/s)	TR VMAX (m/s)	LA/AO (M-Mode)	LA/AO (Heart Base; Swe)	FS (%)	EF (%)	EPSS (cm)
NORMAL PARAMETER	4.5-5.5	<2.7	1.3	Up to 1.6	28-40	40-100	<0.6
PATIENT	--	2.0	1.3	1.4	50	90	0.2
CANINE CARDIAC PARAMETERS	HR (BPM)	AV VMAX (m/s)	PV MAX (m/s)	BODY WEIGHT (lbs)	LAD LA MAX 4 Chamber	LVIDd Avg; 2D and m-mode short axis (cm)	LVIDs Avg; 2D and m-mode short axis (cm)
NORMAL PARAMETER	50-100	0.7-1.7	0.7-1.6				
PATIENT	NM	NM	1.30	13.6	2.2	2.4	--

Cardiac Presentation

The echocardiogram in this patient demonstrated normal **left atrial** size based on 3 different LA measurement methods. Chamber volumes and echogenicity were normal. The cranial and caudal **mitral** valve leaflets presented vegetative thickening consistent with endocardiosis. Doppler indicated moderate eccentric insufficiency. The **left ventricle** presented normal thicknesses with linear contour and was not dilated nor restricted. The **myocardium** presented normal echogenicity without subjective evidence of significant fibrotic or ischemic disease. **Contractility** of the ventricular walls was adequate and in normal range for this patient evidenced by the fractional shortening measurement and subjective evaluation of the different regions of the myocardium. The **left ventricular outflow** tract demonstrated normal laminar flow and subjective structural integrity. The **right atrium** and auricle revealed normal size, structure and content. No evidence of masses was noted or chamber overload. **Tricuspid** insufficiency was present. The **right ventricle** was of normal size (1/3 diameter of LV), chordae structure, myocardial echogenicity and thickness. **Pulmonic** tract assessment revealed normal valve structure, laminar flow, and diameter (approx.1:1 pa/ao ratio). No visible **pericardial** or free pleura fluid was noted. No echographically detectable evidence of infiltrative disease was visible. The cranial **mediastinum and pericardial regions** were free of masses in the visible window.



PATIENT

Lulu Shermister

SPECIES

Canine

BREED

Chihuahua/Pomeranian
Mix

SEX

Spayed Female

AGE

10 Years 9 Months

WEIGHT

13.6 pounds

INTERPRETED BY

Eric Lindquist, DMV,
DABVP(CFM), Cert.
IVUSS

IMAGING PERFORMED BY

Carla

HOSPITAL NAME

Animal Care Clinic of
Flanders

REFERRING VET

Dr. Hallihan

INVOICE

13765

DATE

02/13/26

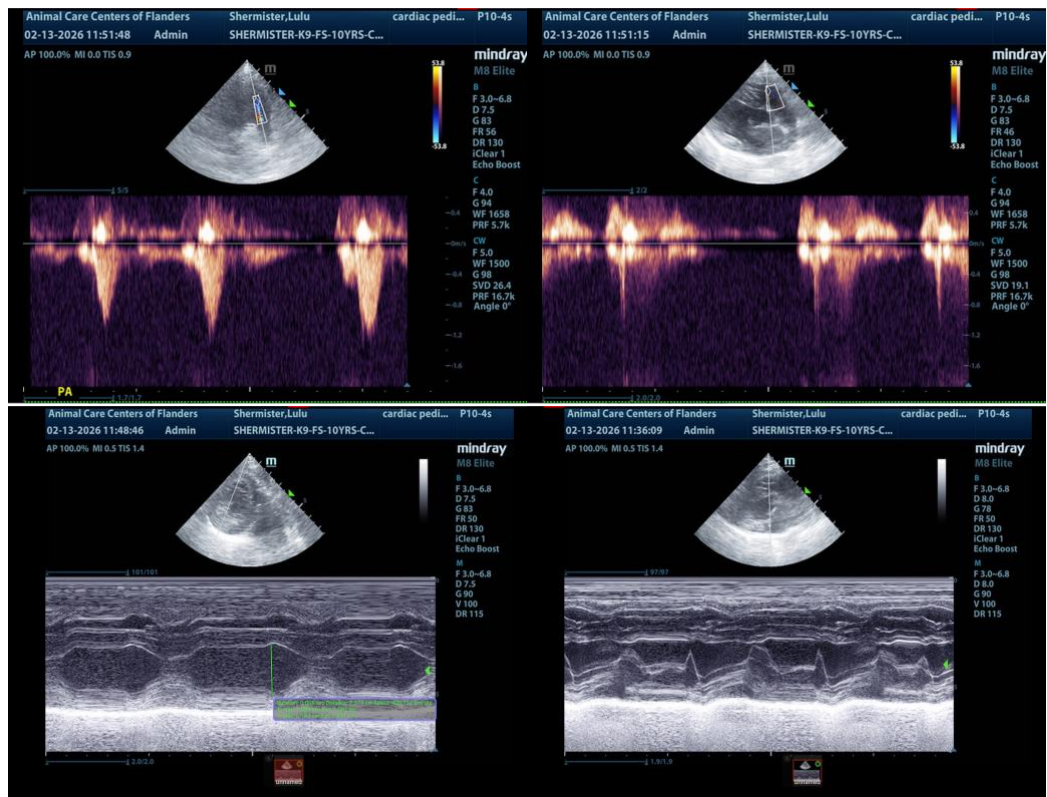
ULTRASONOGRAPHIC FINDINGS

- Compensated stage B1 valvular disease

INTERPRETATION OF THE FINDINGS & FURTHER RECOMMENDATIONS

The heart is stable without clinical disease. No overt contraindication for anesthesia of brief to moderate duration. I suggest Torbutrol premed, Propofol induction, Isoflor maintenance or similar protocol if anesthesia is desired. Blood pressure, EKG and chest radiographs are recommended if not already performed. Target white coat negative systolic pressure of < 160 mmHg. If higher than this ACE-inhibitor is suggested to reach this level. Recheck echocardiogram is recommended in 6-12 months, earlier if murmur grade increases or clinical signs initiate.

No medications are recommended.





PATIENT

Lulu Shermister

SPECIES

Canine

BREED

Chihuahua/Pomeranian
Mix

SEX

Spayed Female

AGE

10 Years 9 Months

WEIGHT

13.6 pounds

INTERPRETED BY

Eric Lindquist, DMV,
DABVP(CFM), Cert.
IVUSS

IMAGING PERFORMED BY

Carla

HOSPITAL NAME

Animal Care Clinic of
Flanders

REFERRING VET

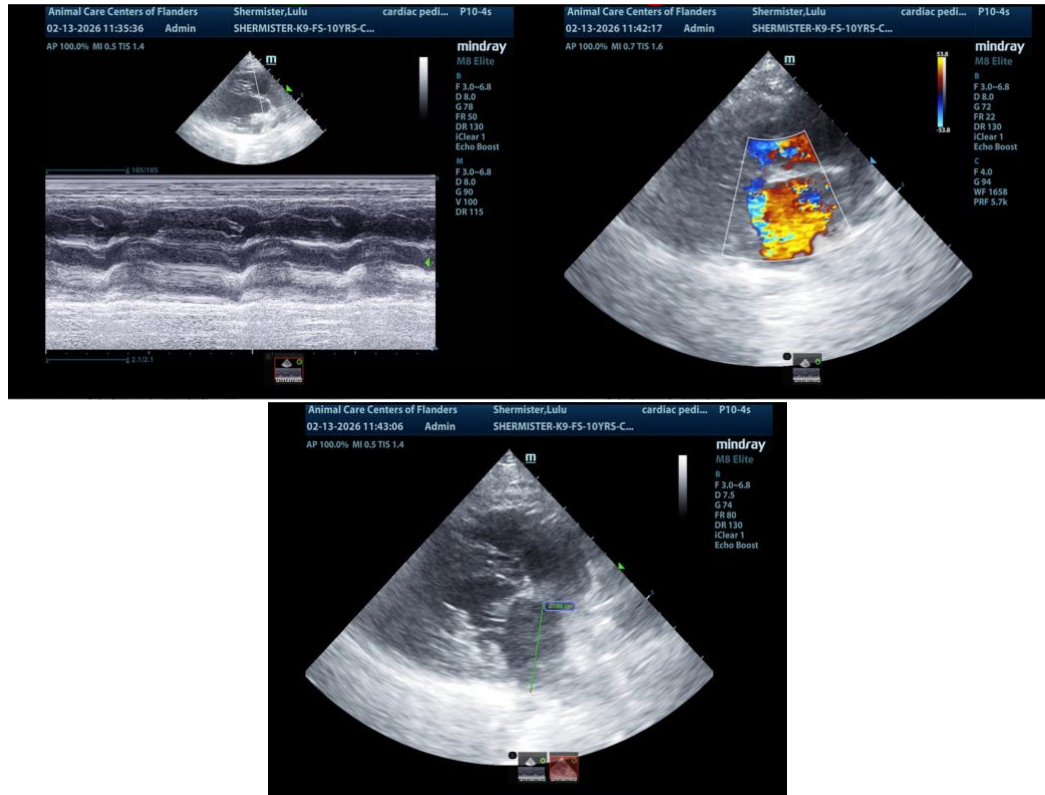
Dr. Hallihan

INVOICE

13765

DATE

02/13/26



The information and recommendations provided are based on the images presented by the referring veterinarian/sonographer. No evaluation can be communicated regarding pathology that was not visible in the image/video clips provided.

Thank you for this referral. If the clinical or image interpretation does not parallel your findings or if I can be of any further assistance, please contact me.

Eric Lindquist, DMV, DABVP(CFM), Cert. IVUSS,

CEO, Owner, Founder -- SonoPath.com

info@SonoPath.com