



PATIENT

Ginger Searles

SPECIES

Canine

BREED

Cavalier King Charles
 Spaniel

SEX

Spayed Female

AGE

8 Years

WEIGHT

Not Provided

INTERPRETED BY

Eric Lindquist, DMV,
 DABVP(CFM), Cert.
 IVUSS

IMAGING PERFORMED BY

Shari Reffi CVT

HOSPITAL NAME

Animal Hospital of
 Sussex County

REFERRING VET

Dr. Catania

INVOICE

13761

DATE

02/13/26

PRESENTING CLINICAL SIGNS

- grade V/VI heart murmur, hx prev. Dx cardiac dz.
- no clinical signs at home per owner
- current meds: Pimobendan 2.5 mg po bid; Spironolactone 12.5mg po Sid (both meds not given religiously)

ULTRASONOGRAPHIC EXAMINATION OF THE HEART

CANINE CARDIAC PARAMETERS	MR VMAX (m/s)	TR VMAX (m/s)	LA/AO (M-Mode)	LA/AO (Heart Base; Swe)	FS (%)	EF (%)	EPSS (cm)
NORMAL PARAMETER	4.5-5.5	<2.7	1.3	Up to 1.6	28-40	40-100	<0.6
PATIENT	5.72	2.53	NM	--	32	61	NM
CANINE CARDIAC PARAMETERS	HR (BPM)	AV VMAX (m/s)	PV MAX (m/s)	BODY WEIGHT (kg)	LAD LA MAX 4 Chamber	LVIDd Avg; 2D and m-mode short axis (cm)	LVIDs Avg; 2D and m-mode short axis (cm)
NORMAL PARAMETER	50-100	0.7-1.7	0.7-1.6				
PATIENT	151	1.44	0.67	NP	4.37	4.26	--

E-Wave Velocity: 1.2

Cardiac Presentation

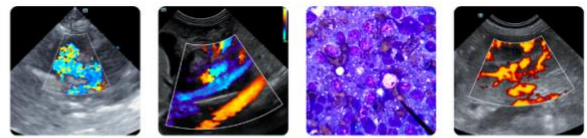
Pulmonic insufficiency was present measuring 1.43. This patient presented with mild volume overload of the left atrium and left ventricle with moderate to severe mitral valve insufficiency. Minor tricuspid valve insufficiency. No evidence of pericardial or pleural effusion. Right sided volumes were unremarkable. The hepatic veins were not dilated.

ULTRASONOGRAPHIC FINDINGS

- Partially compensated stage B2 valvular disease.

INTERPRETATION OF THE FINDINGS & FURTHER RECOMMENDATIONS

Recommend ensuring that Pimobendan and Spironolactone are given regularly and adding an ACE-inhibitor 0.5 mg/kg SID progressively BID. Recheck echo is suggested in 6 months if the patient is stable, earlier if any clinical signs arise.



PATIENT
 Ginger Searles

SPECIES
 Canine

BREED
 Cavalier King Charles
 Spaniel

SEX
 Spayed Female

AGE
 8 Years

WEIGHT
 Not Provided

INTERPRETED BY
 Eric Lindquist, DMV,
 DABVP(CFM), Cert.
 IVUSS

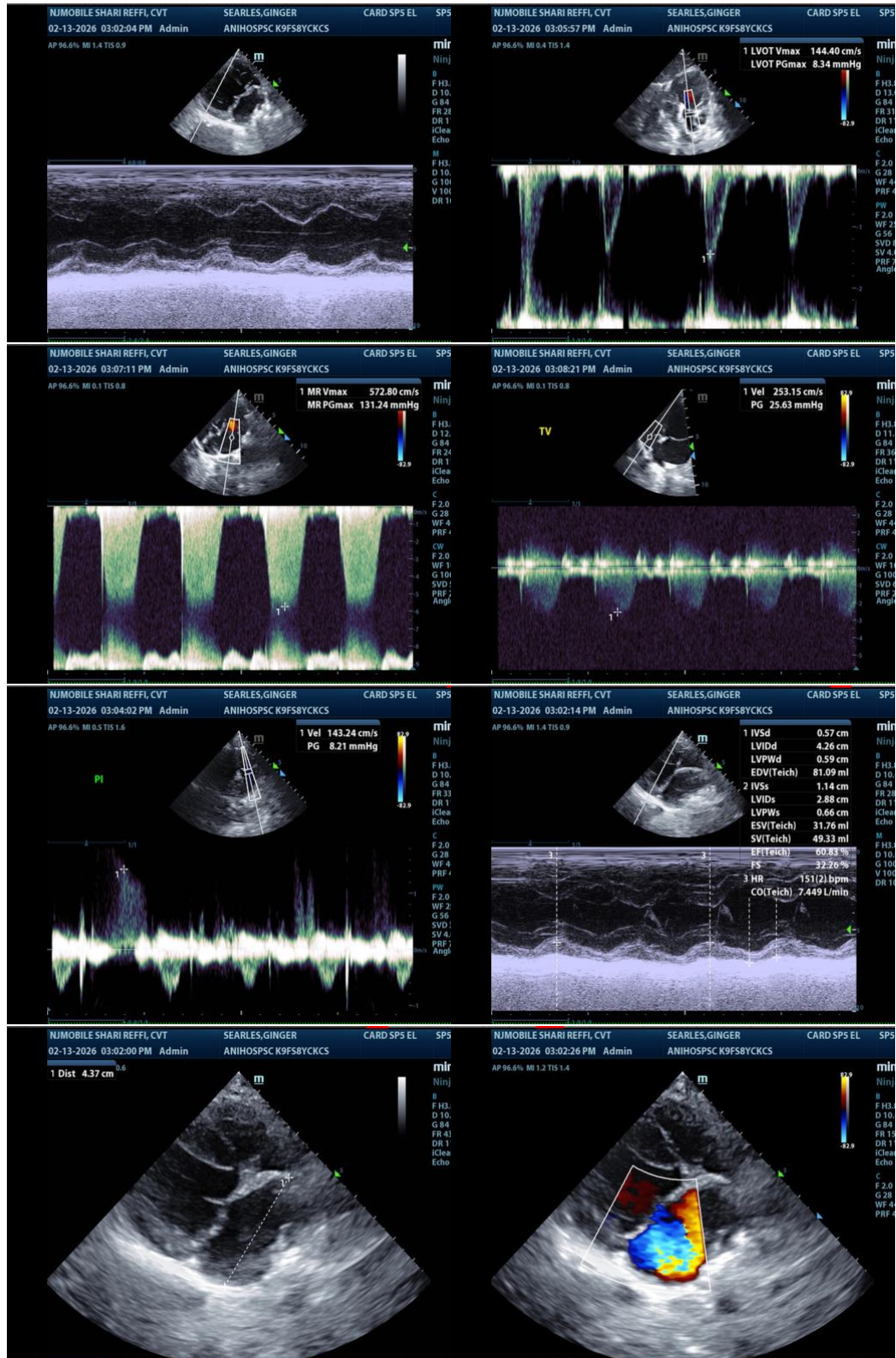
IMAGING PERFORMED BY
 Shari Reffi CVT

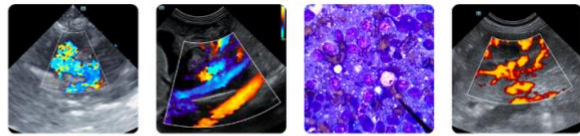
HOSPITAL NAME
 Animal Hospital of
 Sussex County

REFERRING VET
 Dr. Catania

INVOICE
 13761

DATE
 02/13/26





PATIENT

Ginger Searles

SPECIES

Canine

BREED

Cavalier King Charles
Spaniel

SEX

Spayed Female

AGE

8 Years

WEIGHT

Not Provided

INTERPRETED BY

Eric Lindquist, DMV,
DABVP(CFM), Cert.
IVUSS

**IMAGING
PERFORMED BY**

Shari Reffi CVT

HOSPITAL NAME

Animal Hospital of
Sussex County

REFERRING VET

Dr. Catania

INVOICE

13761

DATE

02/13/26

The information and recommendations provided are based on the images presented by the referring veterinarian/sonographer. No evaluation can be communicated regarding pathology that was not visible in the image/video clips provided.

Thank you for this referral. If the clinical or image interpretation does not parallel your findings or if I can be of any further assistance, please contact me.

Eric Lindquist, DMV, DABVP(CFM), Cert. IVUSS,

CEO, Owner, Founder -- SonoPath.com

info@SonoPath.com