



PATIENT

Bogie Henry

SPECIES

Canine

BREED

Spaniel x

SEX

Neutered Male

AGE

9 Years 10 Months

WEIGHT

38 lbs

INTERPRETED BY

Eric Lindquist, DMV,
DABVP (CFM), Cert.
IVUSS

IMAGING PERFORMED BY

Shari Reffi, CVT

HOSPITAL NAME

Sova Animal Hospital

REFERRING VET

Dr. Ammeraal

INVOICE

72977

DATE

2/13/26

PRESENTING CLINICAL SIGNS

Hyperthyroidism. Bladder stones. Parathyroid Tumor.

Abnormal PE/Chem/CBC/UA Results: ALT 333 Alkp 285 Ca 13.2 I ca 1.59 mil/L

ULTRASONOGRAPHIC EXAMINATION OF THE THYROID

The right thyroid lobe measured 0.40 cm in width. Normal parathyroids visible up to 2.0 mm. The esophagus, trachea, regional tissues, and salivary glands are all normal.

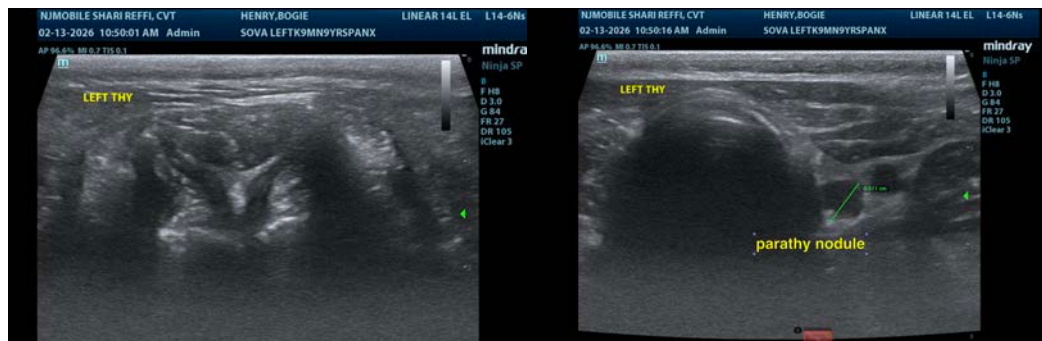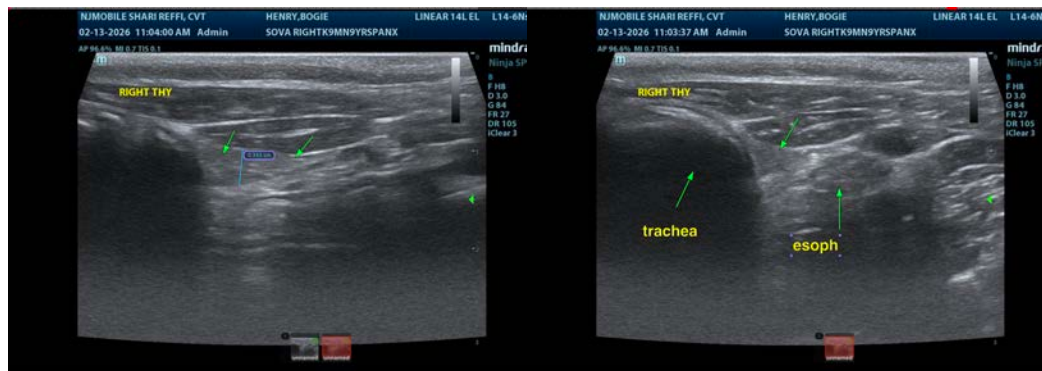
The left thyroid lobe revealed a hypoechoic parathyroid nodule measuring 0.51 cm. The parathyroid adenoma appears encapsulated and resectable. It occupies the mid body of the thyroid gland.

ULTRASONOGRAPHIC FINDINGS

- Left mid parathyroid adenoma.

INTERPRETATION OF THE FINDINGS & FURTHER RECOMMENDATIONS

Appears resectable. Surgical intervention recommended.





PATIENT

Bogie Henry

SPECIES

Canine

BREED

Spaniel x

SEX

Neutered Male

AGE

9 Years 10 Months

WEIGHT

38 lbs

INTERPRETED BY

Eric Lindquist, DMV,
DABVP (CFM), Cert.
IVUSS

IMAGING PERFORMED BY

Shari Reffi, CVT

HOSPITAL NAME

Sova Animal Hospital

REFERRING VET

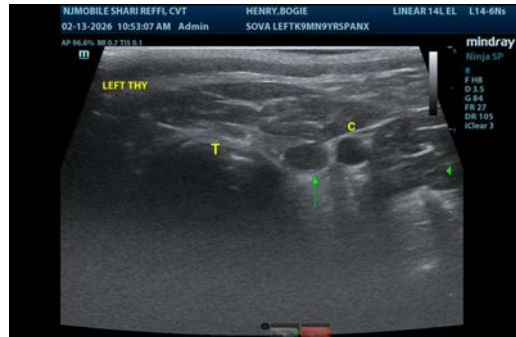
Dr. Ammeraal

INVOICE

72977

DATE

2/13/26



The information and recommendations provided are based on the images presented by the referring veterinarian/sonographer. No evaluation can be communicated regarding pathology that was not visible in the image/video clips provided.

Thank you for this referral. If the clinical or image interpretation does not parallel your findings or if I can be of any further assistance please contact me.

Eric Lindquist, DMV, DABVP(CFM), Cert. IVUSS,
CEO, Owner, Founder -- SonoPath.com
info@SonoPath.com