



**PATIENT**

Vince Hovey

**PRESENTING CLINICAL SIGNS**

not eating vomiting, liver failure, elevated WBC's

**SPECIES**

Canine

**ULTRASONOGRAPHIC EXAMINATION OF THE ABDOMEN**

**Urinary System**

The urinary bladder, trigone, and pelvic urethra presented normal thicknesses and normal tone to a depth of 2.0 cm. The ureters were not visible which is normal. No uroliths or sediment were visualized, and anechoic urine was present. No evidence of inflammatory or neoplastic changes were noted. Ureteral papillae were normal.

**BREED**

Lab Mix

**SEX**

MN

The kidneys revealed normal size and structure, corticomedullary definition and ratio for this age. The cortices presented largely uniform texture with normal echogenic relationship to liver and spleen. Medullary structure differed distinctly from the cortex and no evidence of pelvic dilation was present. The capsules were acceptably uniform without significant irregularities. The left kidney measured 6.24 cm in length. The right kidney measured 6.33 cm in length.

**AGE**

13

**Adrenal Glands**

The regional on the bilateral adrenal glands was free of pathology.

**WEIGHT**

68

**Spleen**

The spleen presented with mild enlargement and subtle micronodular parenchymal changes. An ultrasound guided splenic FNA strongly encouraged.

**INTERPRETED BY**

Eric Lindquist, DMV  
DABVP, Cert. IVUSS

**Liver**

The liver images submitted revealed mild enlargement with swollen contour and minor heterogenous parenchymal changes. Mildly increased portal markings were noted. The gallbladder was overdistended with debris consistent with immature mucocele. The gallbladder measured ~ 7.0 cm x 5.0 cm.

**IMAGING PERFORMED BY**

Jenn

**Gastrointestinal**

Examination of the gastrointestinal tract revealed a stomach and intestine free of stasis, of normal wall thickness, acceptable curvilinear mural detail, and peristaltic activity. Small and large intestine demonstrated normal luminal chyme and stool consistency respectively. No obstructive or overt infiltrative disease was noted. No associated abnormal lymphatic activity was noted.

**HOSPITAL NAME**

Rockaway Animal  
Hospital

**Pancreas**

The base and limbs of the pancreas were observed to be largely isoechoic to surrounding omental fat. Pancreatic duct and capsular contour were acceptably normal, and parenchyma respected normal curvilinear patterns. No overt evidence of active inflammatory or neoplastic disease was noted.

**REFERRING VET**

Dr. Maniar

**ULTRASONOGRAPHIC FINDINGS**

**INVOICE**

12943ag

- Micronodular spleen, possible emerging round cell neoplasia
- Immature gallbladder mucocele
- Minor hepatomegaly with heterogenous parenchymal changes

**DATE**

02/13/2023



**PATIENT**

Vince Hovey

**SPECIES**

Canine

**BREED**

Lab Mix

**SEX**

MN

**AGE**

13

**WEIGHT**

68

**INTERPRETED BY**

Eric Lindquist, DMV  
DABVP, Cert. IVUSS

**IMAGING PERFORMED BY**

Jenn

**HOSPITAL NAME**

Rockaway Animal  
Hospital

**REFERRING VET**

Dr. Maniar

**INVOICE**

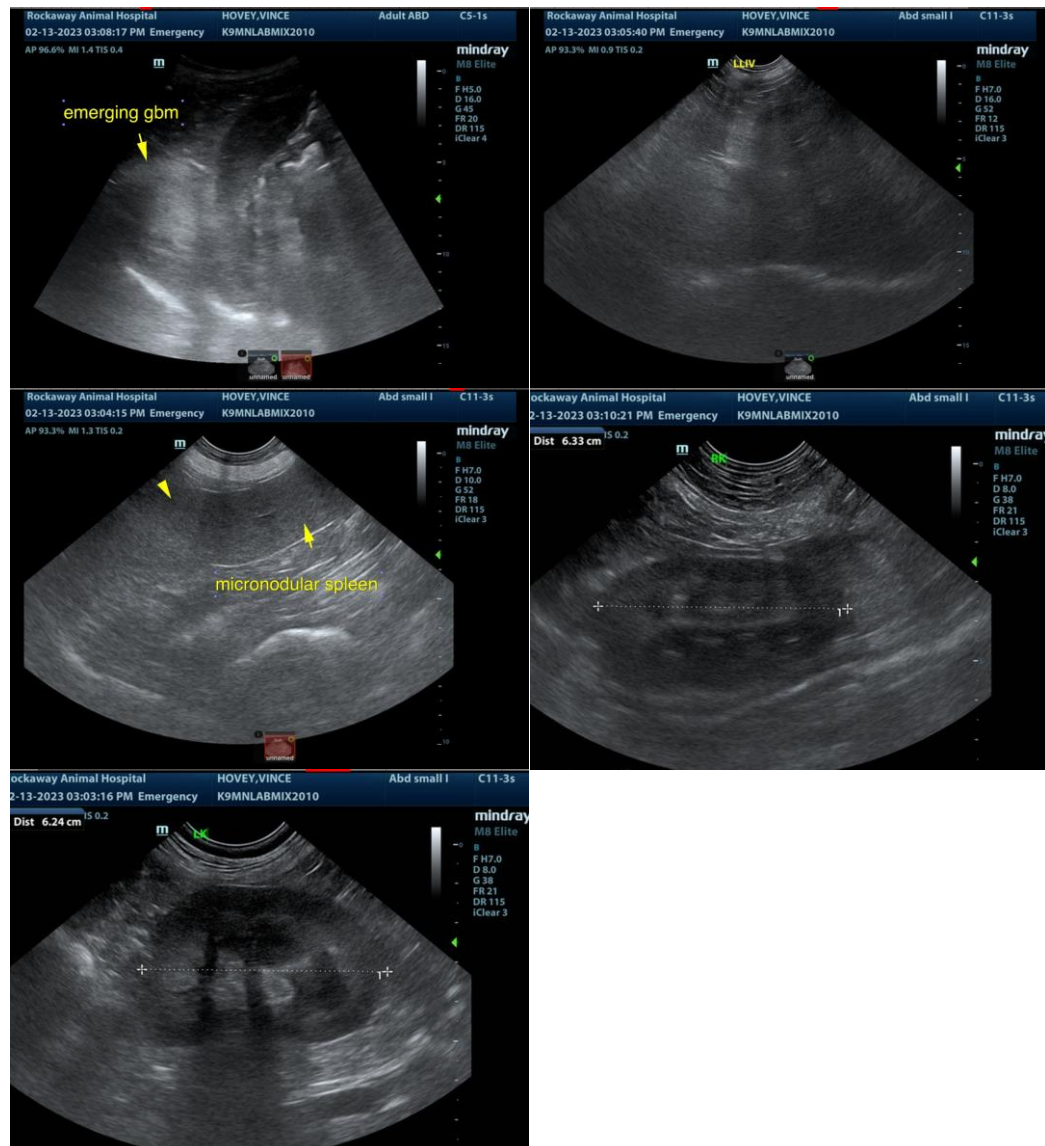
12943ag

**DATE**

02/13/2023

**INTERPRETATION OF THE FINDINGS & FURTHER RECOMMENDATIONS**

The splenic presentation differentials include round cell neoplasia, splenitis or reactive spleen. Assuming normal clotting status and using a 25g needle, a splenic FNA for screening cytology is warranted for further assessment. Ursodiol therapy is warranted for the next 6-8 weeks followed by a recheck sonogram to reassess the gallbladder. Supportive care is warranted otherwise.



The information and recommendations provided are based on the images presented by the referring veterinarian. No evaluation can be communicated regarding pathology that was not visible in the image/video clips provided.

Thank you for this referral. If the clinical or image interpretation does not parallel your findings or if I can be of any further assistance please contact me.



**PATIENT**

Vince Hovey

Eric Lindquist, DMV, DABVP, Cert. IVUSS, CEO of SonoPath.com  
Eric.Lindquist@SonoPath.com

**SPECIES**

Canine

**BREED**

Lab Mix

**SEX**

MN

**AGE**

13

**WEIGHT**

68

**INTERPRETED BY**

Eric Lindquist, DMV  
DABVP, Cert. IVUSS

**IMAGING  
PERFORMED BY**

Jenn

**HOSPITAL NAME**

Rockaway Animal  
Hospital

**REFERRING VET**

Dr. Maniar

**INVOICE**

12943ag

**DATE**

02/13/2023