



**PATIENT**

Molly Vergano

**SPECIES**

Canine

**BREED**

Miniature Schnauzer

**SEX**

Spayed Female

**AGE**

14 Years

**WEIGHT**

17.8 Pounds

**INTERPRETED BY**

Eric Lindquist, DMV  
DABVP, Cert. IVUSS

**IMAGING PERFORMED BY**

Dr. Carlos Abdul-Chani

**HOSPITAL NAME**

Byram AH

**REFERRING VET**

Dr. Carlos Abdul-Chani

**INVOICE**

21072

**DATE**

2/13/23

**PRESENTING CLINICAL SIGNS**

History: Elevated liver values, cholesterol, and Triglycerides Current medications= Chitosan 250mg BID, I/D low fat

Abnormal PE/Chem/CBC/UA Results: ALT= 332 IU/L, ALP= 950 IU/L Cholesterol= 648mg/dl Triglycerides= 1281mg/dl urine specific gravity= 1.035

**ULTRASONOGRAPHIC EXAMINATION OF THE ABDOMEN**

**Urinary System**

The **urinary bladder**, trigone, and pelvic urethra presented normal thicknesses and normal tone. The ureters were not visible which is normal. No uroliths or sediment were visualized and anechoic urine was present. No evidence of inflammatory or neoplastic changes were noted. Ureteral papillae were normal. The pelvic urethra was imaged 3.0 cm beyond the cystourethral junction.

The **kidneys** revealed largely normal size and structure, corticomedullary definition and ratio (cortex 1/3 of medulla) were essentially maintained with some age-related loss of curvilinear patterns regarding the capsule and C/M junction. The cortices presented largely uniform texture with some increased echogenicity expected for his age patient. Medullary structure differed distinctly from that of the cortex and no evidence of pelvic dilation was present. The left kidney measured 4.5 cm. The right kidney measured 4.5 cm.

**Adrenal Glands**

Both **adrenal glands** were visualized and recognized as having normal shape, size, position and echogenicity for this breed. The phrenic vasculature, glandular echogenicity and detail were unremarkable. Capsule, cortex, and medullary definition were normal for this age patient. Multifocal areas of mineralization were noted in both adrenal glands. The left adrenal gland measured 2.01 cm x 0.4 cm at the caudal pole and 0.47 cm at the cranial pole. The right adrenal gland measured 2.06 cm x 0.79 cm at the cranial pole and 0.78 cm at the caudal pole.

**Spleen**

The **spleen** was normal size and relatively normal contour with moderate multifocal hyperechoic areas of mineralization. This is a benign change; however, can be related to Cushing's disease or other endocrinopathies.

**Liver**

The **liver** was uniformly swollen with minor, excessive gallbladder debris and over distension with dependent and suspended bile without evidence of overt mucocele formation. However, excessive sludge was present. The liver presented coarse architecture with mildly increased portal markings and subtle, mixed echogenic changes. This is consistent with vacuolar hepatopathy and some level of remodeling and history of inflammatory component. There was no overt suspicion of neoplasia.

**Gastrointestinal**

Examination of the **gastrointestinal tract** revealed a stomach and intestine free of stasis, of normal wall thickness, acceptable curvilinear mural detail, and peristaltic activity. Small and large intestine demonstrated normal luminal chyme and stool consistency respectively. No obstructive or overt infiltrative disease was noted. No associated abnormal lymphatic activity was noted.



**PATIENT**

**Pancreas**

Molly Vergano

The base and limbs of the **pancreas** were observed to be largely isoechoic to surrounding omental fat. Pancreatic duct and capsular contour were acceptably normal and parenchyma respected normal curvilinear patterns. No overt evidence of active inflammatory or neoplastic disease was noted.

**SPECIES**

Canine

**ULTRASONOGRAPHIC FINDINGS**

- Splenic and adrenal mineralization
- Benign hepatopathy
- Age-related renal changes

**BREED**

Miniature Schnauzer

**INTERPRETATION OF THE FINDINGS & FURTHER RECOMMENDATIONS**

**SEX**

Spayed Female

Even though the adrenal glands measured normal, underlying PDH is a potential. Full adrenal panel to University of Tennessee is recommended. Some inflammatory component in the liver is likely- FNA is indicated for further definition. Otherwise, the abdomen appears benign with likely underlying endocrinopathy.

**AGE**

14 Years

**WEIGHT**

17.8 Pounds

**INTERPRETED BY**

Eric Lindquist, DMV  
DABVP, Cert. IVUSS

**IMAGING PERFORMED BY**

Dr. Carlos Abdul-Chani

**HOSPITAL NAME**

Byram AH

**REFERRING VET**

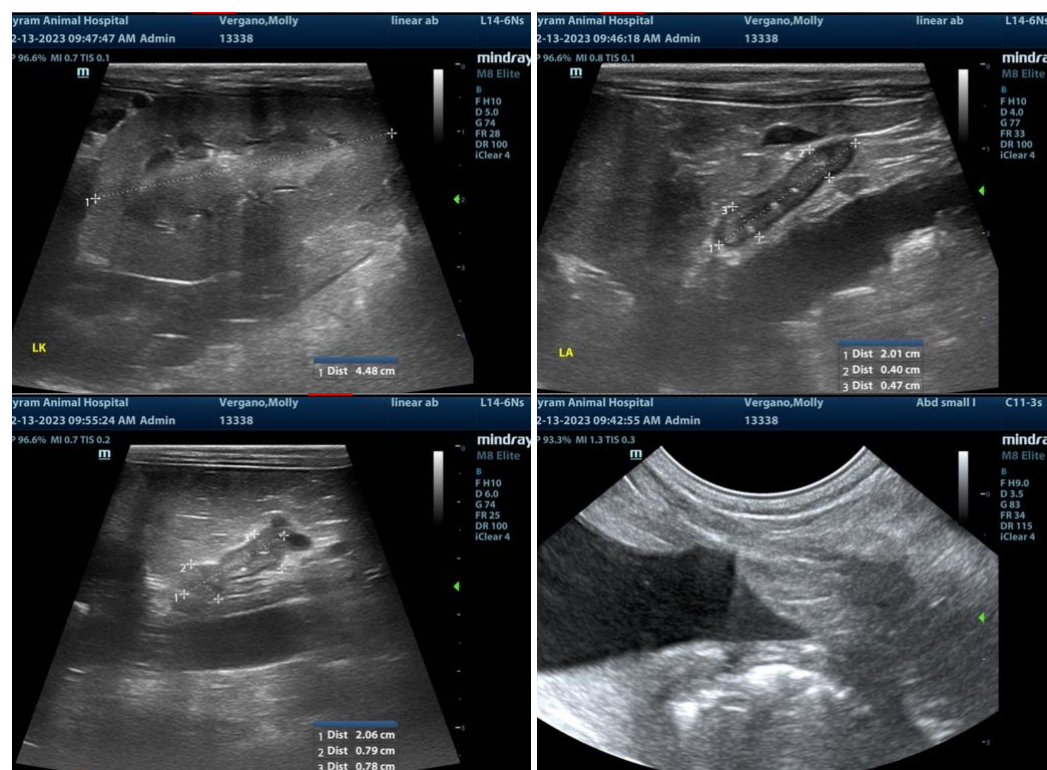
Dr. Carlos Abdul-Chani

**INVOICE**

21072

**DATE**

2/13/23





**PATIENT**

Molly Vergano

**SPECIES**

Canine

**BREED**

Miniature Schnauzer

**SEX**

Spayed Female

**AGE**

14 Years

**WEIGHT**

17.8 Pounds

**INTERPRETED BY**

Eric Lindquist, DMV  
DABVP, Cert. IVUSS

**IMAGING PERFORMED BY**

Dr. Carlos Abdul-Chani

**HOSPITAL NAME**

Byram AH

**REFERRING VET**

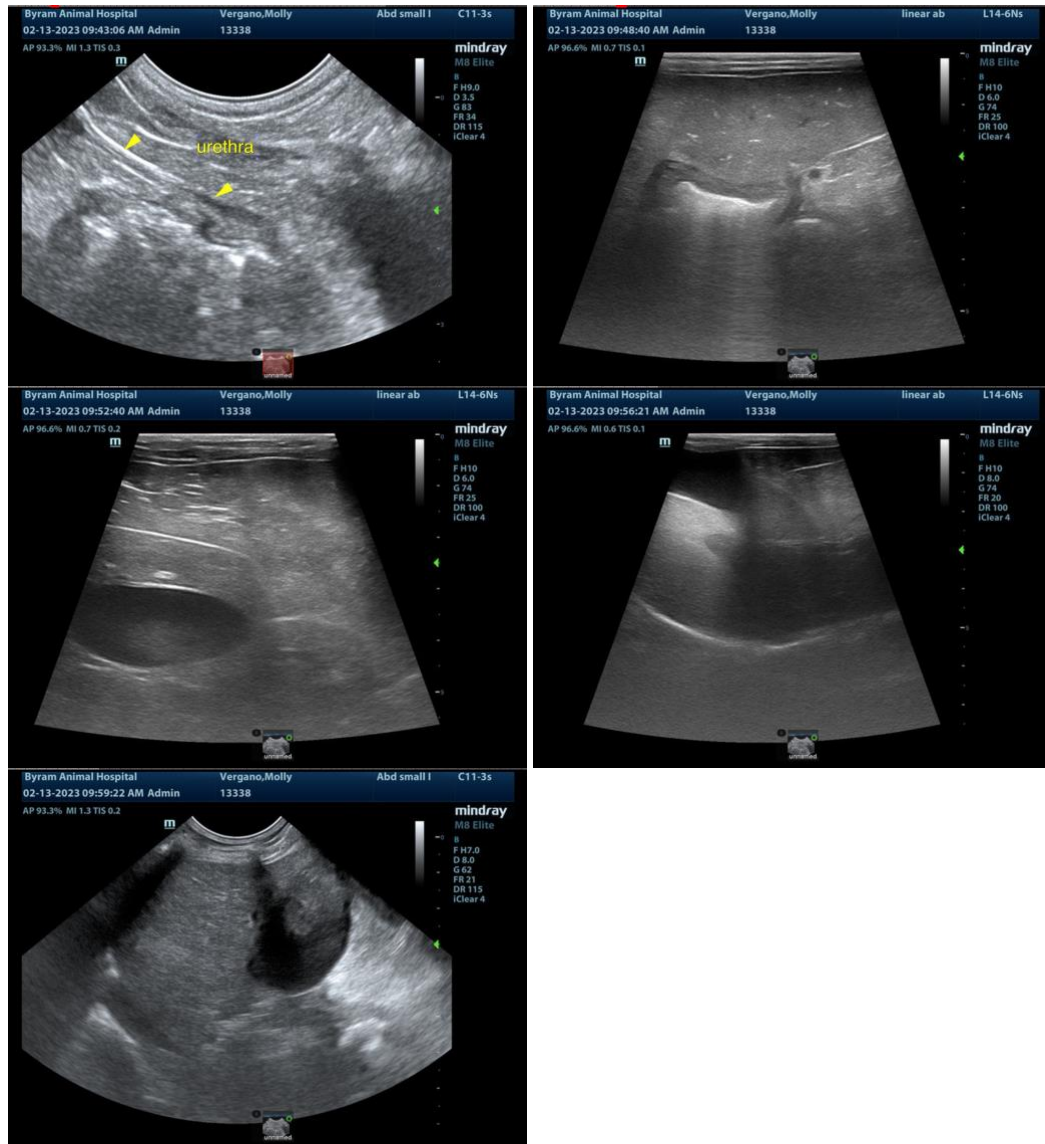
Dr. Carlos Abdul-Chani

**INVOICE**

21072

**DATE**

2/13/23



The information and recommendations provided are based on the images presented by the referring veterinarian. No evaluation can be communicated regarding pathology that was not visible in the image/video clips provided.

Thank you for this referral. If the clinical or image interpretation does not parallel your findings or if I can be of any further assistance please contact me.

**Eric Lindquist**, DMV, DABVP, Cert. IVUSS, CEO of SonoPath.com  
info@SonoPath.com