



PATIENT

Grover Dollins

SPECIES

Canine

BREED

Maltese X

SEX

Neutered Male

AGE

11 Years

WEIGHT

8.5

INTERPRETED BY

Eric Lindquist, DMV

DABVP, Cert. IVUSS

IMAGING PERFORMED BY

Dr. Neil Russell

HOSPITAL NAME

Frosted Faces Foundation

REFERRING VET

Dr. Neil Russell

INVOICE

45128

DATE

2/13/23

PRESENTING CLINICAL SIGNS

1. Consistently mildly low BG 66-69 x 3 over last 6 months (r/o anorexia vs neo vs insulinoma) PLUS: 1. Seizures - v infreq not on meds 2. Atopy - current flare up rubbing at eyes mostly 3. Murmur and CVD 4. Corneal edema OU 5. Tartar 3/4 6. Adenomas 7. Hx mild lab abnorms BUN 36, creat 1.6, alp 257, see below

Abnormal PE/Chem/CBC/UA Results: BUN 36, Creat 1.6 (mild prerenal azotemia) r/o dietary vs GI vs ++ ALP 257 r/o vacuolar vs Cu storage vs chronic hep vs cushings (USG 1.031) vs neoplasia vs chronic pancreatitis vs cholangitis vs choleolith vs +++ UA USG 1.031, quiet sediment Glucose 66-69 x 3 over last 6 months

ULTRASONOGRAPHIC EXAMINATION OF THE ABDOMEN

Urinary System

The **urinary bladder**, trigone, and pelvic urethra presented normal thicknesses and normal tone. The ureters were not visible which is normal. No uroliths or sediment were visualized and anechoic urine was present. No evidence of inflammatory or neoplastic changes were noted. Ureteral papillae were normal. The pelvic urethra was imaged 1.0 cm beyond the cystourethral junction.

The **kidneys** revealed largely normal size and structure, corticomedullary definition and ratio (cortex 1/3 of medulla) were essentially maintained with some age-related loss of curvilinear patterns regarding the capsule and C/M junction. The cortices presented largely uniform texture with some increased echogenicity expected for his age patient. Medullary structure differed distinctly from that of the cortex and no evidence of pelvic dilation was present. The right kidney measured 5.04 cm. The left kidney measured 4.8 cm.

Adrenal Glands

The **left adrenal gland** was slightly enlarged at the caudal pole, measuring 0.75 cm at the caudal pole and 0.51 cm at the cranial pole.

The **right adrenal gland** presented normal size and contour and measured 0.67 cm at the cranial pole and 0.46 cm at the caudal pole.

Spleen

The **spleen** presented a smooth homogeneous parenchyma hyperechoic to liver and renal cortical parenchyma. The capsule was smooth without noticeable expansion or deviation from within the spleen or adjacent pathology. The splenic vasculature demonstrated normal volume without signs of congestion or thrombosis. No sonographic evidence of acute or chronic inflammatory, neoplastic, or infarctual changes were noted.

Liver

The **liver** images from right and left intercostal as well as subcostal views revealed subjectively normal liver size, contour, and structure. Some age-related parenchymal remodeling was noted but likely not clinically significant at this time. Vascular and biliary tracts were of normal volume and no evidence of congestion was noted. The gallbladder presented some dependent debris with essentially normal contour. The cystic and common bile ducts were normal. No overt evidence of active inflammatory, infiltrative or regenerative pathology was noted but should be paired with current or past LE elevations regarding any clinical significance to this presentation. The hepatic lymph nodes were unremarkable.



PATIENT

Grover Dollins

SPECIES

Canine

BREED

Maltese X

SEX

Neutered Male

AGE

11 Years

WEIGHT

8.5

Gastrointestinal

Examination of the **gastrointestinal tract** revealed a stomach and intestine free of stasis, of normal wall thickness, acceptable curvilinear mural detail, and peristaltic activity. Small and large intestine demonstrated normal luminal chyme and stool consistency respectively. No obstructive or overt infiltrative disease was noted. No associated abnormal lymphatic activity was noted.

Pancreas

The base and limbs of the **pancreas** were observed to be largely isoechoic to surrounding omental fat. Some parenchymal remodeling, however, with mild deviation from curvilinear normalcy was observed. Pancreatic duct and capsular irregularities were present consistent with age related changes. If pain upon imaging (+ Murphy sign) was present or if the patient is focally painful in subxyphoid palpation then low-grade smoldering chronic pancreatitis should be suspected.

ULTRASONOGRAPHIC FINDINGS

- Unremarkable abdomen with minor age related changes

INTERPRETATION OF THE FINDINGS & FURTHER RECOMMENDATIONS

No evidence of significant disease. Supportive care should prove effective.

INTERPRETED BY

Eric Lindquist, DMV

DABVP, Cert. IVUSS

IMAGING PERFORMED BY

Dr. Neil Russell

HOSPITAL NAME

Frosted Faces Foundation

REFERRING VET

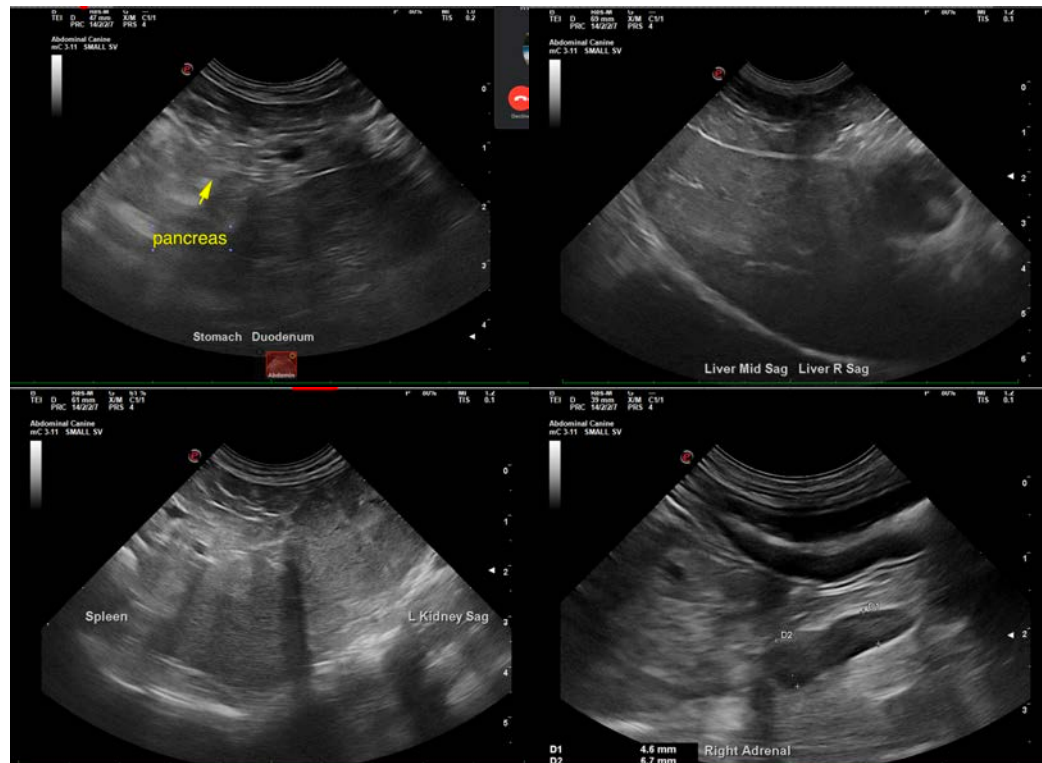
Dr. Neil Russell

INVOICE

45128

DATE

2/13/23





PATIENT

Grover Dollins

SPECIES

Canine

BREED

Maltese X

SEX

Neutered Male

AGE

11 Years

WEIGHT

8.5

INTERPRETED BY

Eric Lindquist, DMV

DABVP, Cert. IVUSS

IMAGING PERFORMED BY

Dr. Neil Russell

HOSPITAL NAME

Frosted Faces
Foundation

REFERRING VET

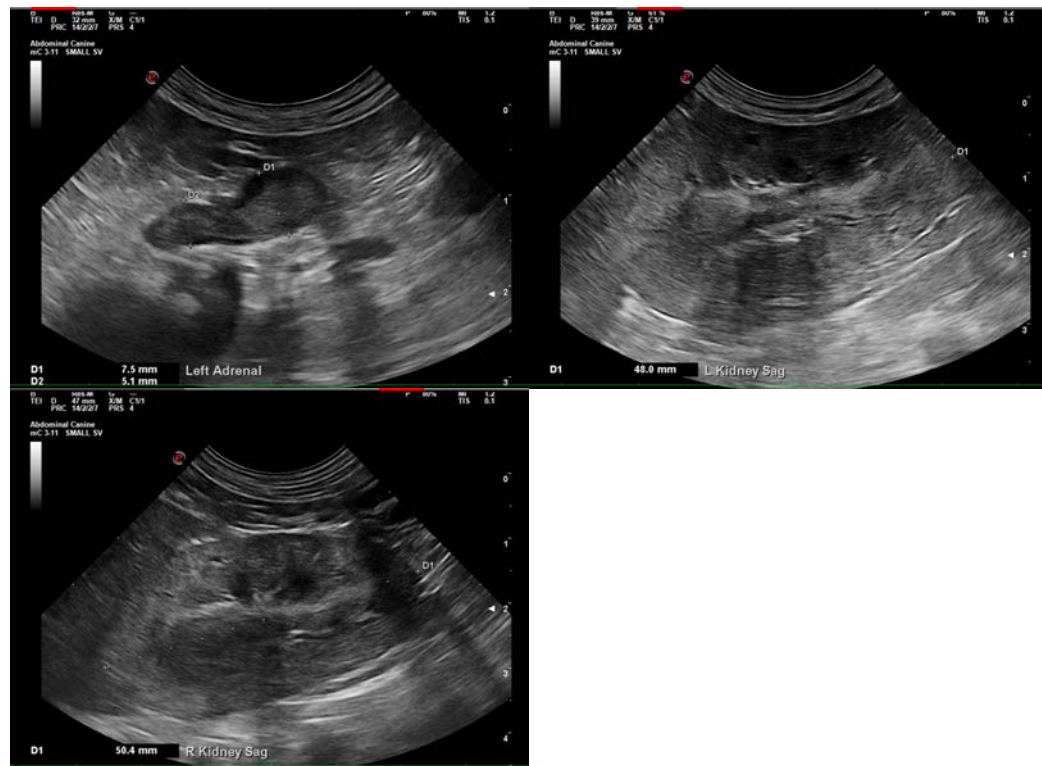
Dr. Neil Russell

INVOICE

45128

DATE

2/13/23



The information and recommendations provided are based on the images presented by the referring veterinarian/sonographer. No evaluation can be communicated regarding pathology that was not visible in the image/video clips provided.

Thank you for this referral. If the clinical or image interpretation does not parallel your findings or if I can be of any further assistance please contact me.

Eric Lindquist, DMV, DABVP, Cert. IVUSS, CEO of SonoPath.com

info@SonoPath.com



PATIENT

Grover Dollins

The following is an applicable excerpt from the *Curbside Guide to Diagnosis & Treatment of Sonographic Disease* offered by [SonoPath.com](http://www.sonopath.com) Lindquist, Frank, Lobetti, and Modler.

SPECIES

Canine


An essential quick guide for every general practitioner and sonographer.

BREED

Maltese X

SEX

Neutered Male



AGE

11 Years

WEIGHT

8.5

Hypoglycemic Syndrome: Insulinoma and Other

<http://www.sonopath.com/Hypoglycemia>

INTERPRETED BY

Eric Lindquist, DMV

DABVP, Cert. IVUSS

IMAGING PERFORMED BY

Dr. Neil Russell

HOSPITAL NAME

Frosted Faces Foundation

REFERRING VET

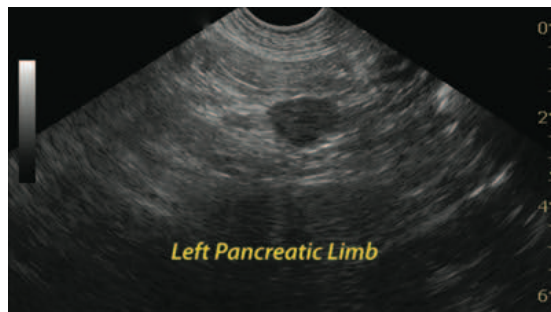Dr. Neil Russell

INVOICE

45128

DATE

2/13/23

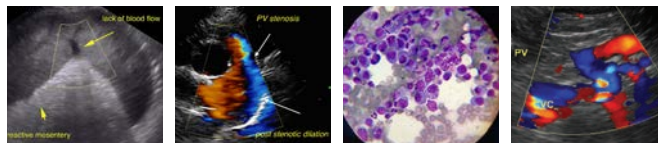


Short axis of the left pancreatic limb in a dog with an insulinoma seen as an ovoid hypoechoic mass lesion expanding the pancreatic capsule.

Description: Hypoglycemia can be found incidentally or associated with non-specific clinical signs, such as listlessness and weakness. It is essential to consider the multiple differentials for hypoglycemia in order to avoid a potential hypoglycemic crisis. One must perform a rapid and efficient workup to arrive at a diagnosis and prescribe the proper therapy.

Differentials for hypoglycemia include: laboratory or handling error; sepsis; toxins (e.g. xylitol, ethylene glycol); hunting dog hypoglycemia; Addison's disease; polycythemia; liver failure; poorly regulated diabetes mellitus; and neoplasia (e.g. leiomyosarcoma, hepatic, lymphoma, and insulinoma).

Once other causes of hypoglycemia have been ruled out, one may initiate an investigation into the



PATIENT

Grover Dollins

possibility of insulinoma. Insulinoma is a tumor of the pancreas that originates in the beta cells and leads to the unregulated secretion of insulin and hypoglycemic syndrome. The tumor can be a malignant carcinoma or a more benign form of adenoma. There is, however, controversy regarding the exact histopathology associated with insulinoma types.

SPECIES

Canine

BREED

Maltese X

Insulinoma patients are usually middle-aged dogs. Half of all cases present with metastasis to the lymph nodes, liver, and mesentery at the time of diagnosis. There are 3 stages of insulinoma:

SEX

Neutered Male

Stage 1: Pancreatic localization

AGE

11 Years

Stage 2: Pancreas and lymph nodes with a median survival time (MST) of 1.5 years

Stage 3: Organ metastasis with an MST of 6 months.

WEIGHT

8.5

Clinical Signs: Neuroglycopenia syndrome results in lethargy, ataxia, collapse, and seizures. Catecholamine release from hypoglycemia leads to hunger, behavior changes, and muscle tremors. Postprandial exacerbation of clinical signs can occur.

INTERPRETED BY

Eric Lindquist, DMV

DABVP, Cert. IVUSS

Diagnostics: When investigating for insulinoma, one should use a fluoride-containing tube (i.e., a grey top tube) to obtain an accurate glucose level. A fasting glucose level below 60 mg/dl is diagnostic for hypoglycemia. Insulinoma is indicated when one observes the Whipple's triad of hypoglycemia, clinical signs consistent are with hypoglycemia, and the latter resolve with the administration of dextrose.

IMAGING PERFORMED BY

Dr. Neil Russell

Fasting insulin and glucose ratio: A high normal to elevated insulin level with glucose < 60 mg/dl is diagnostic for insulinoma.

HOSPITAL NAME

Frosted Faces
Foundation

REFERRING VET

Dr. Neil Russell

Imaging: Localizing the lesion with staging is best approached by ultrasound. The ability to localize the lesion may be highly operator- and/or machine-dependent given the often small or even microscopic nature of insulinoma, especially early on in the disease. Primary or secondary lesions associated with insulinoma can often be identified with higher resolution sonography. Appropriate ultrasound-guided sampling (FNA or core biopsy) can be performed of any enlarged lymph node or hepatic nodule if a primary pancreatic lesion is not seen.

INVOICE

45128

DATE

2/13/23

Computed tomography (CT) with contrast is likely more sensitive than the average sonographer when it comes to assessing insulinoma.

Tumor staging and histopathological characterization in conjunction with the Ki67 biomarker index will yield solid criteria for the prognostic evaluation of insulinoma.



PATIENT

Grover Dollins

Treatment:

SPECIES

Canine

In cases of emergency hypoglycemic crisis, apply corn syrup to the gums. Administer a dextrose bolus (0.5g/kg IV) and maintain 2.5-10% dextrose solution. If cerebral edema occurs, one should administer dexamethasone (2 mg/kg IV) and give mannitol (0.5 mg/kg IV) over a 20-minute period.

BREED

Maltese X

One should perform a surgical pancreatectomy if the tumor is localized (i.e., stage 1 insulinoma). Given that the lesion may be difficult to locate with the naked surgical eye or via palpation, the surgical procedure can be enhanced by intraoperative ultrasound.

SEX

Neutered Male

AGE

11 Years

In cases of stage 2 and 3 insulinoma, administer prednisolone (0.25 mg/kg PO BID). A glucagon IV infusion has also been suggested; it should be infused with saline at 5 mg/kg/min for refractory cases. If prednisone is not adequate, one can supplement with benzothiadiazide diazixide (5 mg/kg PO BID).

WEIGHT

8.5

Patients should be fed small, frequent portions of a diet high in fat, complex carbohydrates, and protein.

INTERPRETED BY

Eric Lindquist, DMV

Chemotherapy: In some cases, the use of alloxan (65 mg/ kg IV) has been shown to be helpful.

DABVP, Cert. IVUSS

IMAGING PERFORMED BY

Dr. Neil Russell

Conclusion: The largest study of insulinoma patients identified a general MST of 547 days; however, the MST was 785 days for those undergoing pancreatectomy and 1316 days for those that relapsed after surgery and received treatment with prednisone. Other studies have reported an MST of 258 days with pancreatectomy. All of these results indicate that insulinoma is treatable. Using ultrasonography for staging and histopathological characterization is essential in order to determine whether the appropriate treatment should be surgical, medical, or both.

HOSPITAL NAME

Frosted Faces
Foundation

REFERRING VET

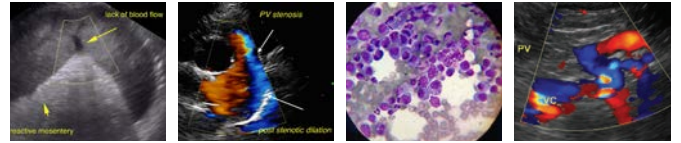
Dr. Neil Russell

INVOICE

45128

DATE

2/13/23



PATIENT

Grover Dollins

SPECIES

Canine

BREED

Maltese X

SEX

Neutered Male

AGE

11 Years

WEIGHT

8.5

INTERPRETED BY

Eric Lindquist, DMV

DABVP, Cert. IVUSS

IMAGING PERFORMED BY

Dr. Neil Russell

HOSPITAL NAME

Frosted Faces
Foundation

REFERRING VET

Dr. Neil Russell

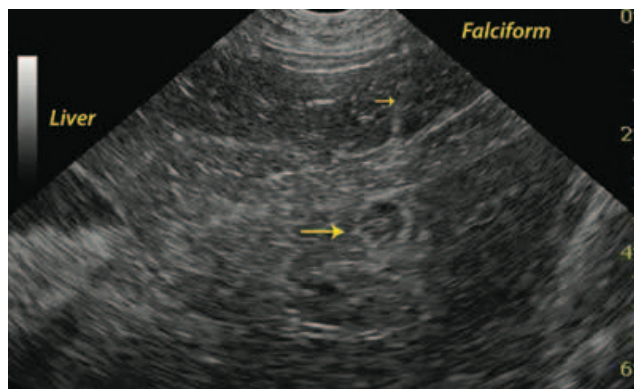
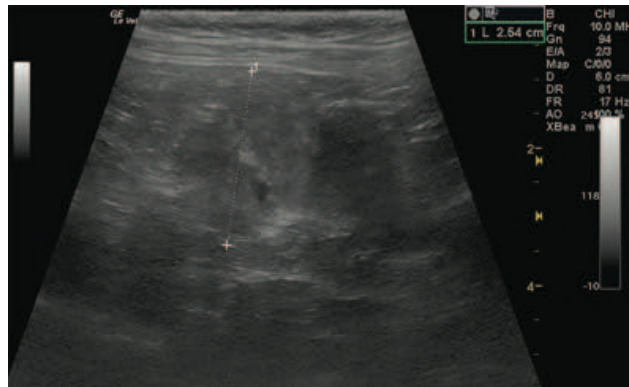
INVOICE

45128

DATE

2/13/23

Short axis of the left pancreatic limb in a cat with an insulinoma seen as a complex heterogenous mass lesion expanding the pancreatic capsule (between calipers). Note the mass effect of the tumor displacing the transverse colon caudally.



Subxiphoidal short axis of the liver in a dog with an insulinoma during ultrasound guided sampling of a suspected metastatic lesion.

The needle trajectory is seen as a hyperechoic line (small arrow) approaching the hypochoic nodule (large arrow) within the liver parenchyma.



PATIENT

Grover Dollins

SPECIES

Canine

BREED

Maltese X

SEX

Neutered Male

AGE

11 Years

WEIGHT

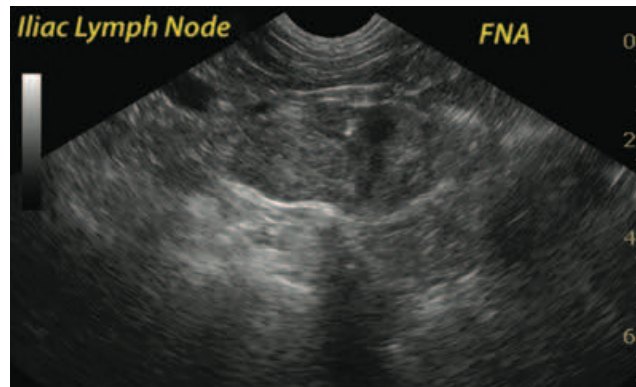
8.5

INTERPRETED BY

Eric Lindquist, DMV

DABVP, Cert. IVUSS

Long axis of the medial iliac lymph node during ne needle aspiration in a dog with multifocal metastatic spread of an insulinoma. The echogenic needle tip is seen within the lymph node. The metastatic lymph node is enlarged, rounded, hypoechoic and heterogenous. The primary metastatic loci in insulinoma are the regional lymph nodes (hepatic, pancreaticoduodenal, gastric) and the liver. Hence, metastatic insulinoma lesions in the iliac lymph node in this case was not a typical occurrence.



IMAGING PERFORMED BY

Dr. Neil Russell

HOSPITAL NAME

Frosted Faces Foundation

REFERRING VET

Dr. Neil Russell

INVOICE

45128

DATE

2/13/23

References:

Buishand FO, Kik M, Kirpensteijn J. Evaluation of clinico-pathological criteria and the Ki67 index as prognostic indicators in canine insulinoma. *Vet J* 2010;185:62-67.

Fischer JR, Smith SA, Harkin KR: Glucagon constant-rate infusion: A novel strategy for management of hyperinsulinemic-hypoglycemia crisis in the dog. *J Am Anim Hosp Assoc* 2000;36:27-32.

Polton GA, White RN, Brearley MJ, et al. Improved survival in a retrospective cohort of 28 dogs with insulinoma. *J Small Anim Pract* 2000;48:151-56.

Steiner JM, Bruyette DS: Canine insulinoma. *Compend Contin Educ Pract Vet* 1996;18:31-36.

Tobin RL, Nelson RW, Lucroy MD, et al. Outcome of surgical versus medical treatment of dogs with beta cell neoplasia: 39 cases (1990-1997). *JAVMA* 1999;215:226-30.