



PATIENT PRESENTING CLINICAL SIGNS

PATIENT Bandit Garman
SPECIES Canine
BREED Mix
SEX Neutered male
AGE 2 ½ years
WEIGHT 60.7 lbs

PRESENTING CLINICAL SIGNS
 History: BCS 5/9 Elevated ALT on BW 1/28, and 1yr previous which responded to Denamarin but increased again. P asymptomatic at that time, but did start vomiting this week. Always just stomach fluid, not soon after a meal
 Abnormal PE/Chem/CBC/UA Results: 5/2022 ALT 668 9/2022 ALT 117 (normal) 1/28/23 ALT 483

ULTRASONOGRAPHIC EXAMINATION OF THE ABDOMEN

Urinary System

The **urinary bladder**, trigone, and pelvic urethra presented normal thicknesses and normal tone. The pelvic urethra was imaged 1.0 cm beyond the cystourethral junction and appeared normal. The ureters were not visible which is normal. No uroliths or sediment were visualized and anechoic urine was present. No evidence of inflammatory or neoplastic changes was noted. Ureteral papillae were normal.

The **kidneys** revealed normal size and structure, corticomedullary definition and ratio for this age. The cortices presented largely uniform texture with normal echogenic relationship to liver and spleen. Medullary structure differed distinctly from the cortex and no evidence of pelvic dilation was present. The capsules were acceptably uniform without significant irregularities. The left kidney measured 6.2 cm. The right kidney measured 6.0 cm.

Adrenal Glands

Both **adrenal glands** were visualized and recognized as having normal shape, size, position and echogenicity for this breed. The phrenic vasculature, glandular echogenicity and detail were unremarkable. Capsule, cortex, and medullary definition were normal for this age patient. The left adrenal gland measured 0.45 cm at the caudal pole and 0.5 cm at the cranial pole. The right adrenal gland measured 0.9 cm at the cranial pole and 0.55 cm at the caudal pole.

Spleen

The **spleen** presented a smooth homogeneous parenchyma hyperechoic to liver and renal cortical parenchyma. The capsule was smooth without noticeable expansion or deviation from within the spleen or adjacent pathology. The splenic vasculature demonstrated normal volume without signs of congestion or thrombosis. No sonographic evidence of acute or chronic inflammatory, neoplastic, or infarctual changes was noted.

Liver

The **liver** images submitted revealed subjectively normal liver size, contour, and structure. Parenchymal echogenicity was naturally coarse and hypoechoic to the spleen. Vascular and biliary tracts were of normal volume with no evidence of congestion. The gallbladder presented acceptably thin walls with primarily anechoic content. The cystic and common bile ducts were normal. No pathological hepatic lymphadenopathy was evident. No overt structural evidence of inflammatory, infiltrative or regenerative pathology was evident.

INTERPRETED BY

Eric Lindquist, DMV
DABVP, Cert. IVUSS

IMAGING PERFORMED BY

Dr. Moon

HOSPITAL NAME

Shiloh VH

REFERRING VET

Dr. Moon

INVOICE

42766

DATE

2/13/23



PATIENT

Gastrointestinal

Bandit Garman

There was some residual chyme and gas was noted in the **stomach**, yet not pathological. This is consistent with end post prandial presentation. Transit of chyme into the small intestine was normal. Curvilinear patterns were maintained throughout the GI tract. No evidence of pathology. Small and large intestine demonstrated normal luminal chyme and stool consistency respectively. No obstructive or overt infiltrative disease was noted. No associated abnormal lymphatic activity was noted.

SPECIES

Canine

BREED

Pancreas

Mix

The base and limbs of the **pancreas** were observed to be largely isoechoic to surrounding omental fat. Pancreatic duct and capsular contour were acceptably normal and parenchyma respected normal curvilinear patterns. No overt evidence of active inflammatory or neoplastic disease was noted.

SEX

Neutered male

ULTRASONOGRAPHIC FINDINGS

AGE

Structurally unremarkable abdomen, non-specific inflammatory hepatopathy, likely reactive hepatopathy.

2 ½ years

WEIGHT

INTERPRETATION OF THE FINDINGS & FURTHER RECOMMENDATIONS

60.7 lbs

FNA of the liver can be considered for further definition.

INTERPRETED BY

Eric Lindquist, DMV
DABVP, Cert. IVUSS

The hepatic clinical sonographic presentation is most consistent with Reactive Hepatopathy which is the most common cause of liver enzyme elevation in dogs and cats. The presumption is that gut and other organ antigen stimuli may be causing a low-grade immune response through portal system with which the liver is reacting to causing low-grade enzyme elevations. US-guided FNA could be performed to assess if low grade lymphoplasmacytic inflammation is present that would support this theory. If FNA is performed, please ask the cytologist to emphasize the primary inflammatory cell type. Empirical treatment measures to address this issue can include diet change to hydrolyzed diet, probiotics, deworming, nutraceuticals (SAME, Actigall...), dental exam and cleaning, and potentially antibiotics such as Clavamox. Metronidazole and Tylosin have traditionally been utilized for this purpose but new studies show that both these antibiotics can disrupt the normal intestinal bacterial flora (intestinal dysbiosis) for weeks and up to 4-6 months. Therefore, Metronidazole and Tylosin should be utilized as a last resort if other efforts have not been effective and sonographic organ appearance remains benign.

IMAGING PERFORMED BY

Dr. Moon

HOSPITAL NAME

Shiloh VH

REFERRING VET

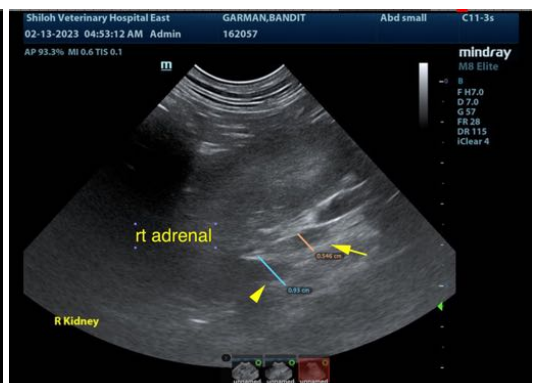
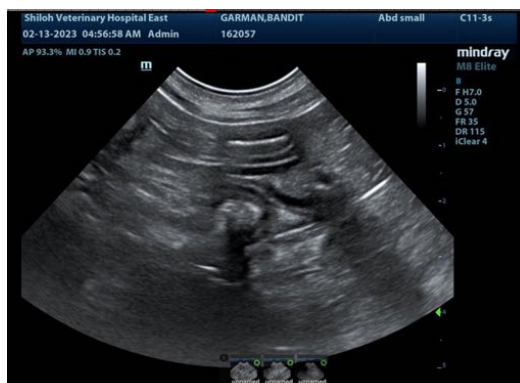Dr. Moon

INVOICE

42766

DATE

2/13/23





PATIENT

Bandit Garman

SPECIES

Canine

BREED

Mix

SEX

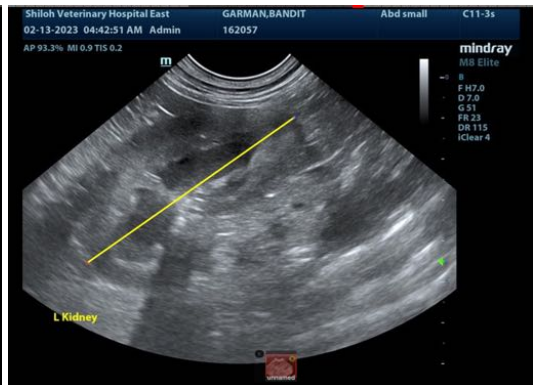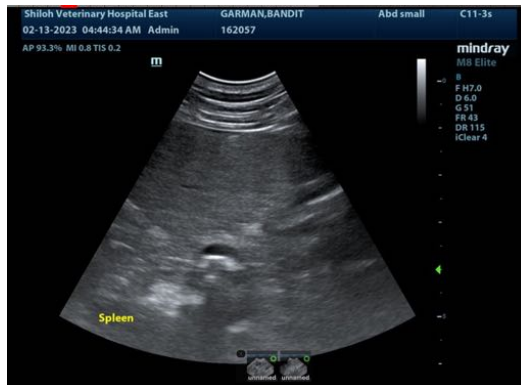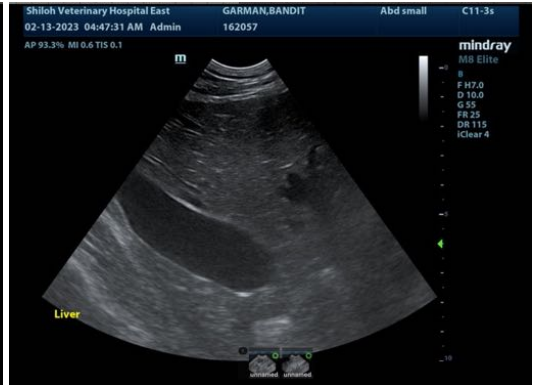
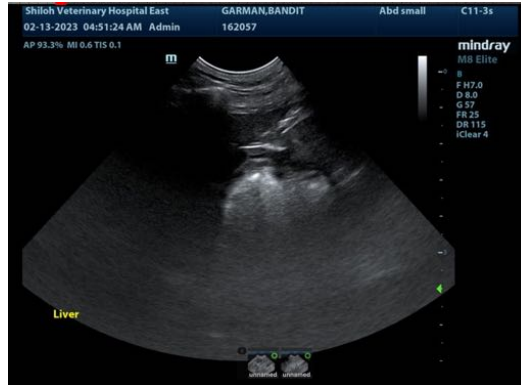
Neutered male

AGE

2 ½ years

WEIGHT

60.7 lbs



INTERPRETED BY

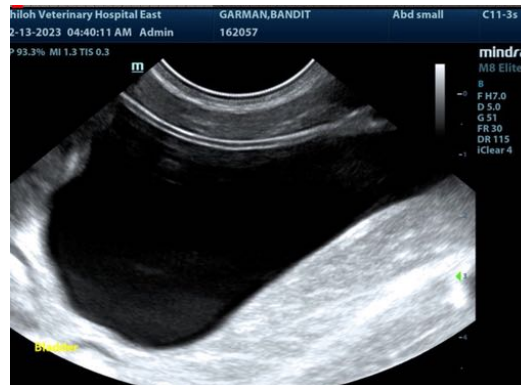
Eric Lindquist, DMV
DABVP, Cert. IVUSS

IMAGING PERFORMED BY

Dr. Moon

HOSPITAL NAME

Shiloh VH



REFERRING VET

Dr. Moon

INVOICE

42766

DATE

2/13/23

The information and recommendations provided are based on the images presented by the referring veterinarian/sonographer. No evaluation can be communicated regarding pathology that was not visible in the image/video clips provided.

Thank you for this referral. If the clinical or image interpretation does not parallel your findings or if I can be of any further assistance please contact me.

Eric Lindquist, DMV, DABVP, Cert. IVUSS, CEO of SonoPath.com
info@SonoPath.com