



## PATIENT

Ash Northstar Rescue

## SPECIES

Canine

## BREED

Belgian Malinois Mix

## SEX

Female

## AGE

1

## WEIGHT

64

## INTERPRETED BY

Eric Lindquist, DMV  
DABVP, Cert. IVUSS

## IMAGING PERFORMED BY

Jenn

## HOSPITAL NAME

Rockaway AH

## REFERRING VET

Dr. Kahn

## INVOICE

21080

## DATE

2/13/23

## PRESENTING CLINICAL SIGNS

History: Follow up from a aortic stenosis from another clinic, doing well at home no clinical signs

## ULTRASONOGRAPHIC EXAMINATION OF THE HEART

CANINE CARDIAC PARAMETERS	MR VMAX (m/s)	TR VMAX (m/s)	LA/AO (Boon method)	LA/AO (Heart Base; Swe)	FS (%)	EF (%)	EPSS (cm)
NORMAL PARAMETER	4.5-5.5	<2.7	1.3	<1.3	28-40	40-100	<0.6
PATIENT	--	--	1.0	1.0	40	90	0.2
CANINE CARDIAC PARAMETERS	HR (BPM)	AV VMAX (m/s)	PV MAX (m/s)	BODY WEIGHT (kg)	LA 2D short axis Base view (cm)	LVIDd Avg; 2D and m-mode short axis (cm)	LVIDs Avg; 2D and m-mode short axis (cm)
NORMAL PARAMETER	50-100	0.7-1.7	0.7-1.6				
PATIENT	--	--	.93	--	--	4.6	--

## Cardiac Presentation

The echocardiogram in this patient demonstrated normal **left atrial** size based on 3 separate methods of LA evaluation. The cranial and caudal **mitral** valve leaflets presented normal linear structure, extension in systole, and union in diastole with normal kinesis. The aortic valve itself was thickened.

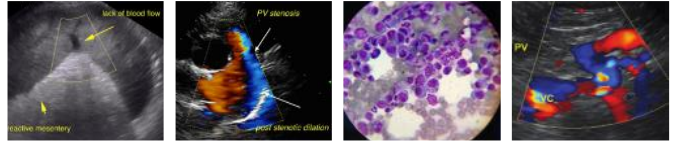
The **myocardium** presented normal echogenicity without subjective evidence of significant fibrotic or ischemic disease. **Contractility** of the ventricular walls was adequate and in normal range for this patient evidenced by the fractional shortening measurement and subjective evaluation of the different regions of the myocardium. Aortic insufficiency was noted on color flow assessment. The **right atrium** and auricle revealed normal size, structure and content. No evidence of masses was noted. Trivial **tricuspid** insufficiency was noted. The **right ventricle** was of normal size (1/3 diameter of LV), chordae structure, myocardial echogenicity and thickness. Trivial pulmonic insufficiency was noted. No visible **pericardial** or free pleura fluid was noted. The cranial **mediastinum and pericardial and extra-cardiac regions** were free of masses in the visible window. Occasional arrhythmia was noted-EKG is indicated.

## ULTRASONOGRAPHIC FINDINGS

- Aortic insufficiency with aortic valve dysplasia (to be defined further), compensated at this time
- Trivial tricuspid and pulmonic insufficiency

## INTERPRETATION OF THE FINDINGS & FURTHER RECOMMENDATIONS

The aortic valve itself was thickened. Further spectral doppler assessment of the aortic outflow is indicated in this patient, as the outflow velocity appears to be normal, however, I suspect a higher



**PATIENT**

velocity.

Ash Northstar Rescue

**SPECIES**

Canine

**BREED**

Belgian Malinois Mix

**SEX**

Female

**AGE**

1

**WEIGHT**

64

**INTERPRETED BY**

Eric Lindquist, DMV  
DABVP, Cert. IVUSS

**IMAGING PERFORMED BY**

Jenn

**HOSPITAL NAME**

Rockaway AH

**REFERRING VET**

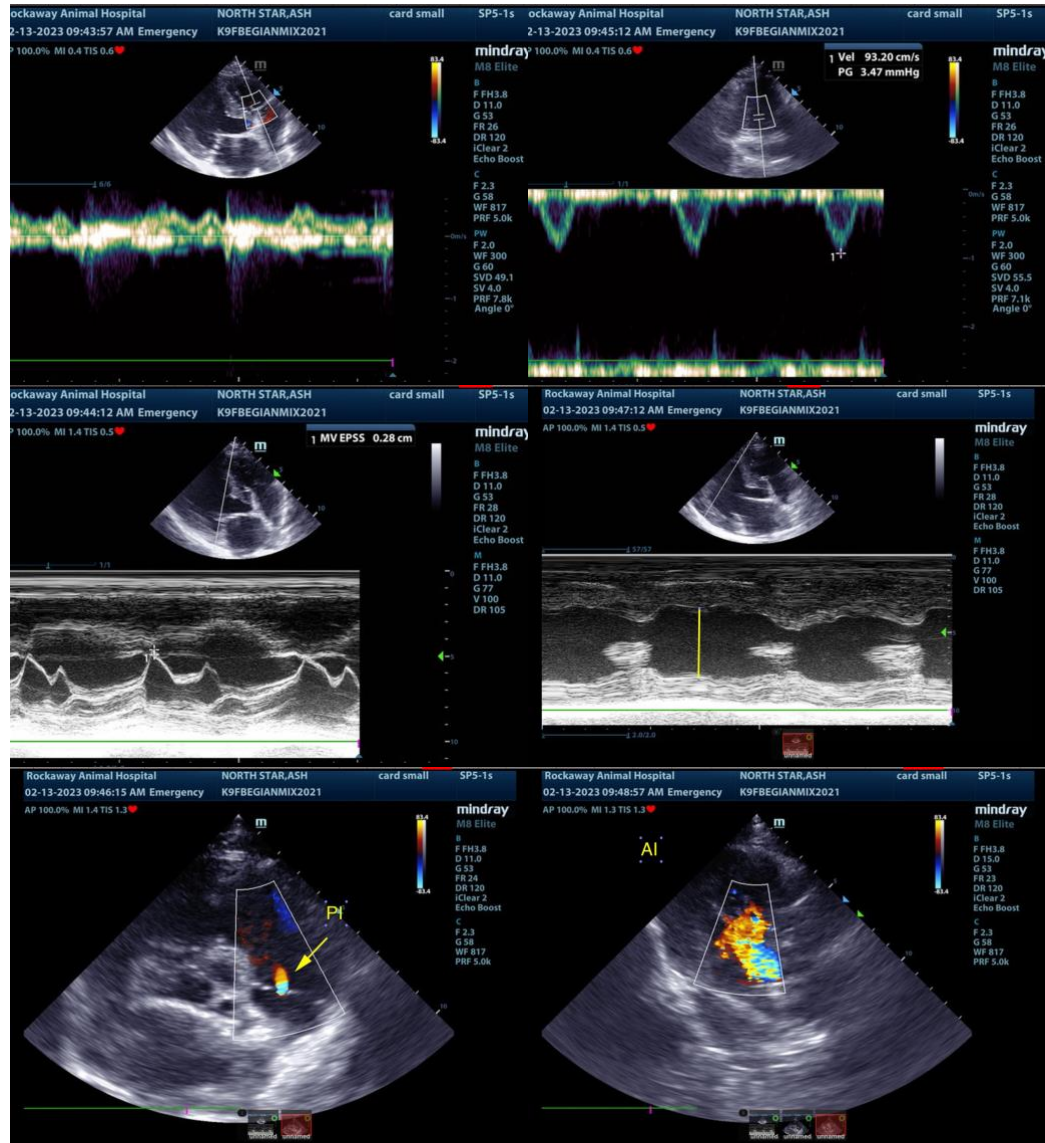
Dr. Kahn

**INVOICE**

21080

**DATE**

2/13/23



The information and recommendations provided are based on the images presented by the referring veterinarian. No evaluation can be communicated regarding pathology that was not visible in the image/video clips provided.

Thank you for this referral. If the clinical or image interpretation does not parallel your findings or if I can be of any further assistance please contact me.

**Eric Lindquist**, DMV, DABVP, Cert. IVUSS, CEO of SonoPath.com  
info@SonoPath.com