



**PATIENT**

Vargas Kai

**SPECIES**

Other

**BREED**

Ferret

**SEX**

Neutered Male

**AGE**

5 Years

**WEIGHT**

Not Provided

**INTERPRETED BY**

Eric Lindquist, DMV,  
DABVP (CFM), Cert.  
IVUSS

**IMAGING  
PERFORMED BY**

Kerri Becker

**HOSPITAL NAME**

Paws Wings Scales AH

**REFERRING VET**

Dr. Stancel

**INVOICE**

35817

**DATE**

2/12/26

**PRESENTING CLINICAL SIGNS**

Enlarged spleen, possible thickened intestines.

**ULTRASONOGRAPHIC EXAMINATION OF THE ABDOMEN**

**Urinary System**

The **urinary bladder**, trigone, and pelvic urethra presented normal thicknesses and normal tone. The ureters were not visible which is normal. No uroliths or sediment were visualized and anechoic urine was present. No evidence of inflammatory or neoplastic changes were noted. Ureteral papillae were normal. The pelvic urethra was imaged 1.0 cm beyond the cystourethral junction.

The **kidneys** revealed normal size and structure, corticomedullary definition and ratio for this age. The cortices presented largely uniform texture with normal echogenic relationship to liver and spleen. Medullary structure differed distinctly from the cortex, and no evidence of pelvic dilation was present. The capsules were acceptably uniform without significant irregularities. The right kidney measured 2.61 cm. The left kidney measured 2.7 cm.

**Adrenal Glands**

Both **adrenal glands** were visualized and recognized as having normal shape, size, position and echogenicity for this breed. The phrenic vasculature, glandular echogenicity and detail were unremarkable. Capsule, cortex, and medullary definition were normal for this age patient. The right adrenal gland measured 0.3 cm. The left adrenal gland measured 0.3 cm.

**Spleen**

The **spleen** was mildly enlarged and folded upon itself caudally.

**Liver**

The **liver** images from right and left intercostal as well as subcostal views revealed subjectively normal liver size, contour, and structure. Some minor age-related parenchymal remodeling was noted but likely not clinically significant at this time. Vascular and biliary tracts were of normal volume, and no evidence of congestion was noted. The gallbladder presented some dependent debris with essentially normal contour. The cystic and common bile ducts were normal. No overt evidence of active inflammatory, infiltrative or regenerative pathology was noted but should be paired with current or past LE elevations regarding any clinical significance to this presentation. The hepatic lymph nodes were unremarkable.

**Gastrointestinal**

Examination of the **gastrointestinal tract** revealed a stomach and intestine free of stasis, of normal wall thickness, acceptable curvilinear mural detail, and peristaltic activity. Small and large intestine demonstrated normal luminal chyme and stool consistency respectively. No obstructive or overt infiltrative disease was noted. No associated abnormal lymphatic activity was noted.

**Pancreas**



**PATIENT**

Vargas Kai

**SPECIES**

Other

**BREED**

Ferret

**SEX**

Neutered Male

**AGE**

5 Years

**WEIGHT**

Not Provided

**INTERPRETED BY**

Eric Lindquist, DMV,  
DABVP (CFM), Cert.  
IVUSS

**IMAGING PERFORMED BY**

Kerri Becker

**HOSPITAL NAME**

Paws Wings Scales AH

**REFERRING VET**

Dr. Stancel

**INVOICE**

35817

**DATE**

2/12/26

The base and limbs of the **pancreas** were observed to be largely isoechoic to surrounding omental fat. Pancreatic duct and capsular contour were acceptably normal and parenchyma respected normal curvilinear patterns. No overt evidence of active inflammatory or neoplastic disease was noted.

**Free Abdomen**

A large amount of **abdominal fat** was noted in this patient.

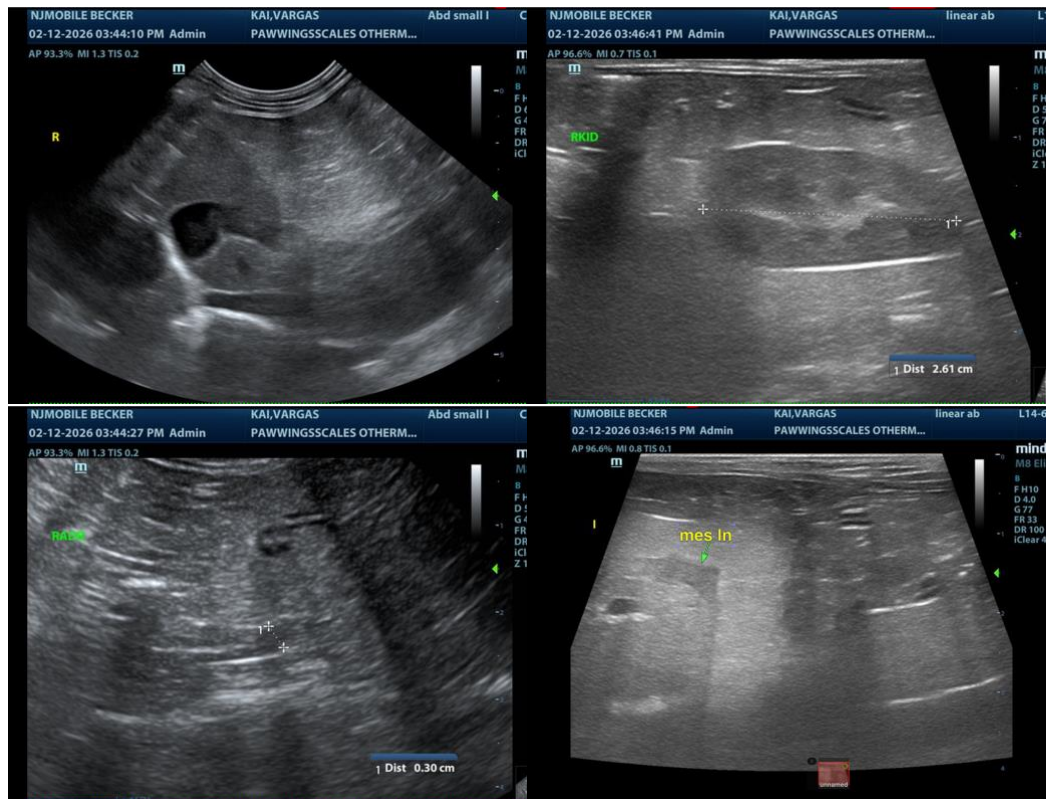
The **mesenteric lymph nodes** were slightly enlarged (up to 8.0 mm x 4.0 mm). The lymph nodes presented normal length to width ratio with slight, swollen contour. There was no loss of parenchymal detail. This is most consistent with reactive lymphadenitis or lymphatic hyperplasia.

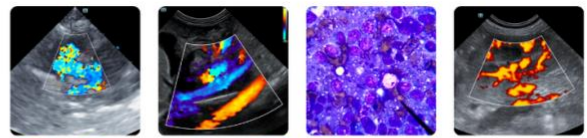
**ULTRASONOGRAPHIC FINDINGS**

- Structurally unremarkable abdomen with excessive abdominal fat and mild splenomegaly
- Slightly enlarged/reactive mesenteric lymph nodes

**INTERPRETATION OF THE FINDINGS & FURTHER RECOMMENDATIONS**

Superimpositioning of the fat upon the organs may create an appearance of organ enlargement yet splenomegaly was minor. A reactive state is likely.





**PATIENT**

Vargas Kai

**SPECIES**

Other

**BREED**

Ferret

**SEX**

Neutered Male

**AGE**

5 Years

**WEIGHT**

Not Provided

**INTERPRETED BY**

Eric Lindquist, DMV,  
DABVP (CFM), Cert.  
IVUSS

**IMAGING PERFORMED BY**

Kerri Becker

**HOSPITAL NAME**

Paws Wings Scales AH

**REFERRING VET**

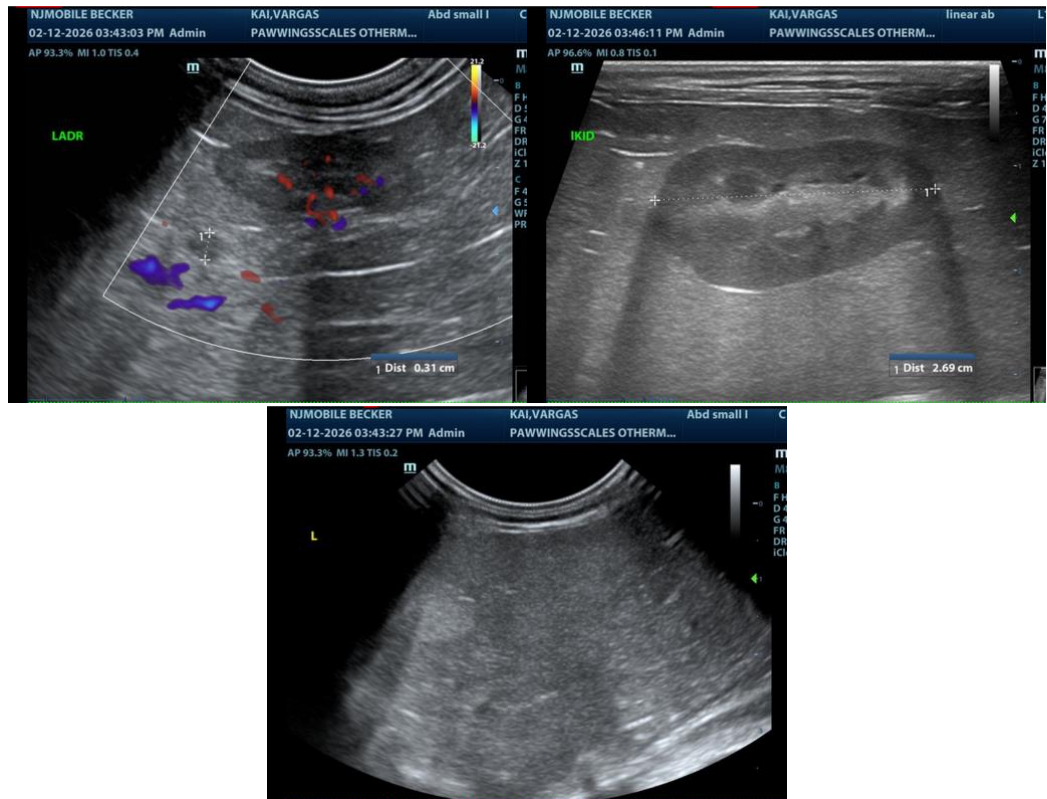
Dr. Stancel

**INVOICE**

35817

**DATE**

2/12/26



**The information and recommendations provided are based on the images presented by the referring veterinarian/sonographer. No evaluation can be communicated regarding pathology that was not visible in the image/video clips provided.**

Thank you for this referral. If the clinical or image interpretation does not parallel your findings or if I can be of any further assistance please contact me.

**Eric Lindquist**, DMV, DABVP(CFM), Cert. IVUSS,  
CEO, Owner, Founder -- SonoPath.com  
[info@SonoPath.com](mailto:info@SonoPath.com)