



PATIENT

Mona Arnold

SPECIES

Feline

BREED

DSH

SEX

Spayed Female

AGE

10 Years

WEIGHT

Not Provided

INTERPRETED BY

Eric Lindquist, DMV,
DABVP (CFM), Cert.
IVUSS

IMAGING PERFORMED BY

Eric Lindquist, DMV,
DABVP (CFM), Cert.
IVUSS

HOSPITAL NAME

Franklin Lakes Animal
Hospital

REFERRING VET

Dr. Rizzo

INVOICE

72897

DATE

2/12/26

PRESENTING CLINICAL SIGNS

Weight loss, chronic diarrhea. Rule out CKD vs pyelo and IBD vs LSA vs maldig.

USG 1.019, SDMA 25, Crea 3.4, BUN 54, T4 WNL.

ULTRASONOGRAPHIC EXAMINATION OF THE ABDOMEN

Urinary System

The **urinary bladder**, trigone, and pelvic urethra presented normal thicknesses and normal tone. The ureters were not visible which is normal. No uroliths or sediment were visualized and anechoic urine was present. No evidence of inflammatory or neoplastic changes were noted. Ureteral papillae were normal.

The **left kidney** presented severe end stage dystrophic changes, measuring 2.0 cm, with echogenic remodeling and mineralization.

The **right kidney** presented moderate degenerative changes, measuring 3.5 cm. Cortical remodeling and slight pyelectasia noted. No evidence of masses or current obstructive disease.

Adrenal Glands

The regions of the **adrenal glands** were unremarkable.

Spleen

The **spleen** presented a smooth homogeneous parenchyma hyperechoic to liver and renal cortical parenchyma. The capsule was smooth without noticeable expansion or deviation from within the spleen or adjacent pathology. The splenic vasculature demonstrated normal volume without signs of congestion or thrombosis. No sonographic evidence of acute or chronic inflammatory, neoplastic, or infarctual changes were noted.

Liver

The **liver** images submitted revealed subjectively normal liver size, contour, and structure. Parenchymal echogenicity was naturally coarse and hypoechoic to the spleen. Vascular and biliary tracts were of normal volume with no evidence of congestion. The gallbladder presented acceptably thin walls with primarily anechoic content. The cystic and common bile ducts were normal. No pathological hepatic lymphadenopathy was evident. No overt structural evidence of inflammatory, infiltrative or regenerative pathology was evident.

Gastrointestinal

The **gastrointestinal tract** revealed minor variable thickening and echogenic submucosal changes most consistent with low grade end result of chronic GI disease such as IBD and may be related to malassimilation of nutrients if any weight loss is present. No obvious neoplastic patterns were noted and luminal content as unremarkable.

Pancreas

The base and limbs of the **pancreas** were observed to be largely isoechoic to surrounding omental fat. Pancreatic duct and capsular contour were acceptably normal and parenchyma respected normal curvilinear patterns. No overt evidence of active inflammatory or neoplastic disease was noted.



PATIENT

Mona Arnold

SPECIES

Feline

BREED

DSH

SEX

Spayed Female

AGE

10 Years

WEIGHT

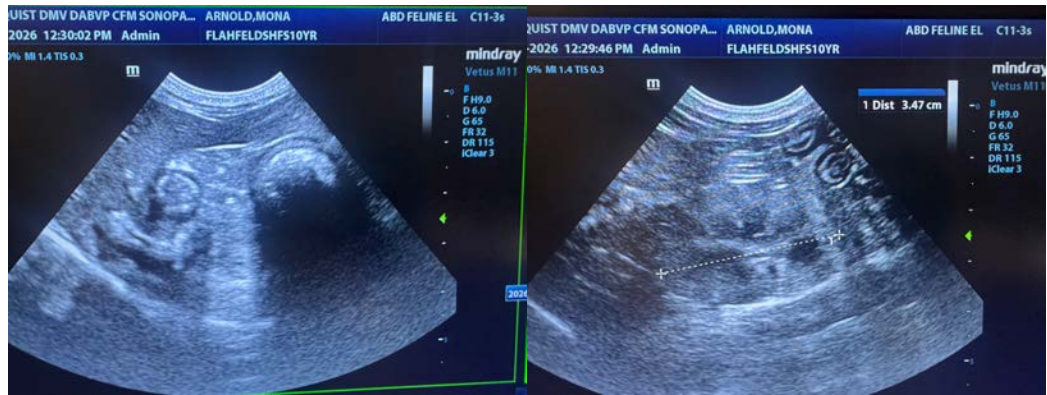
Not Provided

ULTRASONOGRAPHIC FINDINGS

- End stage left kidney, moderate degenerative right kidney.
- Age related GI changes.

INTERPRETATION OF THE FINDINGS & FURTHER RECOMMENDATIONS

72 hour IV fluid protocol, blood pressure, urine culture all indicated. Prognosis is guarded long-term depending upon response to therapy.



INTERPRETED BY

Eric Lindquist, DMV,
 DABVP (CFM), Cert.
 IVUSS

IMAGING PERFORMED BY

Eric Lindquist, DMV,
 DABVP (CFM), Cert.
 IVUSS

HOSPITAL NAME

Franklin Lakes Animal
 Hospital

REFERRING VET

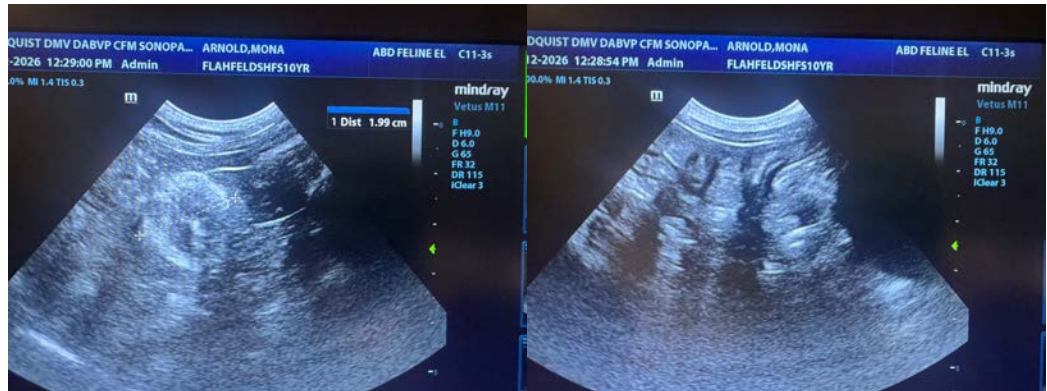
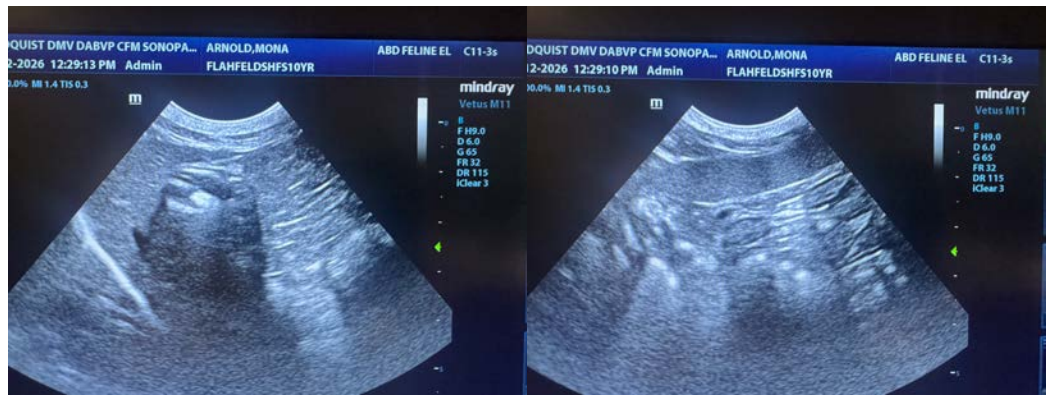
Dr. Rizzo

INVOICE

72897

DATE

2/12/26





PATIENT

Mona Arnold

SPECIES

Feline

BREED

DSH

SEX

Spayed Female

AGE

10 Years

WEIGHT

Not Provided

INTERPRETED BY

Eric Lindquist, DMV,
DABVP (CFM), Cert.
IVUSS

IMAGING PERFORMED BY

Eric Lindquist, DMV,
DABVP (CFM), Cert.
IVUSS

HOSPITAL NAME

Franklin Lakes Animal
Hospital

REFERRING VET

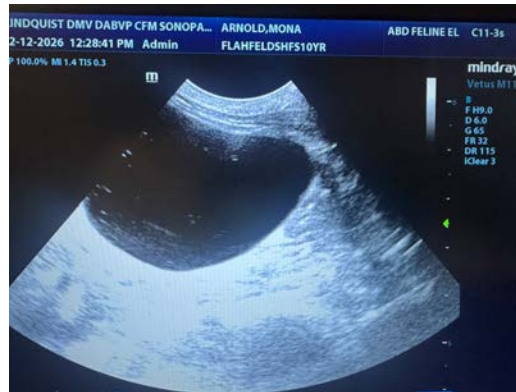Dr. Rizzo

INVOICE

72897

DATE

2/12/26



The information and recommendations provided are based on the images presented by the referring veterinarian/sonographer. No evaluation can be communicated regarding pathology that was not visible in the image/video clips provided.

Thank you for this referral. If the clinical or image interpretation does not parallel your findings or if I can be of any further assistance please contact me.

Eric Lindquist, DMV, DABVP(CFM), Cert. IVUSS,
CEO, Owner, Founder -- SonoPath.com
info@SonoPath.com