

PATIENT

Casey Joseph

SPECIES

Feline

BREED

Himalayan

SEX

Neutered Male

AGE

17 Years 8 Months

WEIGHT

Not Provided

INTERPRETED BY

Eric Lindquist, DMV,
DABVP (CFM), Cert.
IVUSS

IMAGING PERFORMED BY

Kerri Becker

HOSPITAL NAME

Pawsd Wings Scales
AH

REFERRING VET

Dr. Stancel

INVOICE

35818

DATE

2/12/26

PRESENTING CLINICAL SIGNS

O concerned something in pets throat, O says pet eats oddly, makes a motion as if something in the throat, low grade murmur.

Abnormal PE/Chem/CBC/UA Results: BUN-63 creat-4.1 SDMA-26.6 Hct-26

ULTRASONOGRAPHIC EXAMINATION OF THE THYROID

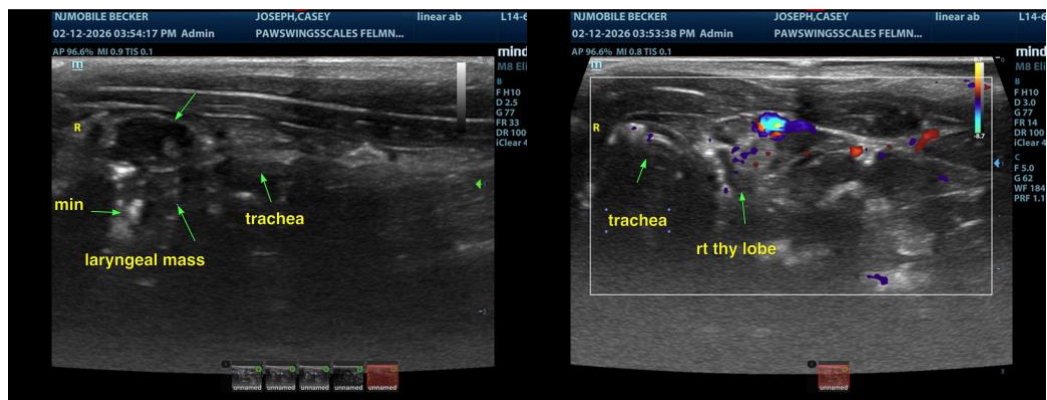
Multiple video images were taken of the left and right thyroid regions, as well as the trachea, larynx, and esophagus. The junction between the larynx and trachea revealed a concentric 1.22 cm mass with thickening of approximately 5.0 mm, stricturing the lumen, and creating a loss of structural detail in the larynx at the junction with the trachea. Esophagus, thyroid lobes, and regional vasculature were unremarkable.

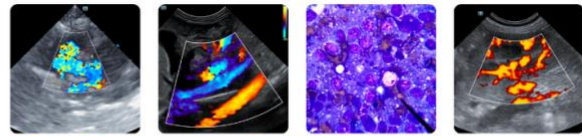
ULTRASONOGRAPHIC FINDINGS

- Mass in the junction between the larynx and trachea - laryngeal carcinoma or sarcoma is suspected.

INTERPRETATION OF THE FINDINGS & FURTHER RECOMMENDATIONS

Endoscopy would be ideal to assess the aperture of the lumen. Ultrasound guided FNA of the mass may be difficult to obtain a definitive diagnosis yet could be attempted. Prognosis is guarded to poor, depending upon eventual responsiveness to chemotherapy or radiation therapy.





PATIENT

Casey Joseph

SPECIES

Feline

BREED

Himalayan

SEX

Neutered Male

AGE

17 Years 8 Months

WEIGHT

Not Provided

INTERPRETED BY

Eric Lindquist, DMV,
 DABVP (CFM), Cert.
 IVUSS

IMAGING PERFORMED BY

Kerri Becker

HOSPITAL NAME

Pawsd Wings Scales
 AH

REFERRING VET

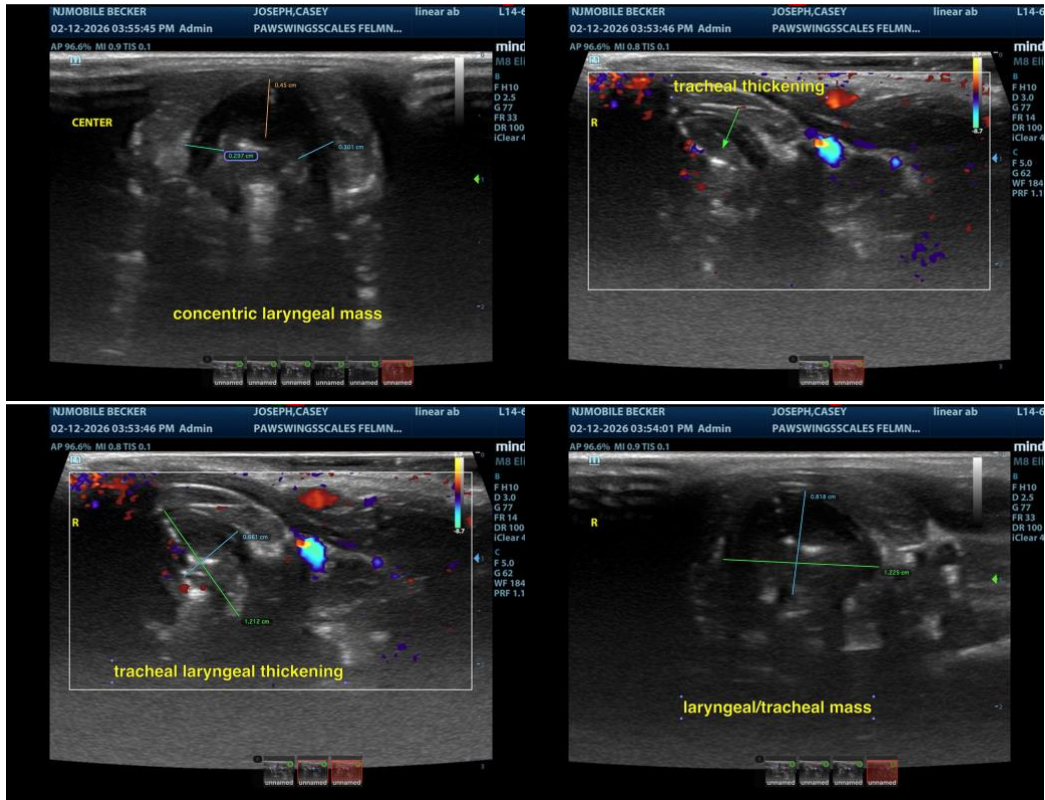
Dr. Stancel

INVOICE

35818

DATE

2/12/26



The information and recommendations provided are based on the images presented by the referring veterinarian/sonographer. No evaluation can be communicated regarding pathology that was not visible in the image/video clips provided.

Thank you for this referral. If the clinical or image interpretation does not parallel your findings or if I can be of any further assistance please contact me.

Eric Lindquist, DMV, DABVP(CFM), Cert. IVUSS,
 CEO, Owner, Founder -- SonoPath.com
info@SonoPath.com