



## PATIENT

Melo Tripodi

## SPECIES

Canine

## BREED

Shih Tzu

## SEX

Neutered male

## AGE

7 years

## WEIGHT

12.5 lbs

## INTERPRETED BY

Eric Lindquist, DMV  
DABVP, Cert. IVUSS

## IMAGING PERFORMED BY

Dr. Salas

## HOSPITAL NAME

Tenafly VC

## REFERRING VET

Dr. Salas

## INVOICE

71517

## DATE

2/11/26

## PRESENTING CLINICAL SIGNS

- History is that he is 7 years old and 12.5 lbs. He has low grade azotemia with isosthenuric urine. Clinically well with no PU/PD. All else is well and that low dose DTK used for the exam due to temperament
- That BP was 75 under sedation
- And that UCS pending

## ULTRASONOGRAPHIC EXAMINATION OF THE ABDOMEN

### Urinary System

The **urinary bladder**, trigone, and pelvic urethra presented normal thicknesses and normal tone. The ureters were not visible which is normal. No uroliths or sediment were visualized and anechoic urine was present. No evidence of inflammatory or neoplastic changes was noted. Ureteral papillae were normal.

The **kidneys** revealed largely normal size and structure, corticomedullary definition and ratio (cortex 1/3 of medulla) were essentially maintained with some age-related loss of curvilinear patterns regarding the capsule and C/M junction. Hyperechoic medullary rim sign was noted. The cortices presented largely uniform texture with some increased echogenicity expected for this age patient. Medullary structure differed distinctly from that of the cortex. Slight pyelectasia was noted. Occasional cortical cyst was noted. The left kidney measured 3.7 cm. The right kidney measured 3.23 cm.

### Adrenal Glands

Both **adrenal glands** were visualized and recognized as having normal shape, size, position and echogenicity for this breed. The phrenic vasculature, glandular echogenicity and detail were unremarkable. Capsule, cortex, and medullary definition were normal for this age patient. The left adrenal gland measured 0.47 cm at the caudal pole and 0.51 cm at the cranial pole. The right adrenal gland measured 0.51 cm at the cranial pole and 0.4 cm at the caudal pole.

### Spleen

The **spleen** presented a smooth homogeneous parenchyma hyperechoic to liver and renal cortical parenchyma. The capsule was smooth without noticeable expansion or deviation from within the spleen or adjacent pathology. The splenic vasculature demonstrated normal volume without signs of congestion or thrombosis. No sonographic evidence of acute or chronic inflammatory, neoplastic, or infarctual changes was noted.

### Liver

The **liver** images submitted revealed subjectively normal liver size, contour, and structure. Parenchymal echogenicity was naturally coarse and hypoechoic to the spleen. Vascular and biliary tracts were of normal volume with no evidence of congestion. The gallbladder presented acceptably thin walls with primarily anechoic content. The cystic and common bile ducts were normal. No pathological hepatic



**PATIENT**

lymphadenopathy was evident. No overt structural evidence of inflammatory, infiltrative or regenerative pathology was evident.

Melo Tripodi

**SPECIES**

**Gastrointestinal**

Canine

There was some residual chyme and gas was noted in the **stomach**, yet not pathological. This is consistent with post prandial presentation. Transit of chyme into the small intestine was normal. Curvilinear patterns were maintained throughout the GI tract. No evidence of pathology. Small and large intestine demonstrated normal luminal chyme and stool consistency respectively. No obstructive or overt infiltrative disease was noted. No associated abnormal lymphatic activity was noted.

**BREED**

Shih Tzu

**SEX**

Neutered male

**Pancreas**

**AGE**

The base and limbs of the **pancreas** were observed to be largely isoechoic to surrounding omental fat. Pancreatic duct and capsular contour were acceptably normal and parenchyma respected normal curvilinear patterns. No overt evidence of active inflammatory or neoplastic disease was noted.

7 years

**WEIGHT**

12.5 lbs

**ULTRASONOGRAPHIC FINDINGS**

**INTERPRETED BY**

Non-specific degenerative renal changes with corticomedullary band.

Eric Lindquist, DMV  
DABVP, Cert. IVUSS

**INTERPRETATION OF THE FINDINGS & FURTHER RECOMMENDATIONS**

**IMAGING PERFORMED BY**

I cannot rule out a mild form of primary renal dysplasia. Blood pressure measurements and urine culture are warranted if any inflammatory sediment is found. 72-hour IV fluid protocol is recommended with reassessment of the clinical status. The prognosis is guarded long term.

Dr. Salas

**HOSPITAL NAME**

Tenafly VC

**REFERRING VET**

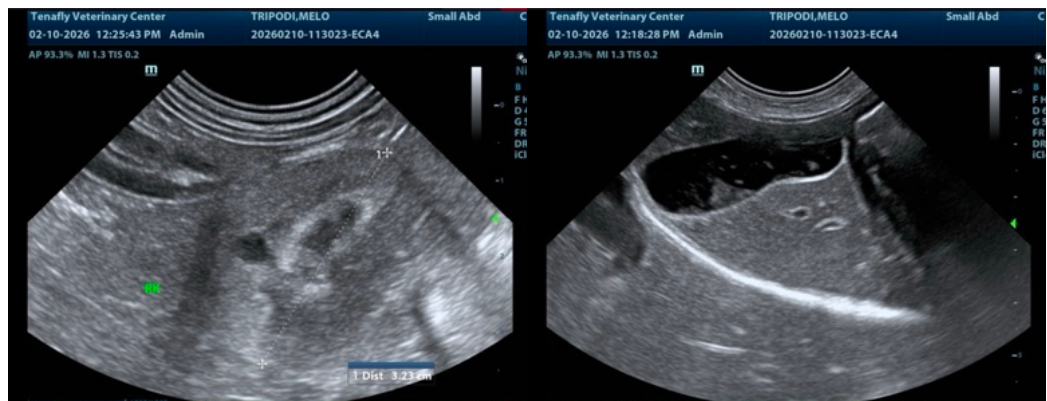
Dr. Salas

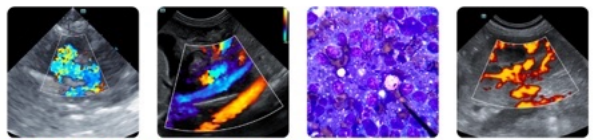
**INVOICE**

71517

**DATE**

2/11/26





**PATIENT**

Melo Tripodi

**SPECIES**

Canine

**BREED**

Shih Tzu

**SEX**

Neutered male

**AGE**

7 years

**WEIGHT**

12.5 lbs

**INTERPRETED BY**

Eric Lindquist, DMV  
DABVP, Cert. IVUSS

**IMAGING PERFORMED BY**

Dr. Salas

**HOSPITAL NAME**

Tenaflly VC

**REFERRING VET**

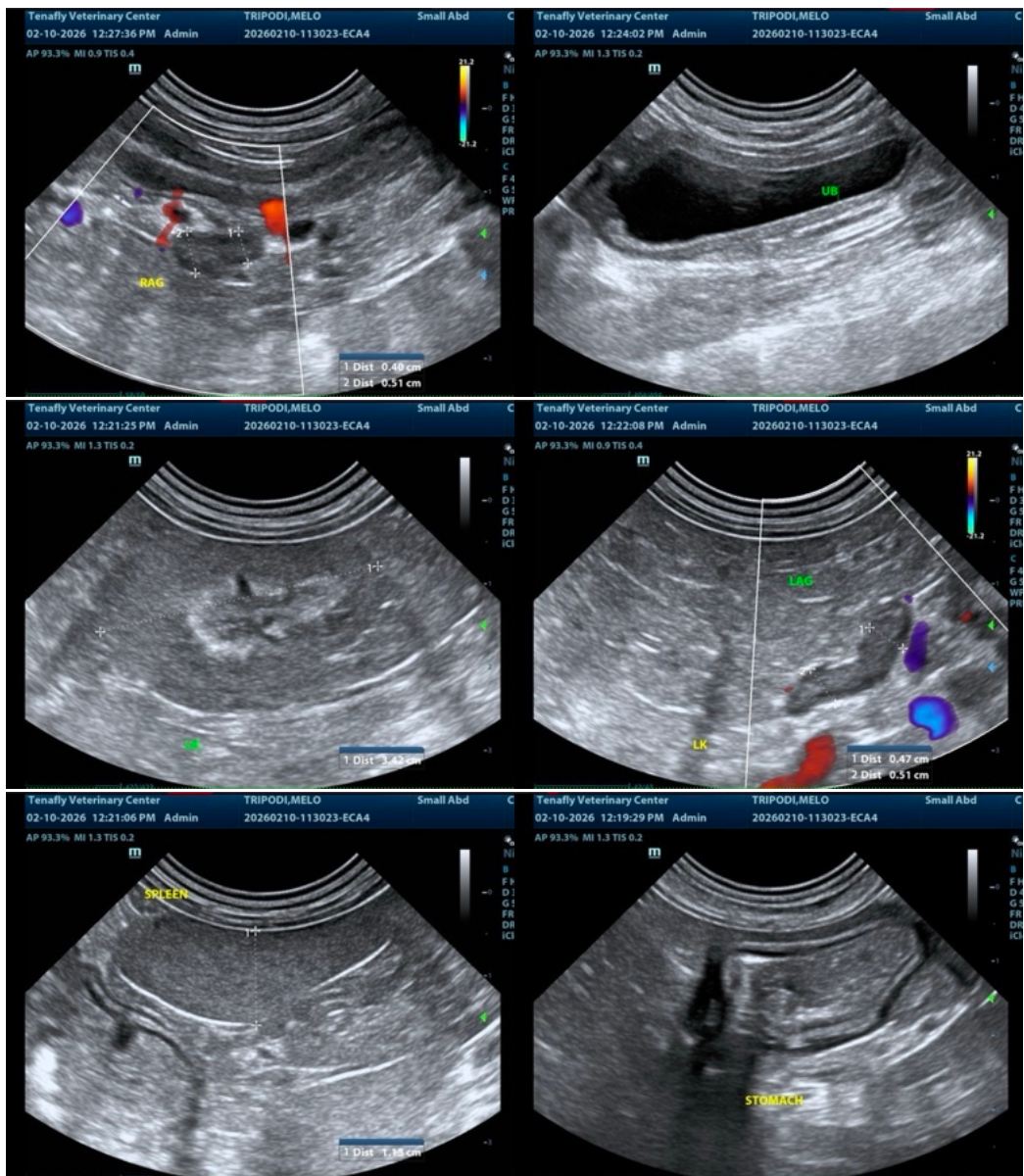
Dr. Salas

**INVOICE**

71517

**DATE**

2/11/26



The information and recommendations provided are based on the images presented by the referring veterinarian/sonographer. No evaluation can be communicated regarding pathology that was not visible in the image/video clips provided.

Thank you for this referral. If the clinical or image interpretation does not parallel your findings or if I can be of any further assistance please contact me.

Eric Lindquist, DMV, DABVP (CFM), Cert. IVUSS, CEO of SonoPath.com

[info@SonoPath.com](mailto:info@SonoPath.com)