



PATIENT

Gregory McCabe

SPECIES

Canine

BREED

Terrier Mix

SEX

Neutered Male

AGE

9

WEIGHT

17.6

INTERPRETED BY

Eric Lindquist, DMV,
DABVP(CFM), Cert.
IVUSS

IMAGING PERFORMED BY

Jenn

HOSPITAL NAME

Rockaway Animal
Hospital

REFERRING VET

Dr. Maniar

INVOICE

13701

DATE

02/11/26

PRESENTING CLINICAL SIGNS

- distended abd, seems nauseous

ULTRASONOGRAPHIC EXAMINATION OF THE ABDOMEN

Urinary System

The **urinary bladder**, trigone, and pelvic urethra to a depth of 2.0 cm presented normal thicknesses and normal tone. The ureters were not visible which is normal. No uroliths or sediment were visualized, and anechoic urine was present. No evidence of inflammatory or neoplastic changes were noted. Ureteral papillae were normal.

The residual **prostate** measured 0.84 cm.

The **kidneys** revealed largely normal size and structure, corticomedullary definition and ratio (cortex 1/3 of medulla) were essentially maintained with some mild age-related loss of curvilinear patterns regarding the capsule and C/M junction. The cortices presented largely uniform texture with some increased echogenicity expected for his age patient. Medullary structure differed distinctly from that of the cortex and no evidence of pelvic dilation was present. The left kidney measured 3.75 cm in length. The right kidney measured 3.42 cm in length.

Adrenal Glands

The **left adrenal gland** was visualized and recognized as having normal shape, size, position and echogenicity for this breed. The phrenic vasculature, glandular echogenicity and detail were unremarkable. Capsule, cortex, and medullary definition were normal for this age patient. The left adrenal gland measured 1.4 cm x 0.58 cm width at the caudal pole and 0.65 cm width at the cranial pole.

The **right adrenal gland** revealed a hyperechoic nodule measuring 1.1 cm x 0.80 cm and is most consistent with adenoma, however, emerging carcinoma, pheochromocytoma or adrenal tumor is possible. The right adrenal gland measured 2.03 cm x 1.23 cm width at the cranial pole and 0.76 cm width at the caudal pole.

Spleen

The **spleen** presented a smooth homogeneous parenchyma hyperechoic to liver and renal cortical parenchyma. The capsule was smooth without noticeable expansion or deviation from within the spleen or adjacent pathology. The splenic vasculature demonstrated normal volume without signs of congestion or thrombosis. No sonographic evidence of acute or chronic inflammatory, neoplastic, or infarctual changes were noted.

Liver

The **liver** images from right and left intercostal as well as subcostal views revealed subjectively normal liver size, contour, and structure. Some mild age-related parenchymal remodeling was noted but likely not clinically significant at this time. Vascular and biliary tracts were of normal volume and no evidence of congestion was noted. The gallbladder presented some dependent debris with essentially normal contour. The cystic and common bile ducts were normal. No overt evidence of active inflammatory, infiltrative or regenerative pathology was noted but should be paired with current or past LE



PATIENT

Gregory McCabe

SPECIES

Canine

BREED

Terrier Mix

SEX

Neutered Male

AGE

9

WEIGHT

17.6

INTERPRETED BY

Eric Lindquist, DMV,
DABVP(CFM), Cert.
IVUSS

IMAGING PERFORMED BY

Jenn

HOSPITAL NAME

Rockaway Animal
Hospital

REFERRING VET

Dr. Maniar

INVOICE

13701

DATE

02/11/26

elevations regarding any clinical significance to this presentation. The hepatic lymph nodes were unremarkable.

Gastrointestinal

There was some residual chyme and gas noted in the **stomach**, yet not pathological. This is consistent with end post prandial presentation. Transit of chyme into the small intestine was normal. Curvilinear patterns were maintained throughout the GI tract. No evidence of pathology. Small and large intestine demonstrated normal luminal chyme and stool consistency respectively. No obstructive or overt infiltrative disease was noted. No associated abnormal lymphatic activity was noted.

Pancreas

The base and limbs of the **pancreas** were observed to be largely isoechoic to surrounding omental fat. Pancreatic duct and capsular contour were acceptably normal and parenchyma respected normal curvilinear patterns. No overt evidence of active inflammatory or neoplastic disease was noted.

ULTRASONOGRAPHIC FINDINGS

- Right adrenal nodule- should be monitored.
- Unremarkable age-related abdominal changes otherwise.

INTERPRETATION OF THE FINDINGS & FURTHER RECOMMENDATIONS

Serial blood pressure measurements are recommended in this patient. If hypertension is an issue metanephrine level is recommended. If the patient appears Cushingoid and urine specific gravity is less than 1.020 then work-up for adrenal dependent Cushing's is indicated. Recheck is recommended in 2-3 weeks to assess for any progression of the adrenal gland.



PATIENT

Gregory McCabe

SPECIES

Canine

BREED

Terrier Mix

SEX

Neutered Male

AGE

9

WEIGHT

17.6

INTERPRETED BY

Eric Lindquist, DMV,
DABVP(CFM), Cert.
IVUSS

IMAGING PERFORMED BY

Jenn

HOSPITAL NAME

Rockaway Animal
Hospital

REFERRING VET

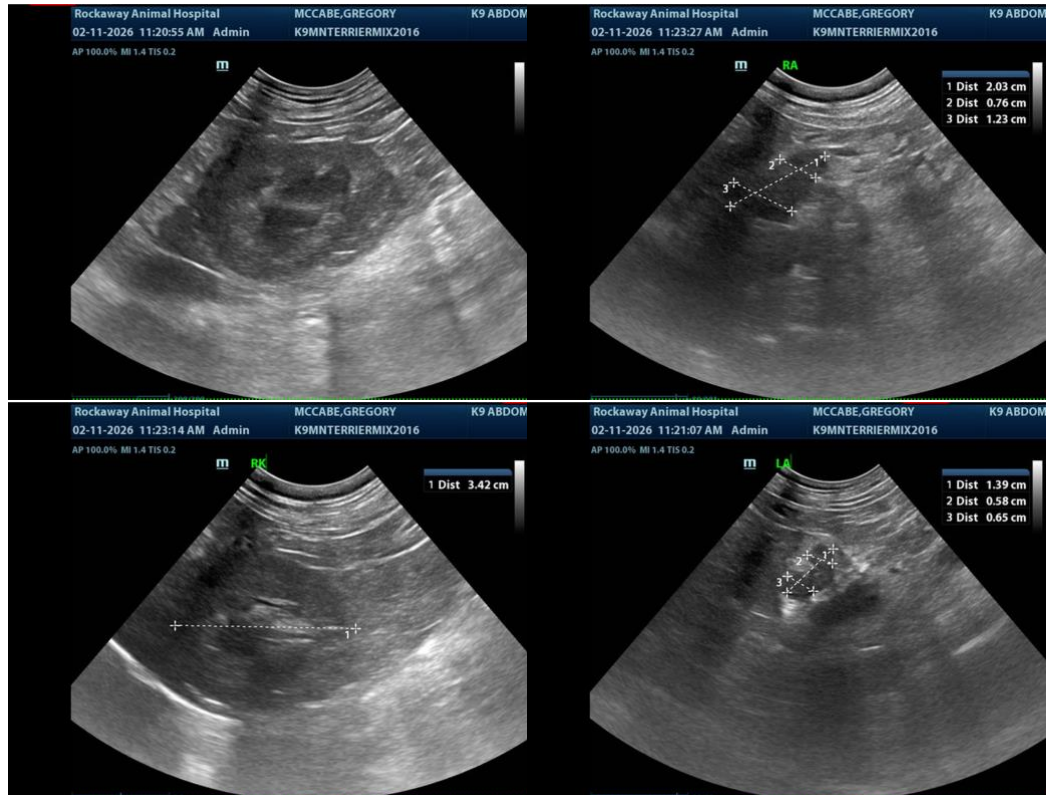
Dr. Maniar

INVOICE

13701

DATE

02/11/26





PATIENT

Gregory McCabe

SPECIES

Canine

BREED

Terrier Mix

SEX

Neutered Male

AGE

9

WEIGHT

17.6

INTERPRETED BY

Eric Lindquist, DMV,
DABVP(CFM), Cert.
IVUSS

IMAGING PERFORMED BY

Jenn

HOSPITAL NAME

Rockaway Animal
Hospital

REFERRING VET

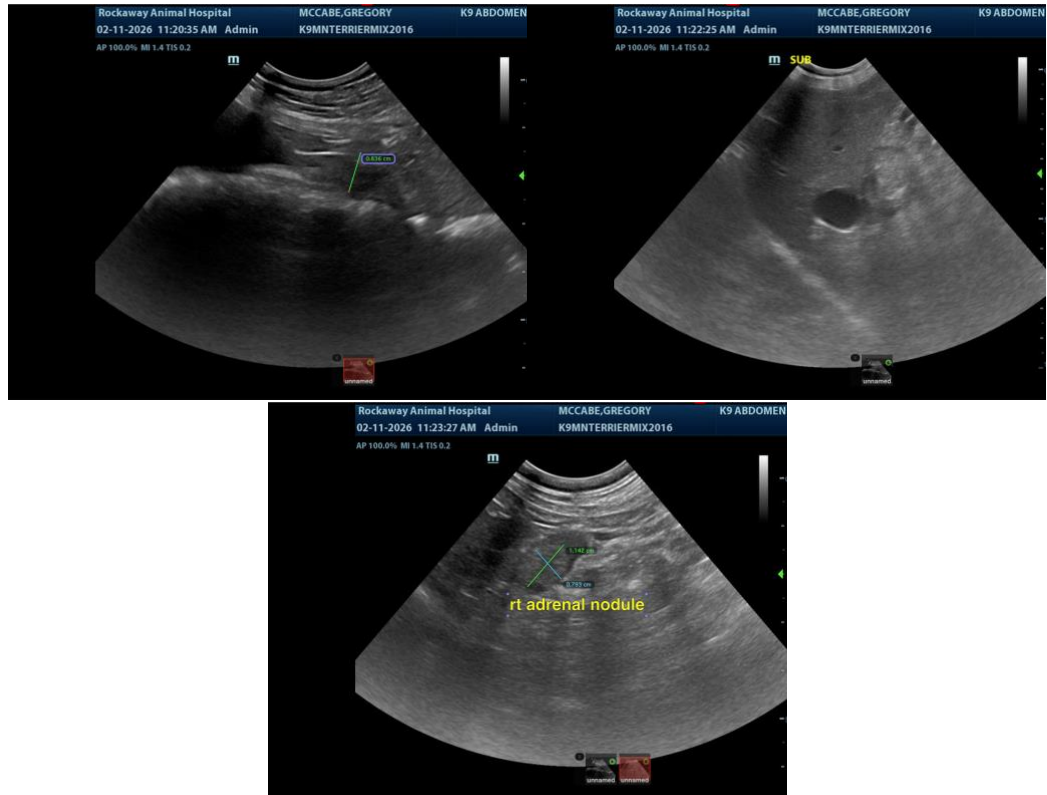
Dr. Maniar

INVOICE

13701

DATE

02/11/26



The information and recommendations provided are based on the images presented by the referring veterinarian/sonographer. No evaluation can be communicated regarding pathology that was not visible in the image/video clips provided.

Thank you for this referral. If the clinical or image interpretation does not parallel your findings or if I can be of any further assistance, please contact me.

Eric Lindquist, DMV, DABVP(CFM), Cert. IVUSS,

CEO, Owner, Founder -- SonoPath.com

info@SonoPath.com