

PATIENT

Sebastian Andrews

PRESENTING CLINICAL SIGNS

Decreased appetite x5 days. Progressive lethargy. Drooling, panting.

SPECIES

Canine

ULTRASONOGRAPHIC EXAMINATION OF THE ABDOMEN

Urinary System

The **urinary bladder**, trigone, and pelvic urethra presented normal thicknesses and normal tone. The ureters were not visible which is normal. No uroliths or sediment were visualized and anechoic urine was present. No evidence of inflammatory or neoplastic changes were noted. Ureteral papillae were normal. The urethra was normal to a depth of 1.0 cm.

BREED

French Bulldog

The **kidneys** revealed normal size and structure, corticomedullary definition and ratio for this age. The cortices presented largely uniform texture with normal echogenic relationship to liver and spleen. Medullary structure differed distinctly from the cortex and no evidence of pelvic dilation was present. The capsules were acceptably uniform without significant irregularities.

SEX

Neutered Male

Adrenal Glands

Both **adrenal glands** were visualized and recognized as having normal shape, size, position and echogenicity for this breed. The phrenic vasculature, glandular echogenicity and detail were unremarkable. Capsule, cortex, and medullary definition were normal for this age patient.

AGE

2 Years

Spleen

The **spleen** presented a smooth homogeneous parenchyma hyperechoic to liver and renal cortical parenchyma. The capsule was smooth without noticeable expansion or deviation from within the spleen or adjacent pathology. The splenic vasculature demonstrated normal volume without signs of congestion or thrombosis. No sonographic evidence of acute or chronic inflammatory, neoplastic, or infarctual changes were noted.

WEIGHT

41.7 Pounds

INTERPRETED BY

Eric Lindquist, DMV

DABVP, Cert. IVUSS

Liver

The **liver** images submitted revealed subjectively normal liver size, contour, and structure. Parenchymal echogenicity was naturally coarse and hypoechoic to the spleen. Vascular and biliary tracts were of normal volume with no evidence of congestion. The gallbladder presented acceptably thin walls with primarily anechoic content. The cystic and common bile ducts were normal. No pathological hepatic lymphadenopathy was evident. No overt structural evidence of inflammatory, infiltrative or regenerative pathology was evident.

IMAGING PERFORMED BY

Eric Lindquist, DMV

DABVP, Cert. IVUSS

Gastrointestinal

The **stomach** was filled with ingesta, consistent with post-prandial presentation. No overt evidence of foreign matter noted. Some minor shadowing present, most consistent with kibble and soft food. Transit of chyme into the small intestine noted. No overt obstruction. Delayed outflow may be an issue.

HOSPITAL NAME

Franklin Lakes AH

REFERRING VET

Dr. Onesios

Pancreas

The base and limbs of the **pancreas** were observed to be largely isoechoic to surrounding omental fat. Pancreatic duct and capsular contour were acceptably normal and parenchyma respected normal curvilinear patterns. No overt evidence of active inflammatory or neoplastic disease was noted.

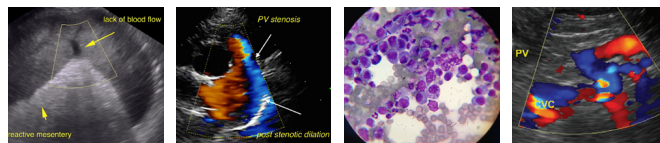
INVOICE

35610

ULTRASONOGRAPHIC FINDINGS

- Unremarkable abdomen with full stomach

DATE



PATIENT

Sebastian Andrews

INTERPRETATION OF THE FINDINGS & FURTHER RECOMMENDATIONS

Post-prandial presentation or possible delayed outflow, likely ingesta.

SPECIES

Canine

BREED

French Bulldog

SEX

Neutered Male

AGE

2 Years

WEIGHT

41.7 Pounds

INTERPRETED BY

Eric Lindquist, DMV

DABVP, Cert. IVUSS

IMAGING PERFORMED BY

Eric Lindquist, DMV

DABVP, Cert. IVUSS

HOSPITAL NAME

Franklin Lakes AH

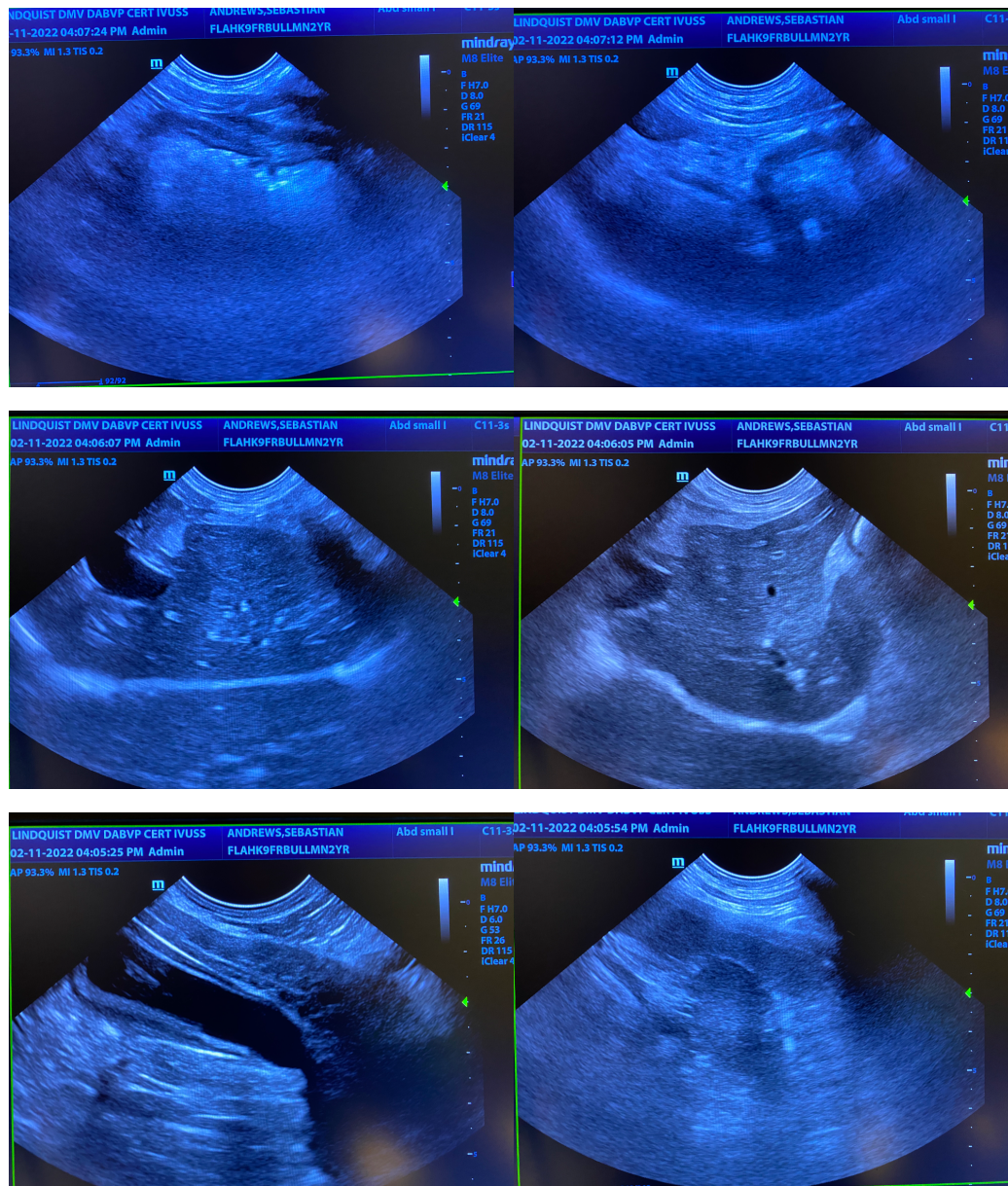
REFERRING VET

Dr. Onesios

INVOICE

35610

DATE



The information and recommendations provided are based on the images presented by the referring veterinarian/sonographer. No evaluation can be communicated regarding pathology that was not visible in the image/video clips provided.

Thank you for this referral. If the clinical or image interpretation does not parallel your findings or if I can be of any further assistance please contact me.

Eric Lindquist, DMV, DABVP, Cert. IVUSS, CEO of SonoPath.com

info@SonoPath.com