



PATIENT

Julius Price

SPECIES

Feline

BREED

DSH

SEX

Neutered Male

AGE

7.5 Years

WEIGHT

8.8 Lbs.

INTERPRETED BY

Eric Lindquist, DMV
DABVP, Cert. IVUSS

IMAGING PERFORMED BY

Judy Schroeder

HOSPITAL NAME

Animal Health
Associates

REFERRING VET

Judy Schroeder

INVOICE

13882

DATE

2/11/22

PRESENTING CLINICAL SIGNS

History: Anemia, enlarged kidneys, FUO. Seen on Monday for inappetence, weight loss, high fever. BW at that time showed markedly elevated WBC, non-regenerative anemia. Chemistries wnl except for mild increase globulins. Started on broad spectrum antibiotics but no response after 72 hours. Repeat blood tests after 72 hours show continued non regenerative anemia, mild hyperglycemia.

Abnormal PE/Chem/CBC/UA Results: Fever 105, non-responsive to broad spectrum abx. Anemia hematocrit 20%, non-regenerative over 4 days, microcytic. Reticulocytes are low. Platelet clumping. Large neutrophilic leukocytosis 43K/ul with bands/toxic changes. Mild increase in monocytes. BUN, creatinine, ALT, ALP, albumin normal. Globulins mildly elevated. Large proteinuria with casts, 3-5 WBCs/hpf, epithelial cells, culture pending.

ULTRASONOGRAPHIC EXAMINATION OF THE ABDOMEN

Urinary System

The **urinary bladder**, trigone, and pelvic urethra presented normal thicknesses and normal tone. The ureters were not visible which is normal. No uroliths or sediment were visualized and anechoic urine was present. No evidence of inflammatory or neoplastic changes were noted. Ureteral papillae were normal.

Cortical irregularity noted at the cranial pole of the **left kidney** with some loss of early mural detail. Concern for infarct versus early infiltrative event. The left kidney measured 4.35 cm.

The **right kidney**, in particular, was enlarged and irregular with early subcapsular halo noted. The right kidney measured 5.3 cm.

Adrenal Glands

Both **adrenal glands** were visualized and recognized as having normal shape, size, position and echogenicity for this breed. The phrenic vasculature, glandular echogenicity and detail were unremarkable. Capsule, cortex, and medullary definition were normal for this age patient. The left adrenal gland measured 0.53 cm. The right adrenal gland measured 0.58 cm.

Spleen

The **spleen** revealed subtle micronodular changes with slight scalloping contour. Splenitis, reactive spleen versus round cell neoplasia.

Liver

The **liver** was enlarged with mild heterogeneous parenchymal changes. Enhanced mesentery was present.

Gastrointestinal

Examination of the **gastrointestinal tract** revealed a stomach and intestine free of stasis, of normal wall thickness, acceptable curvilinear mural detail, and peristaltic activity. Small and large intestine demonstrated normal luminal chyme and stool consistency respectively. No obstructive or overt infiltrative disease was noted. No associated abnormal lymphatic activity was noted.

Pancreas



PATIENT

Julius Price

The **pancreas** was prominent and hypoechoic with mild undulating contour, possible minor pancreatitis.

SPECIES

Feline

ULTRASONOGRAPHIC FINDINGS

- Enlarged kidneys, particularly the right kidney
- Micronodular spleen
- Swollen liver

BREED

DSH

INTERPRETATION OF THE FINDINGS & FURTHER RECOMMENDATIONS

SEX

Neutered Male

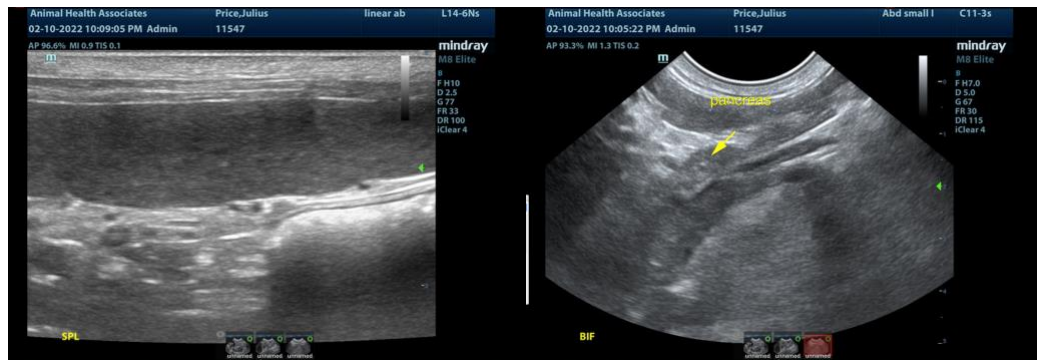
Strong concern for emerging round cell neoplasia. 25-gauge FNA of the spleen, right kidney and liver all indicated in this patient to assess for underlying neoplasia. CBC path review +/- bone marrow aspirate indicated. Prognosis is guarded depending upon cytology results.

AGE

7.5 Years

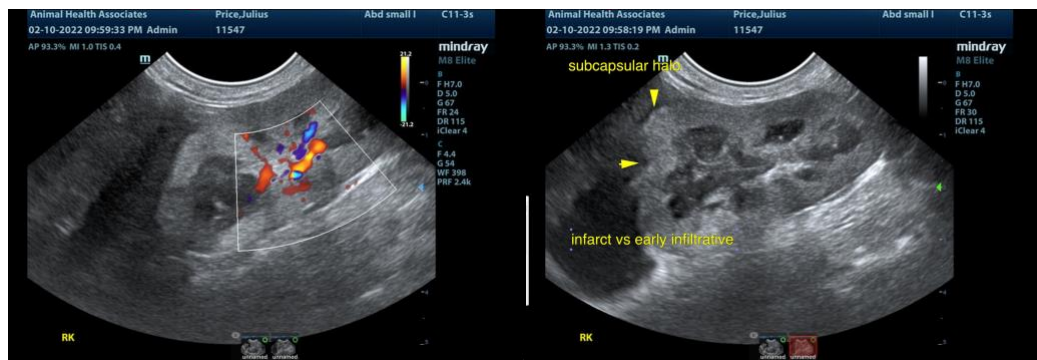
WEIGHT

8.8 Lbs.



INTERPRETED BY

Eric Lindquist, DMV
DABVP, Cert. IVUSS

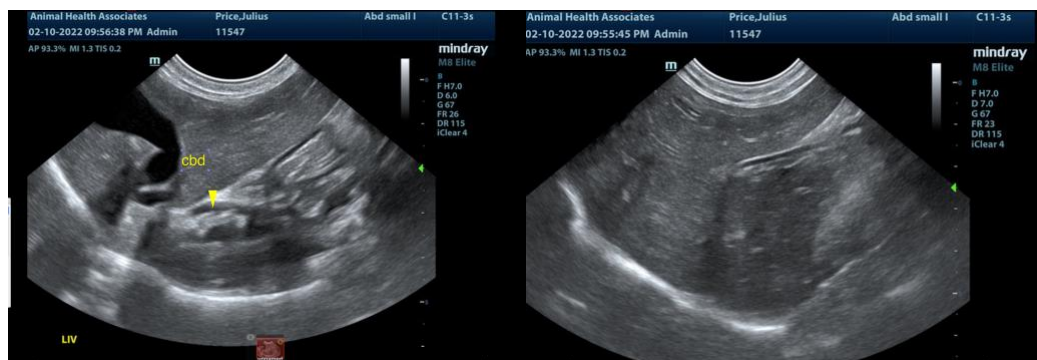


IMAGING PERFORMED BY

Judy Schroeder

HOSPITAL NAME

Animal Health Associates



REFERRING VET

Judy Schroeder

INVOICE

13882

DATE

2/11/22



PATIENT

Julius Price

SPECIES

Feline

BREED

DSH

SEX

Neutered Male

AGE

7.5 Years

WEIGHT

8.8 Lbs.

INTERPRETED BY

Eric Lindquist, DMV
DABVP, Cert. IVUSS

IMAGING PERFORMED BY

Judy Schroeder

HOSPITAL NAME

Animal Health
Associates

REFERRING VET

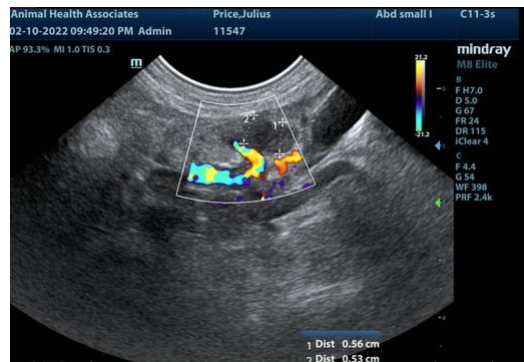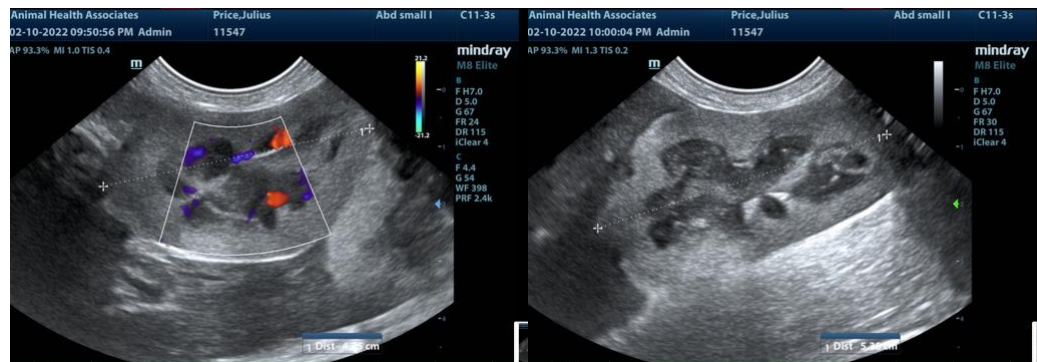
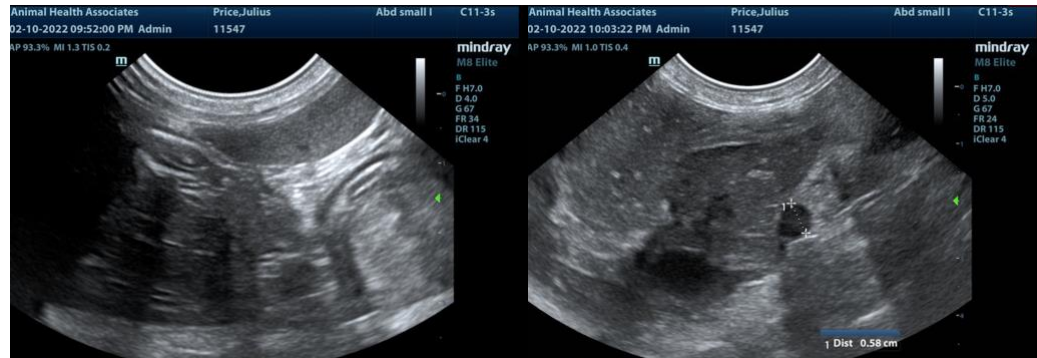
Judy Schroeder

INVOICE

13882

DATE

2/11/22



The information and recommendations provided are based on the images presented by the referring veterinarian. No evaluation can be communicated regarding pathology that was not visible in the image/video clips provided.

Thank you for this referral. If the clinical or image interpretation does not parallel your findings or if I can be of any further assistance please contact me.

Eric Lindquist, DMV, DABVP, Cert. IVUSS, CEO of SonoPath.com
info@SonoPath.com

Fever of Unknown Origin

<http://www.sonopath.com/FUO>



PATIENT

Julius Price

SPECIES

Feline

BREED

DSH

SEX

Neutered Male

AGE

7.5 Years

WEIGHT

8.8 Lbs.

INTERPRETED BY

Eric Lindquist, DMV
DABVP, Cert. IVUSS

IMAGING PERFORMED BY

Judy Schroeder

HOSPITAL NAME

Animal Health
Associates

REFERRING VET

Judy Schroeder

INVOICE

13882

DATE

2/11/22

Description: The definition of a fever of unknown origin (FUO) has not been clearly defined for animals. Currently, it is either understood to be a fever that does not resolve within the period one would expect for a “self-limiting infection” being treated with appropriate antimicrobial therapy, or that for which an underlying diagnosis has not been determined despite considerable diagnostic effort. The common causes of FUO were summarized concisely in a presentation at the American College of Veterinary Internal Medicine 2004 Forum. The presenters synthesized information from three veterinary papers on the subject, which suggested the following:

	Final Diagnosis	Bennett (dogs & cats)	Dunn and Dunn (dogs only)	Lunn (dogs & one cat)	Total
	Infection	21	16	10	47
	Immune	18	22	6	46
	Bone marrow disease	4	22	2	28
	Neoplasia (outside marrow)	0	10	2	12
	Miscellaneous	2	12	2	16
	No diagnosis	0	19	2	21
	TOTALS	45	101	24	170

The types of infection diagnosed in this case series were varied, ranging from discospondylitis (8 cases), blastomycosis (6), and bacterial endocarditis (4), to leishmaniasis (1), prostatitis (1), and *Ehrlichia canis* infection (1); a multitude of other infectious causes also fell within the spectrum. Of the cases in which immune-mediated disease was found, 44% had immune-mediated polyarthritis. Bone marrow diseases included myeloproliferative disease, myelodysplasia (8), lymphocytic leukemia (8), myeloma (3), chronic granulocytic leukemia (3), lymphoblastic leukemia, and malignant histiocytosis. The types of neoplasia located outside the bone marrow included lymphoma (6), metastatic disease (2), and neoplasms of the lung, spleen, and stomach. Finally, miscellaneous diseases included hypertrophic osteodystrophy (6), meningitis (3), portosystemic shunt (3), lymphadenitis (2), panosteitis, and intervertebral disc disease. Overall, the most common causes across all cases were polyarthritis (44), lymphoid neoplasia (15), discospondylitis (8), myelodysplasia (8), hypertrophic osteodystrophy (6), and blastomycosis (6).

Clinical Signs: Animals usually present with either persistent or waxing and waning fevers ranging from 103°F to 106°F. Other clinical signs depend on the underlying cause of the fever. Careful and thorough physical examination is required to assess potential causes.



PATIENT

Julius Price

SPECIES

Feline

BREED

DSH

SEX

Neutered Male

AGE

7.5 Years

WEIGHT

8.8 Lbs.

INTERPRETED BY

Eric Lindquist, DMV
DABVP, Cert. IVUSS

IMAGING PERFORMED BY

Judy Schroeder

HOSPITAL NAME

Animal Health
Associates

REFERRING VET

Judy Schroeder

INVOICE

13882

DATE

2/11/22

Diagnosics: FUE etiologies are partly related to geography, and thus locale or travel history should factor into a practitioner's diagnostic approach. A patient's lifestyle may also provide clues regarding exposure to certain etiologic agents. Therefore, conducting a thorough history can unveil important pieces of the diagnostic puzzle. Physical examination is especially important and should include an inspection of all accessible lymph nodes, palpation and movement of the joints, a fundic examination, a neurological evaluation, spinal and limb palpation and range of motion tests, and a rectal examination.

A minimum database should include a CBC reviewed by a clinical pathologist, as well as a biochemical profile and urinalysis. Retroviral testing should also be considered in cats. In areas where tick-borne disease is prevalent, in-house testing should be performed early. Advanced laboratory work can include: urine culture, blood culture, and infectious disease panels (PCR and/or serology). In dogs, one may screen for the following infectious agents: *Ehrlichia* spp., *Borrelia burgdorferi*, Rock Mountain Spotted Fever, *Bartonella* spp. (culture and PCR), and *Leptospira* spp. in cases of hepatic or renal involvement. In cats, one should evaluate for FeLV, FIV, feline infectious peritonitis (FIP) virus, toxoplasmosis, *Hemoplasma* spp. (*Mycoplasma*), and *Bartonella* spp. (culture and PCR). Testing for *Ehrlichia* spp., *Rickettsia* spp., and *Anaplasma phagocytophilum* can also be considered. A fungal assay is indicated if the patient lives in or has had exposure to a region with a higher incidence of fungal disease. Other infectious disease tests may be performed depending on the geographical location of the pet. Screening for *Brucella* should be done in breeding dogs. Immune-mediated disease screening can include a Coomb's test, a slide agglutination test (if the patient is anemic), and an antinuclear antibody (ANA) test. Immune disease is often a diagnosis of exclusion.

Imaging should include thoracic radiographs, abdominal ultrasound, and/or abdominal radiographs. Ultrasound can be very useful for assessing evidence of cholangiohepatitis, pyelonephritis, chronic urinary tract infection, abscess formation, peritonitis, and neoplasia; it also permits an examination of the intra-abdominal lymph nodes. An echocardiogram can offer assessment for vegetative endocarditis, whereas spinal radiographs offer assessment for discospondylitis. In cases where all other testing has proven negative and the patient has not responded to broad-spectrum antibiotics and supportive care, arthrocentesis should be considered to evaluate for septic joint disease, immune-mediated polyarthritis, and infectious disease. Finally, one can consider assessing the cerebrospinal fluid for meningoencephalitis, GME, and meningitis/arteritis. A bone marrow exam should be performed if blood dyscrasias are noted on the CBC.

Treatment: Treatment of the fever depends entirely on the underlying cause. Ideally, a thorough diagnostic plan will yield a diagnosis that will guide the appropriate therapeutic course. However, if an exhaustive approach has not produced a definitive diagnosis and there is no response to broad-spectrum antibiotics, trial therapy with immunosuppressive agents such as prednisolone can be considered to treat presumed immune-mediated diseases. Given the potential for negative sequelae should an underlying infection be present, one must be certain that the investigation is thorough and monitor the patient's response carefully.

Conclusion: If a documented fever has not responded to antibiotics, antipyretics, or general nursing care, it is important to obtain a diagnosis to guide more specific treatment. A systematic physical



PATIENT

Julius Price

examination and thorough history-taking will help inform further diagnostics in addition to what is revealed by the minimum database.

SPECIES

Feline

References:

Bennet D. Diagnosis of pyrexia of unknown origin. *In Practice* 1995;17(10):470-81.

Dunn KJ, Dunn JK. Diagnostic investigations in 101 dogs with pyrexia of unknown origin. *J Sm Anim Pract* 1998;39(12):574-80.

BREED

DSH

Flood J. The diagnostic approach to fever of unknown origin in cats. *Compend Contin Educ Vet* 2009;31(1):26-31.

SEX

Neutered Male

Flood J. The diagnostic approach to fever of unknown origin in dogs. *Compend Contin Educ Vet* 2009;31(1):14-21.

AGE

7.5 Years

Lappin MR. The role of blood borne pathogens in feline fever of unknown origin. Proceedings from the American College of Veterinary Internal Medicine, Denver, CO, June 15-18, 2011.

WEIGHT

8.8 Lbs.

Lunn KF. Fever of unknown origin: a systematic approach to diagnosis. *Compend Contin Educ Vet* 2001;23(11):976-92.

Lunn KF. Fever of unknown origin: appropriate choice of diagnostic tests. Proceedings from the American College of Veterinary Internal Medicine, Minneapolis, MN, June 9-12, 2004.

INTERPRETED BY

Eric Lindquist, DMV
DABVP, Cert. IVUSS

IMAGING PERFORMED BY

Judy Schroeder

HOSPITAL NAME

Animal Health
Associates

REFERRING VET

Judy Schroeder

INVOICE

13882

DATE

2/11/22