



## PATIENT

Tuck Eisenman

## SPECIES

Canine

## BREED

Jack Russell Terrier  
Mix

## SEX

Neutered male

## AGE

8 years

## WEIGHT

47.8 lbs

## INTERPRETED BY

Eric Lindquist, DMV  
DABVP, Cert. IVUSS

## IMAGING PERFORMED BY

Ashley Whitesell

## HOSPITAL NAME

Dickson AC

## REFERRING VET

Dr. Huneycutt

## INVOICE

71465

## DATE

2/10/26

## PRESENTING CLINICAL SIGNS

- hx of AGASACA, routine recheck scan since being off Palladia medication.
- New heart murmur noted during recheck exam on 2/4/26
- Exam note from 2/4/26 - CVR: grade 1-2 left systolic murmur, normal rate/rhythm; normal BV sounds bilaterally Blood Pressure Measurement 2/10/26 Cuff Size 4 Location left forelimb, right lateral recumbency Systolic 156 mmHg Diastolic 110 mmHg MAP 127 mmHg HR 97 bpm

## ULTRASONOGRAPHIC EXAMINATION OF THE ABDOMEN

### Urinary System

The **urinary bladder**, trigone, and pelvic urethra presented normal thicknesses and normal tone. The ureters were not visible which is normal. Calculi were noted in the bladder. Grouping of which measured 1.5 cm. . No evidence of inflammatory or neoplastic changes was noted. Ureteral papillae were normal.

The **kidneys** revealed largely normal size and structure, corticomedullary definition and ratio (cortex 1/3 of medulla) were essentially maintained with some age-related loss of curvilinear patterns regarding the capsule and C/M junction. The cortices presented largely uniform texture with some increased echogenicity expected for this age patient. Medullary structure differed distinctly from that of the cortex and no evidence of pelvic dilation was present. The right kidney measured 6.77 cm. The left kidney measured 6.37 cm.

The residual prostate measured 1.0 cm. The pre and post prostatic urethra was unremarkable.

### Adrenal Glands

Both **adrenal glands** were visualized and recognized as having normal shape, size, position and echogenicity for this breed. The phrenic vasculature, glandular echogenicity and detail were unremarkable. Capsule, cortex, and medullary definition were normal for this age patient. The right adrenal gland measured 0.75 cm. The left adrenal gland measured 0.82 cm at the cranial pole and 0.62 cm at the caudal pole.

### Spleen

The **spleen** presented a smooth homogeneous parenchyma hyperechoic to liver and renal cortical parenchyma. The capsule was smooth without noticeable expansion or deviation from within the spleen or adjacent pathology. The splenic vasculature demonstrated normal volume without signs of congestion or thrombosis. No sonographic evidence of acute or chronic inflammatory, neoplastic, or infarctual changes was noted.

### Liver

The **liver** images from right and left intercostal as well as subcostal views revealed subjectively normal liver size, contour, and structure. Some age-related parenchymal remodeling was noted but likely not clinically significant at this time. Vascular and biliary tracts were of normal volume and no evidence of



## PATIENT

Tuck Eisenman

## SPECIES

Canine

## BREED

Jack Russell Terrier  
Mix

## SEX

Neutered male

## AGE

8 years

## WEIGHT

47.8 lbs

## INTERPRETED BY

Eric Lindquist, DMV  
DABVP, Cert. IVUSS

## IMAGING PERFORMED BY

Ashley Whitesell

## HOSPITAL NAME

Dickson AC

## REFERRING VET

Dr. Huneycutt

## INVOICE

71465

## DATE

2/10/26

congestion was noted. The gallbladder presented some dependent debris with essentially normal contour. The cystic and common bile ducts were normal. No overt evidence of active inflammatory, infiltrative or regenerative pathology was noted but should be paired with current or past LE elevations regarding any clinical significance to this presentation. The hepatic lymph nodes were unremarkable.

## Gastrointestinal

Examination of the **gastrointestinal tract** revealed a stomach and intestine free of stasis, of normal wall thickness, acceptable curvilinear mural detail, and peristaltic activity. Small and large intestine demonstrated normal luminal chyme and stool consistency respectively. No obstructive or overt infiltrative disease was noted. No associated abnormal lymphatic activity was noted.

## Pancreas

The base and limbs of the **pancreas** were observed to be largely isoechoic to surrounding omental fat. Pancreatic duct and capsular contour were acceptably normal and parenchyma respected normal curvilinear patterns. No overt evidence of active inflammatory or neoplastic disease was noted.

## ULTRASONOGRAPHIC EXAMINATION OF THE HEART

The echocardiogram in this patient demonstrated normal **left atrial** size based on 3 separate methods of LA evaluation. Trivial **mitral** valve insufficiency was noted on the mitral valve, yet not clinically significant. The **left ventricle** presented thicknesses with linear contour and was not dilated nor restricted. The **myocardium** presented normal echogenicity without subjective evidence of significant fibrotic or ischemic disease. **Contractility** of the ventricular walls was adequate and in normal range for this patient evidenced by the fractional shortening measurement and subjective evaluation of the different regions of the myocardium. The **left ventricular outflow** tract demonstrated normal laminar flow and subjective structural integrity. The **right atrium** and auricle revealed normal size, structure and content. No evidence of masses was noted. **Tricuspid** valvular assessment demonstrated adequate linear morphology and kinesis. The **right ventricle** was of normal size (1/3 diameter of LV), chordae structure, myocardial echogenicity and thickness. **Pulmonary outflow** tract assessment revealed normal valve structure, laminar flow, and diameter (approx. 1:1 pa/ao ratio). No visible **pericardial** or free pleura fluid was noted. The cranial **mediastinum and pericardial and extra-cardiac regions** were free of masses in the visible window.



**PATIENT**

Tuck Eisenman

**SPECIES**

Canine

**BREED**

Jack Russell Terrier  
Mix

**SEX**

Neutered male

**AGE**

8 years

**WEIGHT**

47.8 lbs

**INTERPRETED BY**

Eric Lindquist, DMV  
DABVP, Cert. IVUSS

**IMAGING PERFORMED BY**

Ashley Whitesell

**HOSPITAL NAME**

Dickson AC

**REFERRING VET**

Dr. Huneycutt

**INVOICE**

71465

**DATE**

2/10/26

CANINE CARDIAC PARAMETERS	MR VMAX (m/s)	TR VMAX (m/s)	LA/AO	LA/AO (Heart Base)	FS (%)	EF (%)	EPSS (cm)
NORMAL PARAMETER	4.5-5.5	<2.7	1.3	<1.6	28-40	40-100	<0.6
PATIENT	-	-	1.1	1.3	45	90	0.1
CANINE CARDIAC PARAMETERS	HR (BPM)	AV VMAX (m/s)	PV MAX (m/s)	BODY WEIGHT	LA 2D short axis Base view (cm)	LVIDd Avg; 2D and m-mode short axis (cm)	LVIDs Avg; 2D and m-mode short axis (cm)
NORMAL PARAMETER	50-100	0.7-1.7	0.7-1.6	BELOW	BELOW	BELOW	BELOW
PATIENT	-	1.9	1.4	47.8 lbs	3.3	3.5	

**ULTRASONOGRAPHIC FINDINGS**

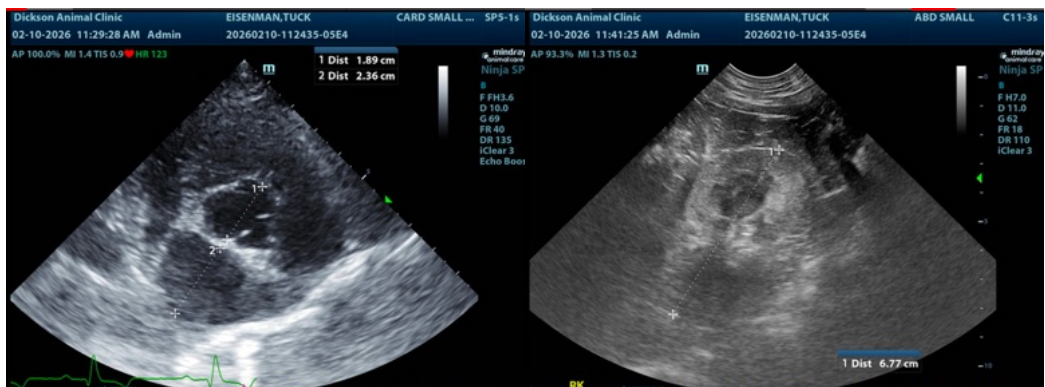
Essentially normal echocardiogram with trivial flow murmur, not clinically significant.

Bladder calculi.

Otherwise, age related abdominal changes.

**INTERPRETATION OF THE FINDINGS & FURTHER RECOMMENDATIONS**

Dissolution protocol or surgical intervention is recommended. There was no evidence of a neoplastic criteria in any organs.





**PATIENT**

Tuck Eisenman

**SPECIES**

Canine

**BREED**

Jack Russell Terrier  
Mix

**SEX**

Neutered male

**AGE**

8 years

**WEIGHT**

47.8 lbs

**INTERPRETED BY**

Eric Lindquist, DMV  
DABVP, Cert. IVUSS

**IMAGING PERFORMED BY**

Ashley Whitesell

**HOSPITAL NAME**

Dickson AC

**REFERRING VET**

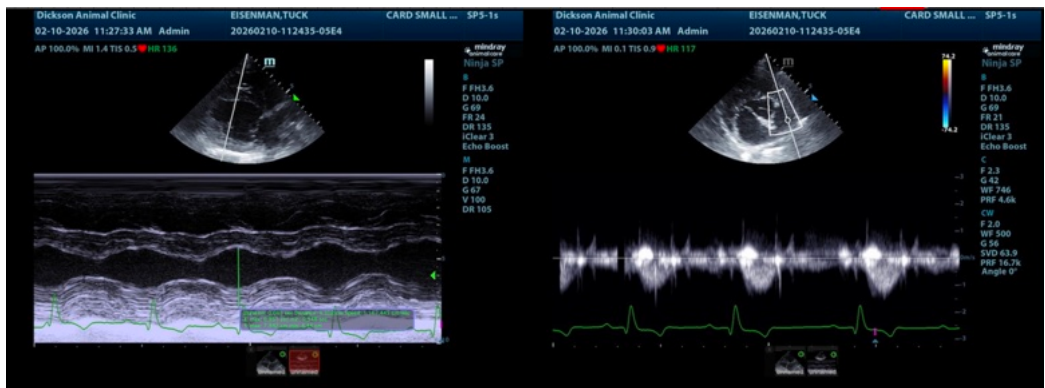
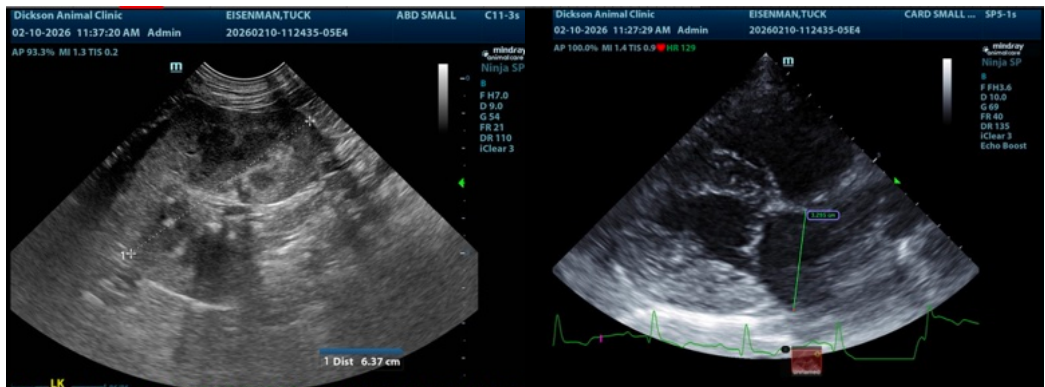
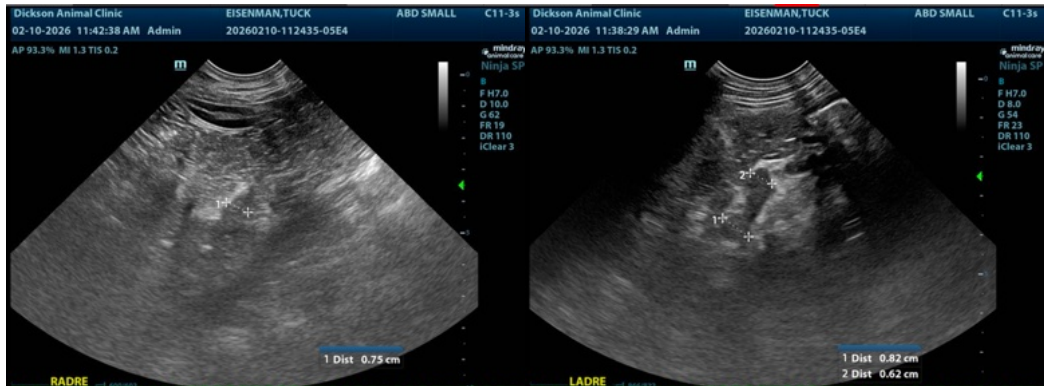Dr. Huneycutt

**INVOICE**

71465

**DATE**

2/10/26





**PATIENT**

Tuck Eisenman

**SPECIES**

Canine

**BREED**

Jack Russell Terrier  
Mix

**SEX**

Neutered male

**AGE**

8 years

**WEIGHT**

47.8 lbs

**INTERPRETED BY**

Eric Lindquist, DMV  
DABVP, Cert. IVUSS

**IMAGING  
PERFORMED BY**

Ashley Whitesell

**HOSPITAL NAME**

Dickson AC

**REFERRING VET**

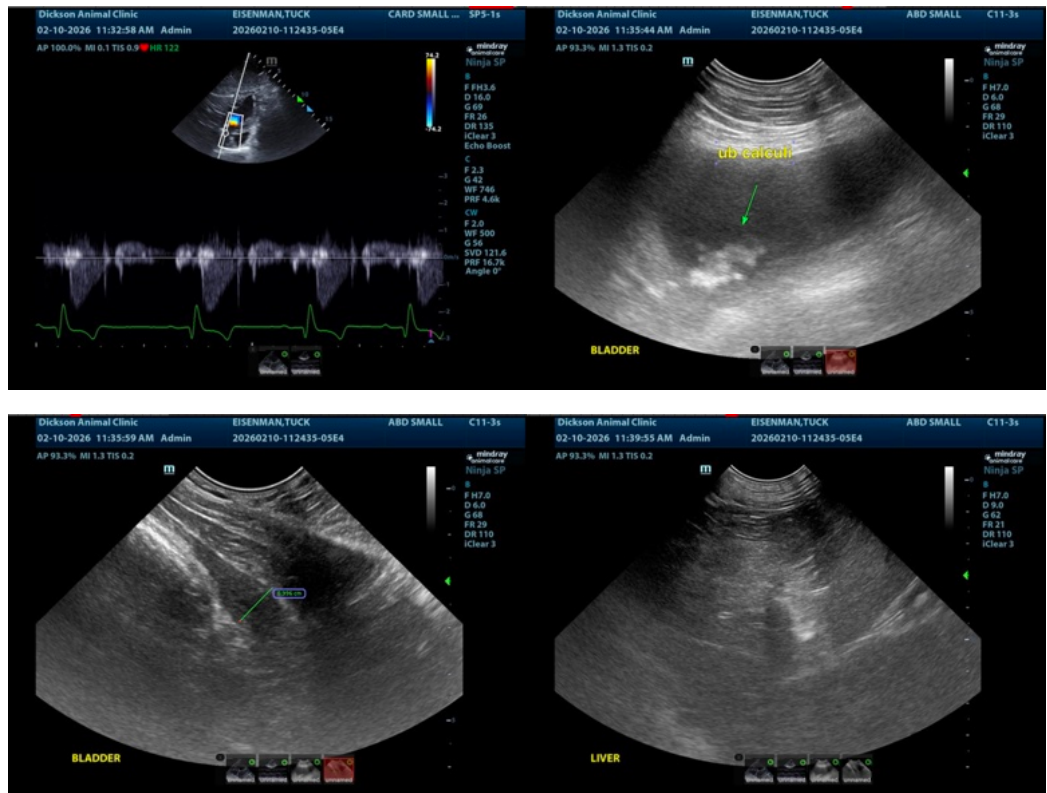
Dr. Huneycutt

**INVOICE**

71465

**DATE**

2/10/26



The information and recommendations provided are based on the images presented by the referring veterinarian/sonographer. No evaluation can be communicated regarding pathology that was not visible in the image/video clips provided.

Thank you for this referral. If the clinical or image interpretation does not parallel your findings or if I can be of any further assistance please contact me.

Eric Lindquist, DMV, DABVP (CFM), Cert. IVUSS, CEO of SonoPath.com

[info@SonoPath.com](mailto:info@SonoPath.com)