



PATIENT

Penny Reynolds

SPECIES

Canine

BREED

Mix

SEX

Spayed female

AGE

12 years

WEIGHT

54 lbs

INTERPRETED BY

Eric Lindquist, DMV
DABVP, Cert. IVUSS

IMAGING PERFORMED BY

Dr. Roche

HOSPITAL NAME

Fredon AH

REFERRING VET

Dr. Roche

INVOICE

71438

DATE

2/10/26

PRESENTING CLINICAL SIGNS

- Continued elevation of liver values on routine monitoring. Dog takes carprofen sporadically on as needed basis
- BCS 6/9, unremarkable exam. ALT 356, Alkphos 498

ULTRASONOGRAPHIC EXAMINATION OF THE ABDOMEN

Urinary System

The **urinary bladder**, trigone, and pelvic urethra presented normal thicknesses and normal tone. The ureters were not visible which is normal. No uroliths or sediment were visualized and anechoic urine was present. No evidence of inflammatory or neoplastic changes was noted. Ureteral papillae were normal.

The **kidneys** revealed largely normal size and structure, corticomedullary definition and ratio (cortex 1/3 of medulla) were essentially maintained with some age-related loss of curvilinear patterns regarding the capsule and C/M junction. The cortices presented largely uniform texture with some increased echogenicity expected for this age patient. Medullary structure differed distinctly from that of the cortex and no evidence of pelvic dilation was present. The left kidney measured 5.1 cm. The right kidney measured 5.7 cm.

Adrenal Glands

Both **adrenal glands** were visualized and recognized as having normal shape, size, position and echogenicity for this breed. The phrenic vasculature, glandular echogenicity and detail were unremarkable. Capsule, cortex, and medullary definition were normal for this age patient. The left adrenal gland was not visualized.

Spleen

The **spleen** presented a smooth homogeneous parenchyma hyperechoic to liver and renal cortical parenchyma. Hyperechoic lipid plaques were noted and were not pathological. The capsule was smooth without noticeable expansion or deviation from within the spleen or adjacent pathology. The splenic vasculature demonstrated normal volume without signs of congestion or thrombosis. No sonographic evidence of acute or chronic inflammatory, neoplastic, or infarctual changes was noted.

Liver

The **liver** images from right and left intercostal as well as subcostal views revealed subjectively normal liver size, contour, and structure. Some age-related parenchymal remodeling was noted but likely not clinically significant at this time. Vascular and biliary tracts were of normal volume and no evidence of congestion was noted. The gallbladder presented some dependent debris with essentially normal contour. The cystic and common bile ducts were normal. No overt evidence of active inflammatory,



PATIENT

Penny Reynolds

SPECIES

Canine

BREED

Mix

SEX

Spayed female

AGE

12 years

WEIGHT

54 lbs

INTERPRETED BY

Eric Lindquist, DMV
DABVP, Cert. IVUSS

IMAGING PERFORMED BY

Dr. Roche

HOSPITAL NAME

Fredon AH

REFERRING VET

Dr. Roche

INVOICE

71438

DATE

2/10/26

infiltrative or regenerative pathology was noted but should be paired with current or past LE elevations regarding any clinical significance to this presentation. The hepatic lymph nodes were unremarkable.

Gastrointestinal

Examination of the **gastrointestinal tract** revealed a stomach and intestine free of stasis, of normal wall thickness, acceptable curvilinear mural detail, and peristaltic activity. Small and large intestine demonstrated normal luminal chyme and stool consistency respectively. No obstructive or overt infiltrative disease was noted. No associated abnormal lymphatic activity was noted.

Pancreas

The base and limbs of the **pancreas** were observed to be largely isoechoic to surrounding omental fat. Pancreatic duct and capsular contour were acceptably normal and parenchyma respected normal curvilinear patterns. No overt evidence of active inflammatory or neoplastic disease was noted.

ULTRASONOGRAPHIC FINDINGS

Structurally unremarkable abdomen, non-specific inflammatory hepatopathy.

INTERPRETATION OF THE FINDINGS & FURTHER RECOMMENDATIONS

FNA of the liver can be considered for further definition. There is a potential for reactive hepatopathy. Leptospirosis titers are indicated.

The hepatic clinical sonographic presentation is most consistent with Reactive Hepatopathy which is the most common cause of liver enzyme elevation in dogs and cats. The presumption is that gut and other organ antigen stimuli may be causing a low-grade immune response through portal system with which the liver is reacting to causing low-grade enzyme elevations. US-guided FNA could be performed to assess if low grade lymphoplasmacytic inflammation is present that would support this theory. If FNA is performed, please ask the cytologist to emphasize the primary inflammatory cell type. Empirical treatment measures to address this issue can include diet change to hydrolyzed diet, probiotics, deworming, nutraceuticals (SAME, Actigall...), dental exam and cleaning, and potentially antibiotics such as Clavamox. Metronidazole and Tylosin have traditionally been utilized for this purpose but new studies show that both these antibiotics can disrupt the normal intestinal bacterial flora (intestinal dysbiosis) for weeks and up to 4-6 months. Therefore, Metronidazole and Tylosin should be utilized as a last resort if other efforts have not been effective and sonographic organ appearance remains benign.



PATIENT

Penny Reynolds

SPECIES

Canine

BREED

Mix

SEX

Spayed female

AGE

12 years

WEIGHT

54 lbs

INTERPRETED BY

Eric Lindquist, DMV
DABVP, Cert. IVUSS

IMAGING PERFORMED BY

Dr. Roche

HOSPITAL NAME

Fredon AH

REFERRING VET

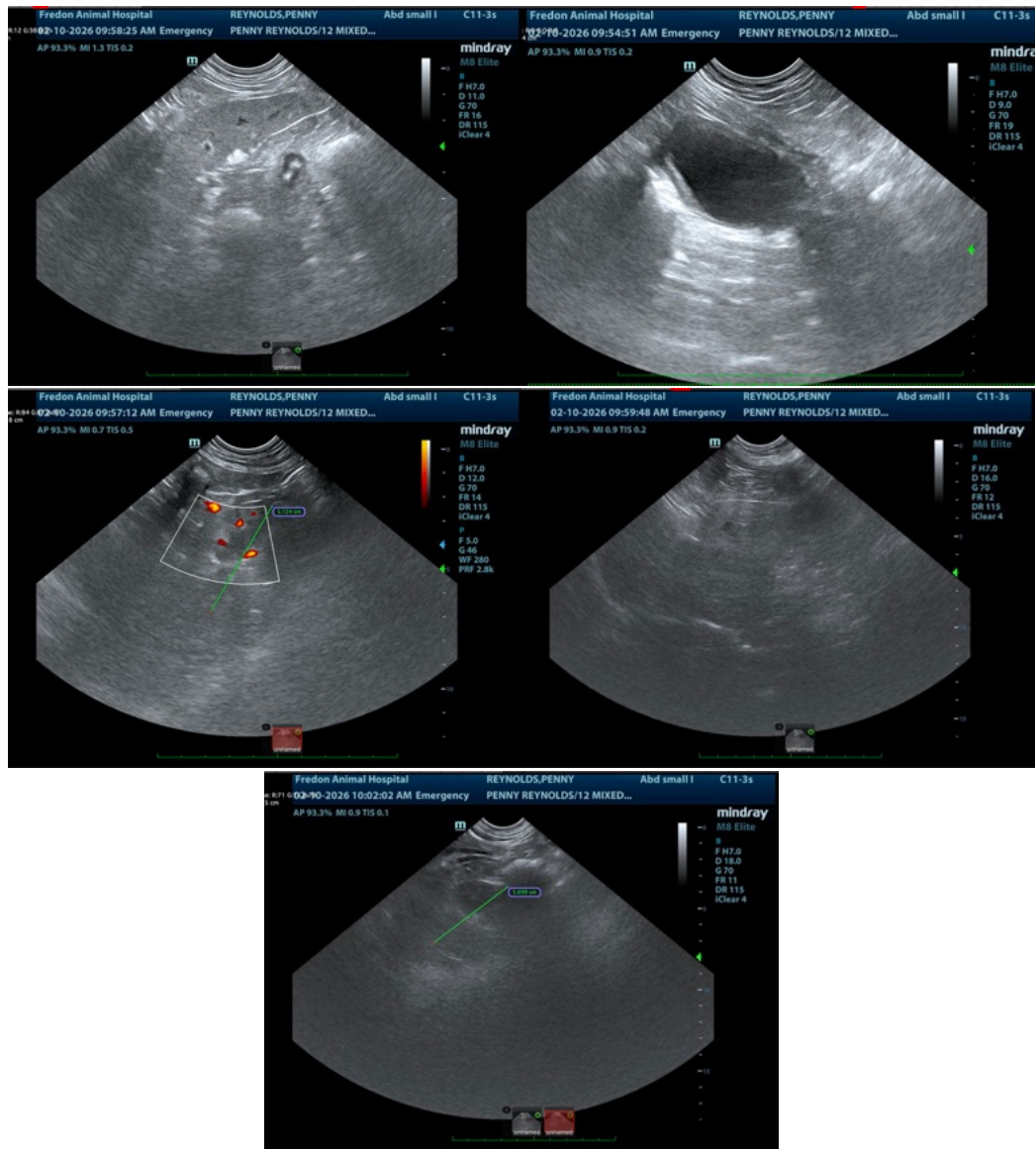
Dr. Roche

INVOICE

71438

DATE

2/10/26



The information and recommendations provided are based on the images presented by the referring veterinarian/sonographer. No evaluation can be communicated regarding pathology that was not visible in the image/video clips provided.

Thank you for this referral. If the clinical or image interpretation does not parallel your findings or if I can be of any further assistance please contact me.

Eric Lindquist, DMV, DABVP (CFM), Cert. IVUSS, CEO of SonoPath.com

info@SonoPath.com