



PATIENT

Melo Forbes

SPECIES

Canine

BREED

Shih Tzu

SEX

Neutered Male

AGE

12 Years

WEIGHT

14.56 lbs

INTERPRETED BY

Eric Lindquist, DMV,
DABVP (CFM), Cert.
IVUSS

IMAGING PERFORMED BY

Vincent Ravancho, CVT

HOSPITAL NAME

Summit Dog & Cat
Hospital

REFERRING VET

Dr. Baker

INVOICE

72857

DATE

2/10/26

PRESENTING CLINICAL SIGNS

Cardiac Failure (rads performed at ER on 1/14). HM V/VI, increased resp rate

Medications: Furosemide 12.5 mg tabs - give 1/2 tab BID, Pimobendan 5mg - 1/2 tab BID

ULTRASONOGRAPHIC EXAMINATION OF THE HEART

CANINE CARDIAC PARAMETERS	MR VMAX (m/s)	TR VMAX (m/s)	LA/AO (M-Mode)	LA/AO (Heart Base; Swe)	FS (%)	EF (%)	EPSS (cm)
NORMAL PARAMETER	4.5-5.5	<2.7	1.3	Up to 1.6	28-40	40-100	<0.6
PATIENT	5.0	2.8	1.8	2.1	50	56	0.1
CANINE CARDIAC PARAMETERS	HR (BPM)	AV VMAX (m/s)	PV MAX (m/s)	BODY WEIGHT (lbs)	LAD LA MAX 4 Chamber	LVIDd Avg; 2D and m-mode short axis (cm)	LVIDs Avg; 2D and m-mode short axis (cm)
NORMAL PARAMETER	50-100	0.7-1.7	0.7-1.6				
PATIENT	100	1.3	2.0	14.56	3.6	3.5	--

Cardiac Presentation

The echocardiogram for this patient presented excessive **left atrial size** expressed both in the LA/AO and LA max measurements Chamber volumes and echogenicity were normal. The cranial and caudal **mitral** valve leaflets presented vegetative thickening consistent with endocardiosis. Doppler indicated measurable insufficiency. Severe prolapse of the anterior mitral valve leaflet noted. The **left ventricle** presented thicknesses with linear contour and was not dilated nor restricted. The **myocardium** presented normal echogenicity without subjective evidence of significant fibrotic or ischemic disease. **Contractility** of the ventricular walls was adequate and in normal range for this patient evidenced by the fractional shortening measurement and subjective evaluation of the different regions of the myocardium. The **left ventricular outflow** tract demonstrated normal laminar flow and subjective structural integrity. The **right atrium** and auricle revealed normal size, structure and content. No evidence of masses was noted or chamber overload. **Tricuspid** insufficiency noted. The **right ventricle** was of normal size (1/3 diameter of LV), chordae structure, myocardial echogenicity and thickness. **Pulmonic** tract assessment revealed normal valve structure, laminar flow, and diameter (approx.1:1 pa/ao ratio). Bradyarrhythmia noted. Pulmonary edema lines noted.

ULTRASONOGRAPHIC FINDINGS

- Stage C1 valvular disease.
- Bradyarrhythmia.



PATIENT

Melo Forbes

SPECIES

Canine

BREED

Shih Tzu

SEX

Neutered Male

AGE

12 Years

WEIGHT

14.56 lbs

INTERPRETED BY

Eric Lindquist, DMV,
 DABVP (CFM), Cert.
 IVUSS

IMAGING PERFORMED BY

Vincent Ravancho, CVT

HOSPITAL NAME

Summit Dog & Cat
 Hospital

REFERRING VET

Dr. Baker

INVOICE

72857

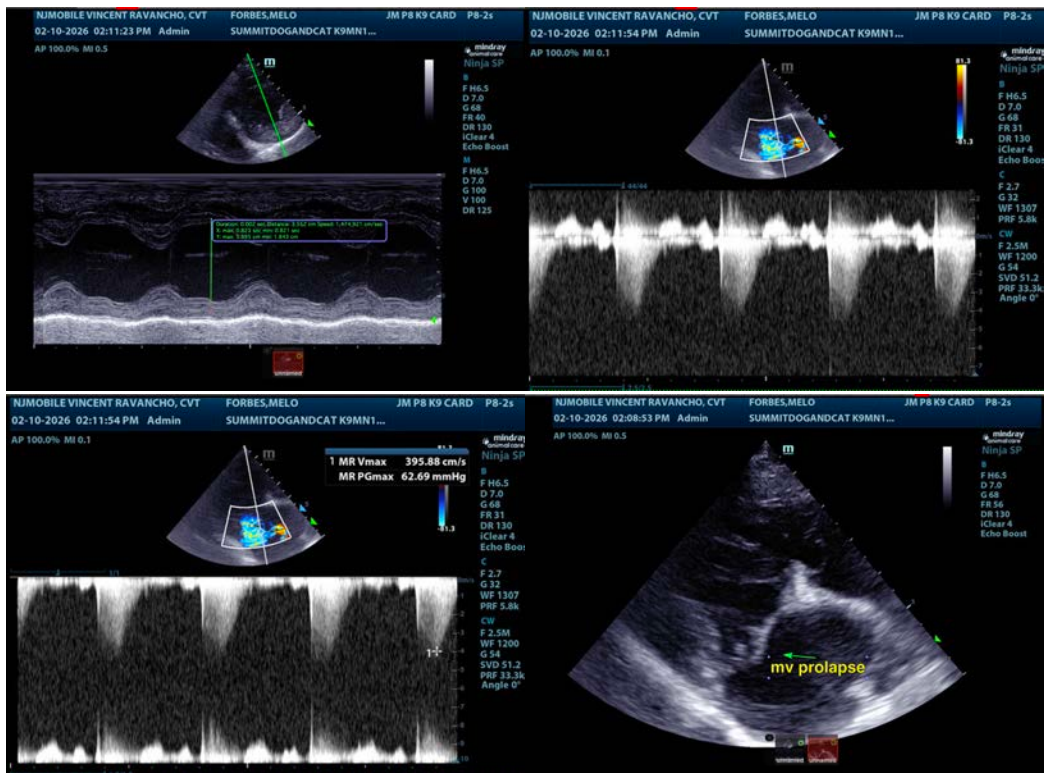
DATE

2/10/26

INTERPRETATION OF THE FINDINGS & FURTHER RECOMMENDATIONS

EKG indicated to assess for cause of bradyarrhythmia. Recommend continuation with Pimobendan, Lasix, and adding ACE inhibitor 0.5 mg/kg SID progressing to BID, and Spironolactone at 1-2 mg/kg BID. Concurrent respiratory disease may also be present in this patient.

The heart is in a somewhat precarious state with volume overload and a heart that is working to compensate for the valvular insufficiency. Target respiratory rate is < 20 resp/minute after therapy. After initiating therapy, I recommend recheck on the clinical exam, BUN, Creatinine, USG, Chest radiographs & Blood pressure in 5-7 days. Recheck echo in 1 month. Earlier if clinical decompensation is occurring. I do not recommend anesthesia at this time until stabilization has occurred on the recommended medications. Repeat preanesthetic echo is ideal if anesthesia is eventually necessary. There is severe anesthetic risk for this patient. Light dose opioids may be used to calm but I do not recommend anesthesia.





PATIENT

Melo Forbes

SPECIES

Canine

BREED

Shih Tzu

SEX

Neutered Male

AGE

12 Years

WEIGHT

14.56 lbs

INTERPRETED BY

Eric Lindquist, DMV,
DABVP (CFM), Cert.
IVUSS

IMAGING PERFORMED BY

Vincent Ravancho, CVT

HOSPITAL NAME

Summit Dog & Cat
Hospital

REFERRING VET

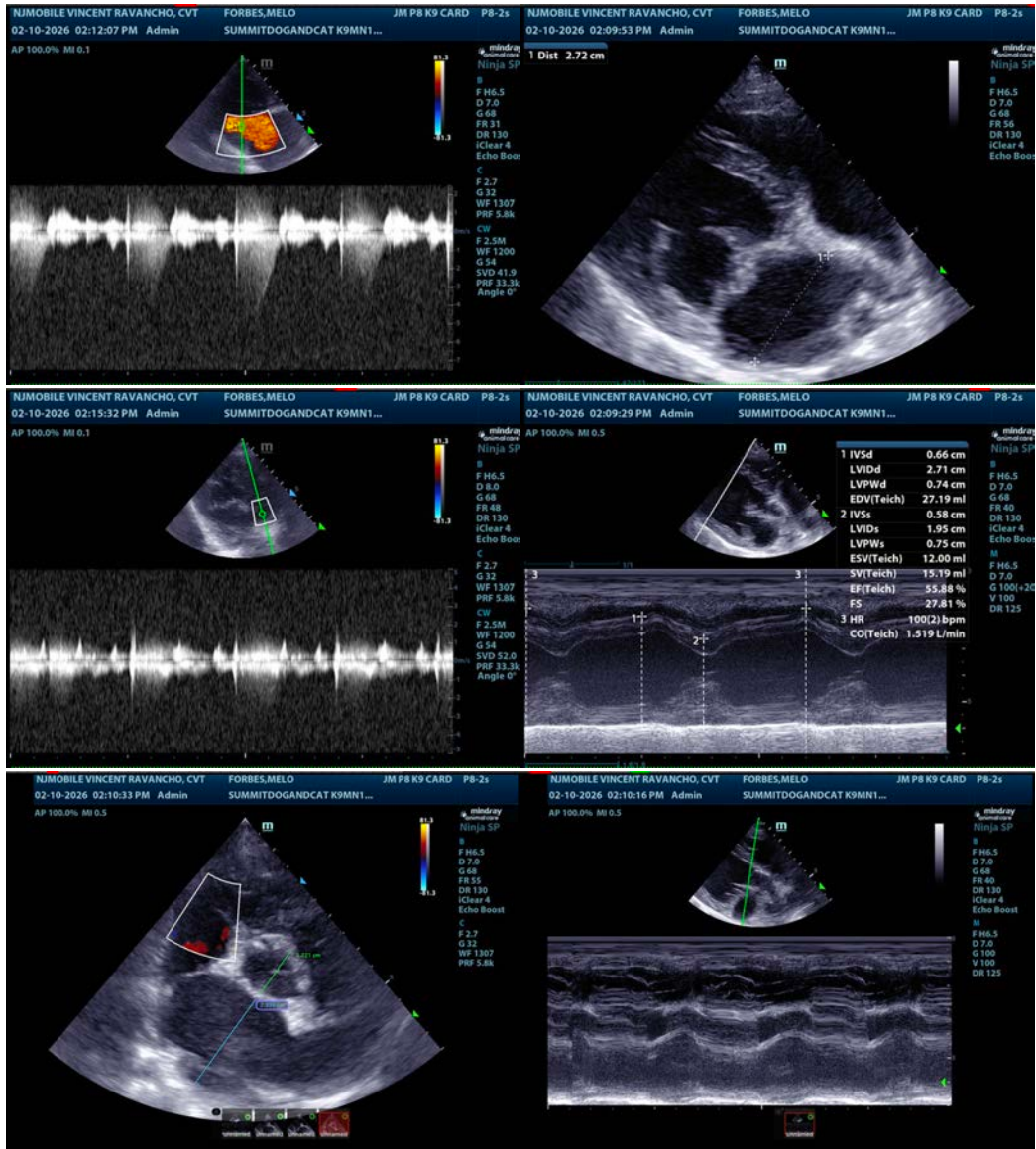
Dr. Baker

INVOICE

72857

DATE

2/10/26





PATIENT

Melo Forbes

SPECIES

Canine

BREED

Shih Tzu

SEX

Neutered Male

AGE

12 Years

WEIGHT

14.56 lbs

INTERPRETED BY

Eric Lindquist, DMV,
DABVP (CFM), Cert. IVUSS

IMAGING PERFORMED BY

Vincent Ravancho, CVT

HOSPITAL NAME

Summit Dog & Cat
Hospital

REFERRING VET

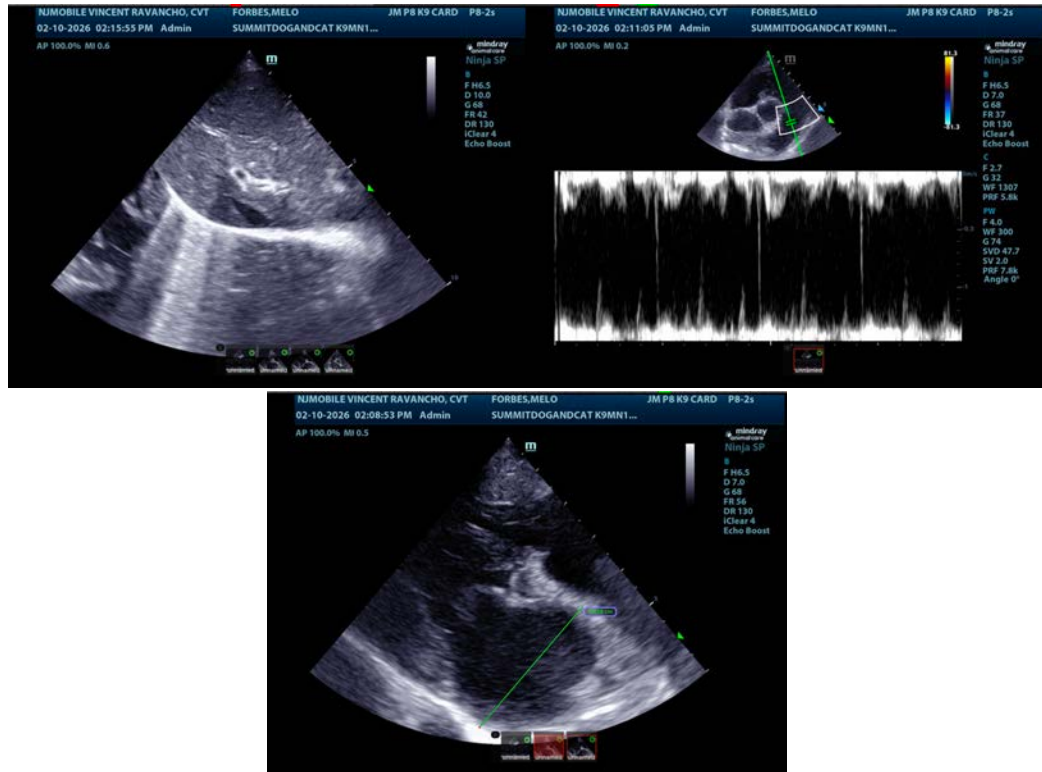
Dr. Baker

INVOICE

72857

DATE

2/10/26



The information and recommendations provided are based on the images presented by the referring veterinarian/sonographer. No evaluation can be communicated regarding pathology that was not visible in the image/video clips provided.

Thank you for this referral. If the clinical or image interpretation does not parallel your findings or if I can be of any further assistance please contact me.

Eric Lindquist, DMV, DABVP(CFM), Cert. IVUSS,
CEO, Owner, Founder -- SonoPath.com
info@SonoPath.com