



PATIENT

Luna Fehrs

SPECIES

Feline

BREED

Domestic Shorthair

SEX

Spayed female

AGE

7 years

WEIGHT

6.9 lbs

INTERPRETED BY

Eric Lindquist, DMV
DABVP, Cert. IVUSS

IMAGING PERFORMED BY

Ashley Whitesell

HOSPITAL NAME

Dickson AC

REFERRING VET

Dr. Levine

INVOICE

71441

DATE

2/10/26

PRESENTING CLINICAL SIGNS

- Vomiting, lethargy, weight loss, diarrhea
- WBC 17.86 ALT 173

ULTRASONOGRAPHIC EXAMINATION OF THE ABDOMEN *Urinary System*

The **urinary bladder**, trigone, and pelvic urethra presented normal thicknesses and normal tone. The ureters were not visible which is normal. No uroliths or sediment were visualized and anechoic urine was present. No evidence of inflammatory or neoplastic changes was noted. Ureteral papillae were normal.

The **kidneys** revealed largely normal size and structure, corticomedullary definition and ratio (cortex 1/3 of medulla) were essentially maintained with some age-related loss of curvilinear patterns regarding the capsule and C/M junction. The cortices presented largely uniform texture with some increased echogenicity expected for this age patient. Medullary structure differed distinctly from that of the cortex and no evidence of pelvic dilation was present. The left kidney measured 3.6 cm. The right kidney measured 4.04 cm.

Adrenal Glands

Both **adrenal glands** were visualized and recognized as having normal shape, size, position and echogenicity for this breed. The phrenic vasculature, glandular echogenicity and detail were unremarkable. Capsule, cortex, and medullary definition were normal for this age patient. The left and right adrenal gland measured 0.4 cm each.

Spleen

The **spleen** in this patient was uniform, yet volume contracted. Hydration status should be assessed.

Liver

The **liver** images from right and left intercostal as well as subcostal views revealed subjectively normal liver size, contour, and structure. Some age-related parenchymal remodeling was noted but likely not clinically significant at this time. Vascular and biliary tracts were of normal volume and no evidence of congestion was noted. The gallbladder presented some dependent debris with essentially normal contour. The cystic and common bile ducts were normal. No overt evidence of active inflammatory, infiltrative or regenerative pathology was noted but should be paired with current or past LE elevations regarding any clinical significance to this presentation. The hepatic lymph nodes were unremarkable.

Gastrointestinal

There was some residual chyme and gas was noted in the **stomach**, yet not pathological. This is consistent with post prandial presentation. Transit of chyme into the small intestine was normal.



PATIENT

Luna Fehrs

SPECIES

Feline

BREED

Domestic Shorthair

SEX

Spayed female

AGE

7 years

WEIGHT

6.9 lbs

INTERPRETED BY

Eric Lindquist, DMV
DABVP, Cert. IVUSS

IMAGING PERFORMED BY

Ashley Whitesell

HOSPITAL NAME

Dickson AC

REFERRING VET

Dr. Levine

INVOICE

71441

DATE

2/10/26

Curvilinear patterns were maintained throughout the GI tract. No evidence of pathology. Small and large intestine demonstrated normal luminal chyme and stool consistency respectively. The mesenteric lymph nodes were reactive and minor measuring up to 0.7 cm.

Pancreas

The base and limbs of the **pancreas** were observed to be largely isoechoic to surrounding omental fat. Pancreatic duct and capsular contour were acceptably normal and parenchyma respected normal curvilinear patterns. No overt evidence of active inflammatory or neoplastic disease was noted.

ULTRASONOGRAPHIC FINDINGS

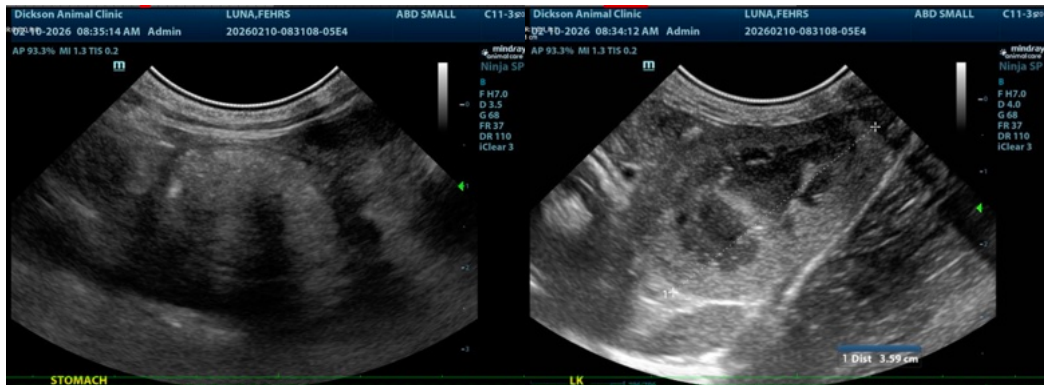
Geriatric abdomen.

Slight mesenteric lymph node prominence and inflammatory hepatopathy or reactive hepatopathy.

INTERPRETATION OF THE FINDINGS & FURTHER RECOMMENDATIONS

There was no specific pathology.

Maldigestion panel, three view chest radiographs and full CNS examination is recommended to examine for occult disease that could be responsible for the weight loss. Evaluation for competitive eating environments should also be considered.





PATIENT

Luna Fehrs

SPECIES

Feline

BREED

Domestic Shorthair

SEX

Spayed female

AGE

7 years

WEIGHT

6.9 lbs

INTERPRETED BY

Eric Lindquist, DMV
DABVP, Cert. IVUSS

IMAGING PERFORMED BY

Ashley Whitesell

HOSPITAL NAME

Dickson AC

REFERRING VET

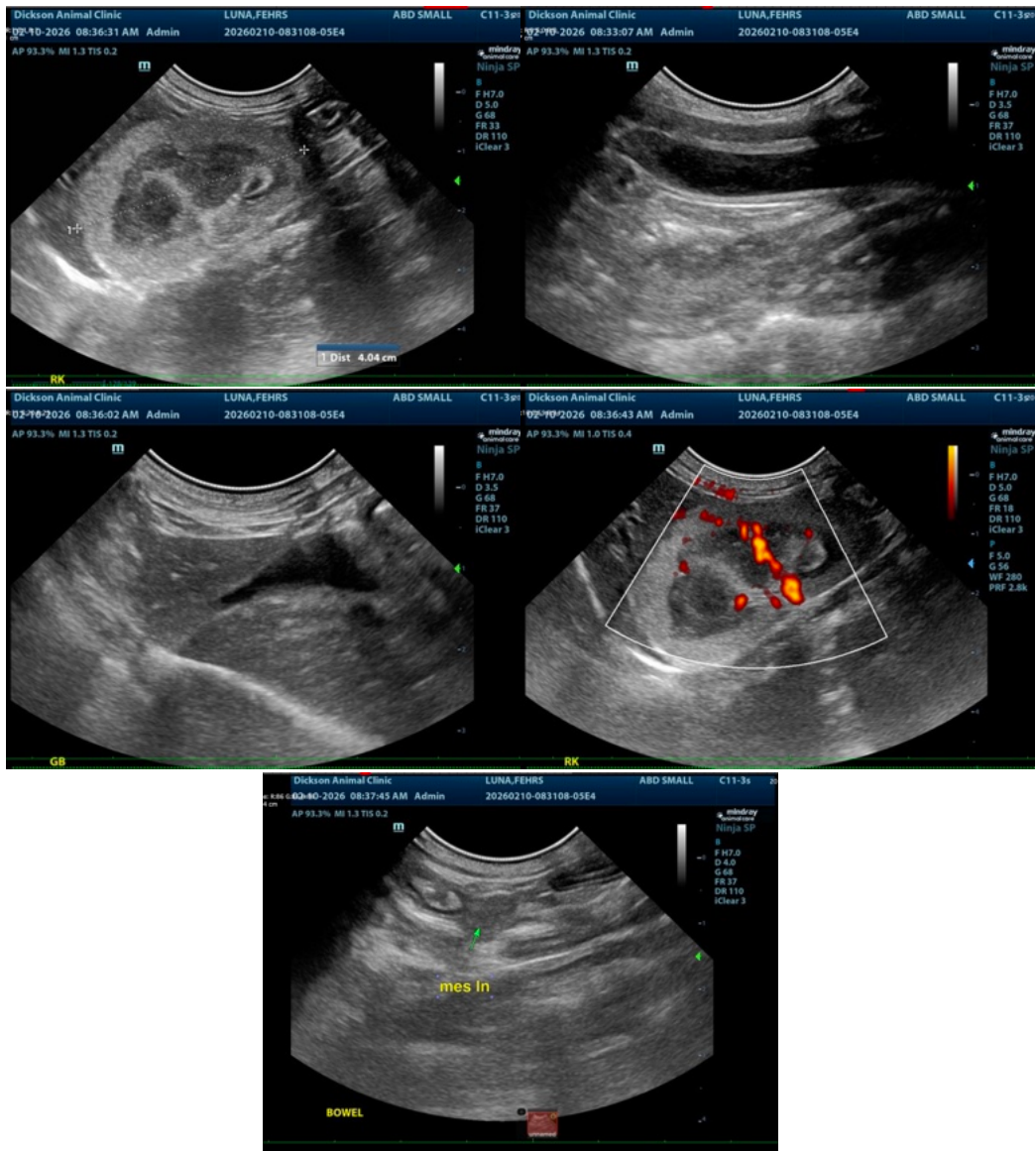
Dr. Levine

INVOICE

71441

DATE

2/10/26



The information and recommendations provided are based on the images presented by the referring veterinarian/sonographer. No evaluation can be communicated regarding pathology that was not visible in the image/video clips provided.

Thank you for this referral. If the clinical or image interpretation does not parallel your findings or if I can be of any further assistance please contact me.

Eric Lindquist, DMV, DABVP (CFM), Cert. IVUSS, CEO of SonoPath.com

info@SonoPath.com