



PATIENT **PRESENTING CLINICAL SIGNS**
Jeter Rao Early B2, currently on Vetmedin

SPECIES **ULTRASONOGRAPHIC EXAMINATION OF THE HEART**

Canine

BREED

Cavalier

SEX

Neutered Male

AGE

16 Years

WEIGHT

Not Provided

CANINE CARDIAC PARAMETERS	MR VMAX (m/s)	TR VMAX (m/s)	LA/AO (M-Mode)	LA/AO (Heart Base; Swe)	FS (%)	EF (%)	EPSS (cm)
NORMAL PARAMETER	4.5-5.5	<2.7	1.3	Up to 1.6	28-40	40-100	<0.6
PATIENT	7.0	--	NM	1.5	33	64	0.1
CANINE CARDIAC PARAMETERS	HR (BPM)	AV VMAX (m/s)	PV MAX (m/s)	BODY WEIGHT (kg)	LAD LA MAX 4 Chamber	LVIDd Avg; 2D and m-mode short axis (cm)	LVIDs Avg; 2D and m-mode short axis (cm)
NORMAL PARAMETER	50-100	0.7-1.7	0.7-1.6				
PATIENT	136	2.1	1.1	NP	3.07	3.16	--

INTERPRETED BY

Eric Lindquist, DMV,
DABVP(CFM), Cert.
IVUSS

IMAGING PERFORMED BY

Eric Lindquist, DMV,
DABVP(CFM), Cert.
IVUSS

HOSPITAL NAME

Franklin Lakes Animal
Hospital

REFERRING VET

Dr. Hudson

INVOICE

13661

DATE

02/10/26

Cardiac Presentation

Significant improvement from the prior sonogram. Mitral insufficiency was persistent. The liver was unremarkable. Occasional arrhythmia is noted in this patient.

ULTRASONOGRAPHIC FINDINGS

- Compensated mitral insufficiency.

INTERPRETATION OF THE FINDINGS & FURTHER RECOMMENDATIONS

Systemic hypertension may be an issue. EKG and serial blood pressure is indicated. No adjustment in current cardiac protocol as left-sided volumes have normalized.



PATIENT

Jeter Rao

SPECIES

Canine

BREED

Cavalier

SEX

Neutered Male

AGE

16 Years

WEIGHT

Not Provided

INTERPRETED BY

Eric Lindquist, DMV,
DABVP(CFM), Cert.
IVUSS

IMAGING PERFORMED BY

Eric Lindquist, DMV,
DABVP(CFM), Cert.
IVUSS

HOSPITAL NAME

Franklin Lakes Animal
Hospital

REFERRING VET

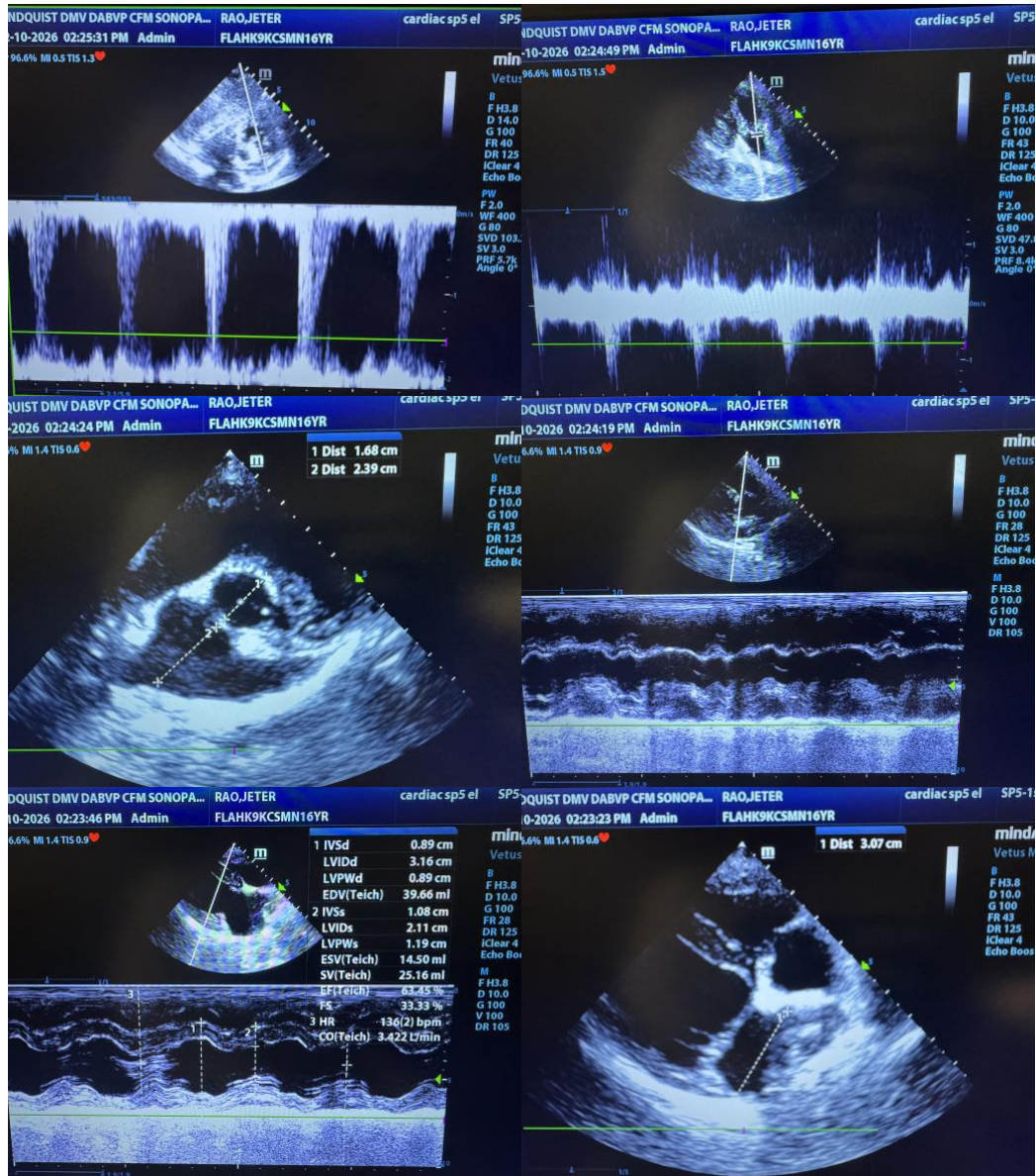
Dr. Hudson

INVOICE

13661

DATE

02/10/26



The information and recommendations provided are based on the images presented by the referring veterinarian/sonographer. No evaluation can be communicated regarding pathology that was not visible in the image/video clips provided.

Thank you for this referral. If the clinical or image interpretation does not parallel your findings or if I can be of any further assistance, please contact me.

Eric Lindquist, DMV, DABVP(CFM), Cert. IVUSS,

CEO, Owner, Founder -- SonoPath.com



PATIENT info@SonoPath.com

Jeter Rao

SPECIES

Canine

BREED

Cavalier

SEX

Neutered Male

AGE

16 Years

WEIGHT

Not Provided

INTERPRETED BY

Eric Lindquist, DMV,
DABVP(CFM), Cert.
IVUSS

**IMAGING
PERFORMED BY**

Eric Lindquist, DMV,
DABVP(CFM), Cert.
IVUSS

HOSPITAL NAME

Franklin Lakes Animal
Hospital

REFERRING VET

Dr. Hudson

INVOICE

13661

DATE

02/10/26