



PATIENT

Gypsy Tomulich

SPECIES

Feline

BREED

Domestic Shorthair

SEX

Spayed female

AGE

18 years

WEIGHT

10 lbs

INTERPRETED BY

Eric Lindquist, DMV
DABVP, Cert. IVUSS

IMAGING PERFORMED BY

Jenn

HOSPITAL NAME

Rockaway AH

REFERRING VET

Dr. Maniar

INVOICE

71423

DATE

2/10/26

PRESENTING CLINICAL SIGNS

- Recheck previous UA 2/9 rechecking pancreatic cyst

ULTRASONOGRAPHIC EXAMINATION

The intestinal submucosa was slightly irregular, thickened and hyperechoic suggestive of low grade, chronic disease. The mesenteric lymph nodes were reactive and measured up to 1.0 x 0.4 cm.

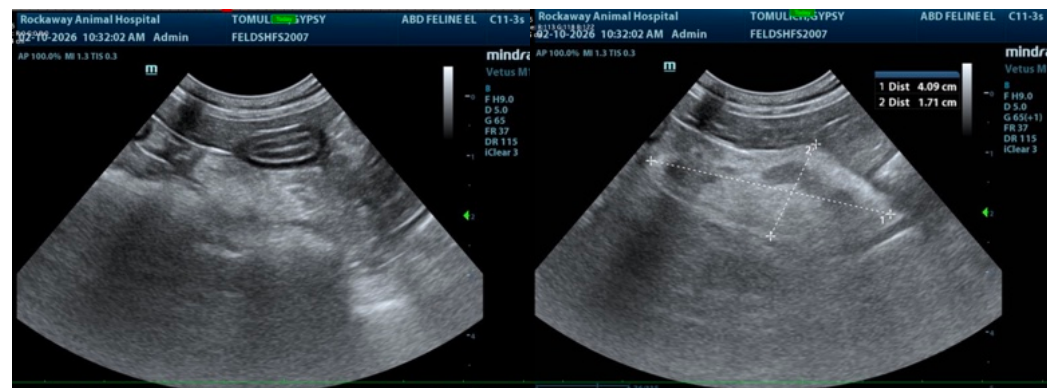
Portions of the pancreas were visualized without evident pathology.

ULTRASONOGRAPHIC FINDINGS

Minor, variable small intestinal thickening with reactive mesenteric lymph nodes.

INTERPRETATION OF THE FINDINGS & FURTHER RECOMMENDATIONS

No residual cystic changes noted in the images provided.



The information and recommendations provided are based on the images presented by the referring veterinarian/sonographer. No evaluation can be communicated regarding pathology that was not visible in the image/video clips provided.

Thank you for this referral. If the clinical or image interpretation does not parallel your findings or if I can be of any further assistance please contact me.

Eric Lindquist, DMV, DABVP (CFM), Cert. IVUSS, CEO of SonoPath.com

info@SonoPath.com