



**PATIENT**

Gus Avery

**SPECIES**

Canine

**BREED**

Border Collie

**SEX**

Neutered Male

**AGE**

9 Years

**WEIGHT**

67 Pounds

**INTERPRETED BY**

Eric Lindquist, DMV,  
DABVP (Canine &  
Feline), Cert. IVUSS

**IMAGING PERFORMED BY**

Darice Ackerson-  
Gordon

**HOSPITAL NAME**

Clovercroft Veterinary  
Hospital

**REFERRING VET**

Dr. David Harris

**INVOICE**

13699

**DATE**

02/10/26

**PRESENTING CLINICAL SIGNS**

Elevated ProBNP

**ULTRASONOGRAPHIC EXAMINATION OF THE HEART**

CANINE CARDIAC PARAMETERS	MR VMAX (m/s)	TR VMAX (m/s)	LA/AO (M-Mode)	LA/AO (Heart Base; Swe)	FS (%)	EF (%)	EPSS (cm)
NORMAL PARAMETER	4.5-5.5	<2.7	1.3	Up to 1.6	28-40	40-100	<0.6
PATIENT	--	--	1.1	1.7	35	80	0.1
CANINE CARDIAC PARAMETERS	HR (BPM)	AV VMAX (m/s)	PV MAX (m/s)	BODY WEIGHT (lbs)	LAD LA MAX 4 Chamber	LVIDd Avg; 2D and m-mode short axis (cm)	LVIDs Avg; 2D and m-mode short axis (cm)
NORMAL PARAMETER	50-100	0.7-1.7	0.7-1.6				
PATIENT	70	--	--	67.0	4.3	3.9	--

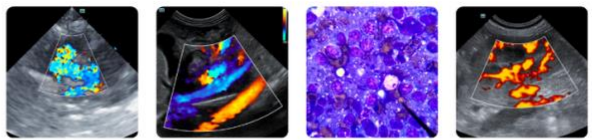
**Cardiac Presentation**

The echocardiogram in this patient demonstrated normal **left atrial** size based on 3 separate methods of LA evaluation. The cranial and caudal **mitral** valve leaflets presented normal linear structure, extension in systole, and union in diastole with normal kinesis. The **left ventricle** presented normal thicknesses with linear contour and was not dilated nor restricted. The **myocardium** presented normal echogenicity without subjective evidence of significant fibrotic or ischemic disease. **Contractility** of the ventricular walls was adequate and in normal range for this patient evidenced by the fractional shortening measurement and subjective evaluation of the different regions of the myocardium. The **left ventricular outflow** tract demonstrated normal laminar flow and subjective structural integrity. The **right atrium** and auricle revealed normal size, structure and content. No evidence of masses was noted. **Tricuspid** valvular assessment demonstrated adequate linear morphology and kinesis. The **right ventricle** was of normal size (1/3 diameter of LV), chordae structure, myocardial echogenicity and thickness. **Pulmonary outflow** tract assessment revealed normal valve structure, laminar flow, and diameter (approx.1:1 pa/ao ratio). No visible **pericardial** or free pleura fluid was noted. The cranial **mediastinum and pericardial and extra-cardiac regions** were free of masses in the visible window. Arrhythmogenic activity is potentially present. The hepatic veins were not dilated.

**ULTRASONOGRAPHIC FINDINGS**

- Normal echocardiogram with mild bradycardia.

**INTERPRETATION OF THE FINDINGS & FURTHER RECOMMENDATIONS**



**PATIENT**

Baseline EKG and blood pressure are indicated. No evidence of structural or functional disease.

Gus Avery

**SPECIES**

Canine

**BREED**

Border Collie

**SEX**

Neutered Male

**AGE**

9 Years

**WEIGHT**

67 Pounds

**INTERPRETED BY**

Eric Lindquist, DMV,  
DABVP (Canine &  
Feline), Cert. IVUSS

**IMAGING  
PERFORMED BY**

Darice Ackerson-  
Gordon

**HOSPITAL NAME**

Clovercroft Veterinary  
Hospital

**REFERRING VET**

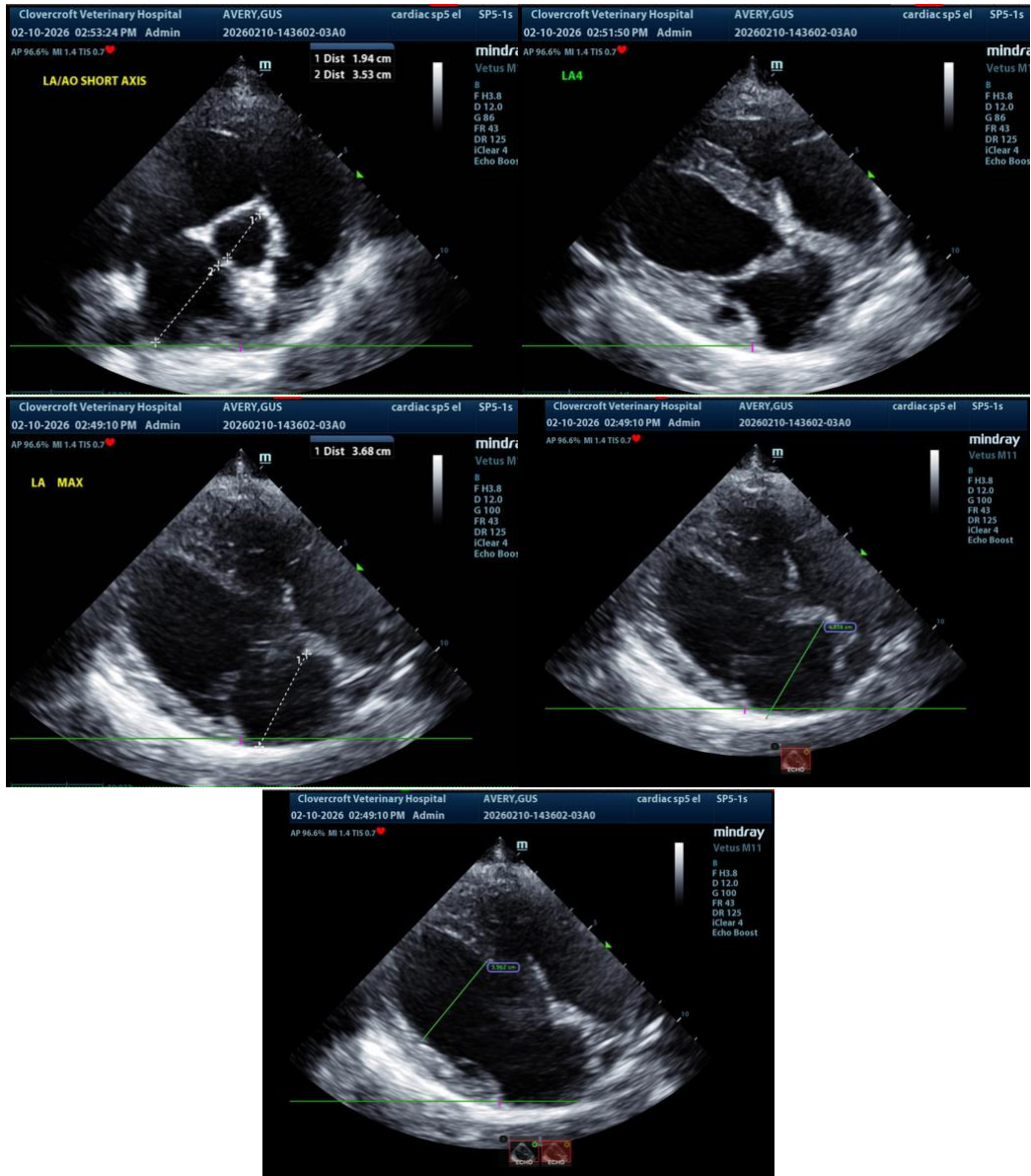
Dr. David Harris

**INVOICE**

13699

**DATE**

02/10/26



The information and recommendations provided are based on the images presented by the referring veterinarian/sonographer. No evaluation can be communicated regarding pathology that was not visible in the image/video clips provided.

Thank you for this referral. If the clinical or image interpretation does not parallel your findings or if I can be of any further assistance please contact me.

Eric Lindquist, DMV, DABVP (Canine & Feline), Cert. IVUSS

CEO, Owner, Founder -- SonoPath.com



**PATIENT**

[info@SonoPath.com](mailto:info@SonoPath.com)

Gus Avery

**SPECIES**

Canine

**BREED**

Border Collie

**SEX**

Neutered Male

**AGE**

9 Years

**WEIGHT**

67 Pounds

**INTERPRETED BY**

Eric Lindquist, DMV,  
DABVP (Canine &  
Feline), Cert. IVUSS

**IMAGING  
PERFORMED BY**

Darice Ackerson-  
Gordon

**HOSPITAL NAME**

Clovercroft Veterinary  
Hospital

**REFERRING VET**

Dr. David Harris

**INVOICE**

13699

**DATE**

02/10/26