



## PATIENT

Bailey Eye

## SPECIES

Ferret

## BREED

Ferret

## SEX

Spayed Female

## AGE

6 Years

## WEIGHT

2.16 pounds

## INTERPRETED BY

Eric Lindquist, DMV,  
DABVP(CFM), Cert.  
IVUSS

## IMAGING PERFORMED BY

Alexis Cervantes

## HOSPITAL NAME

TLC Animal Hospital

## REFERRING VET

Dr. Priscilla Rubio

## INVOICE

13697

## DATE

02/10/26

## PRESENTING CLINICAL SIGNS

- Bailey is an 6yo ferret that presented for historical tumor on base of tail for about 3 years. On PE, I feel something firm/lumpy in cranial abdomen, spleen feels prominent, ~30mm firm tail base tumor that is invading rectum, has alopecia. P not able to poop normally due to constipation from pressure of tumor. Doing abdominal ultrasound to check for metastasis in abdomen.

Abnormal PE/Chem/CBC/UA Results: We sent off bloodwork

## ULTRASONOGRAPHIC EXAMINATION OF THE ABDOMEN

### Urinary System

The **urinary bladder**, trigone, and pelvic urethra presented normal thicknesses and normal tone. The ureters were not visible which is normal. No uroliths or sediment were visualized, and anechoic urine was present. No evidence of inflammatory or neoplastic changes were noted. Ureteral papillae were normal.

The **kidneys** presented with moderate degenerative changes and cortical mineralizations as well as slight pyelectasia. Microcystic changes were present as well as areas of cortical collapse. The left kidney measured 2.5 cm in length. The right kidney measured 2.8 cm in length.

### Adrenal Glands

The regions of the **adrenal glands** were imaged with no gross pathology.

### Spleen

The **spleen** presented enlarged and irregular with scalloping contour. The spleen was folded upon itself. Trace amount of free fluid were noted.

### Liver

The **liver** presented with polycystic parenchymal changes occupying a majority of the liver. The gallbladder and common bile duct were unremarkable.

### Gastrointestinal

Examination of the **gastrointestinal tract** revealed a stomach and intestine free of stasis, of normal wall thickness, acceptable curvilinear mural detail, and peristaltic activity. Small and large intestine demonstrated normal luminal chyme and stool consistency respectively. No obstructive or overt infiltrative disease was noted. No associated abnormal lymphatic activity was noted.

### Pancreas

The base and limbs of the **pancreas** were observed to be largely isoechoic to surrounding omental fat. Pancreatic duct and capsular contour were acceptably normal and parenchyma respected normal curvilinear patterns. No overt evidence of active inflammatory or neoplastic disease was noted.

### Free Abdomen

A large amount of abdominal fat was noted in this patient.



## PATIENT

Bailey Eye

## SPECIES

Ferret

## BREED

Ferret

## SEX

Spayed Female

## AGE

6 Years

## WEIGHT

2.16 pounds

## INTERPRETED BY

Eric Lindquist, DMV,  
DABVP(CFM), Cert.  
IVUSS

## IMAGING PERFORMED BY

Alexis Cervantes

## HOSPITAL NAME

TLC Animal Hospital

## REFERRING VET

Dr. Priscilla Rubio

## INVOICE

13697

## DATE

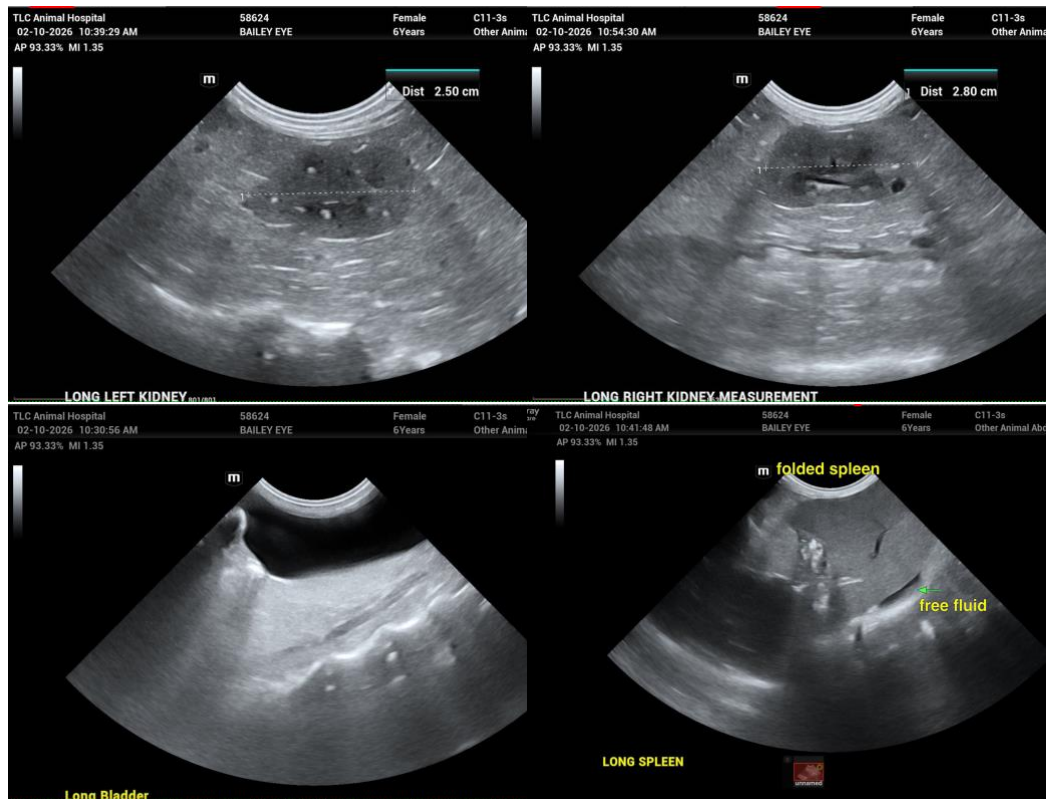
02/10/26

## ULTRASONOGRAPHIC FINDINGS

- Polycystic kidneys with moderate degenerative changes.
- Polycystic liver.
- Splenomegaly with folding- reactive spleen versus emerging round cell neoplasia.
- Abdominal fat.

## INTERPRETATION OF THE FINDINGS & FURTHER RECOMMENDATIONS

25-gauge FNA is indicated.





## PATIENT

Bailey Eye

## SPECIES

Ferret

## BREED

Ferret

## SEX

Spayed Female

## AGE

6 Years

## WEIGHT

2.16 pounds

## INTERPRETED BY

Eric Lindquist, DMV,  
DABVP(CFM), Cert.  
IVUSS

## IMAGING PERFORMED BY

Alexis Cervantes

## HOSPITAL NAME

TLC Animal Hospital

## REFERRING VET

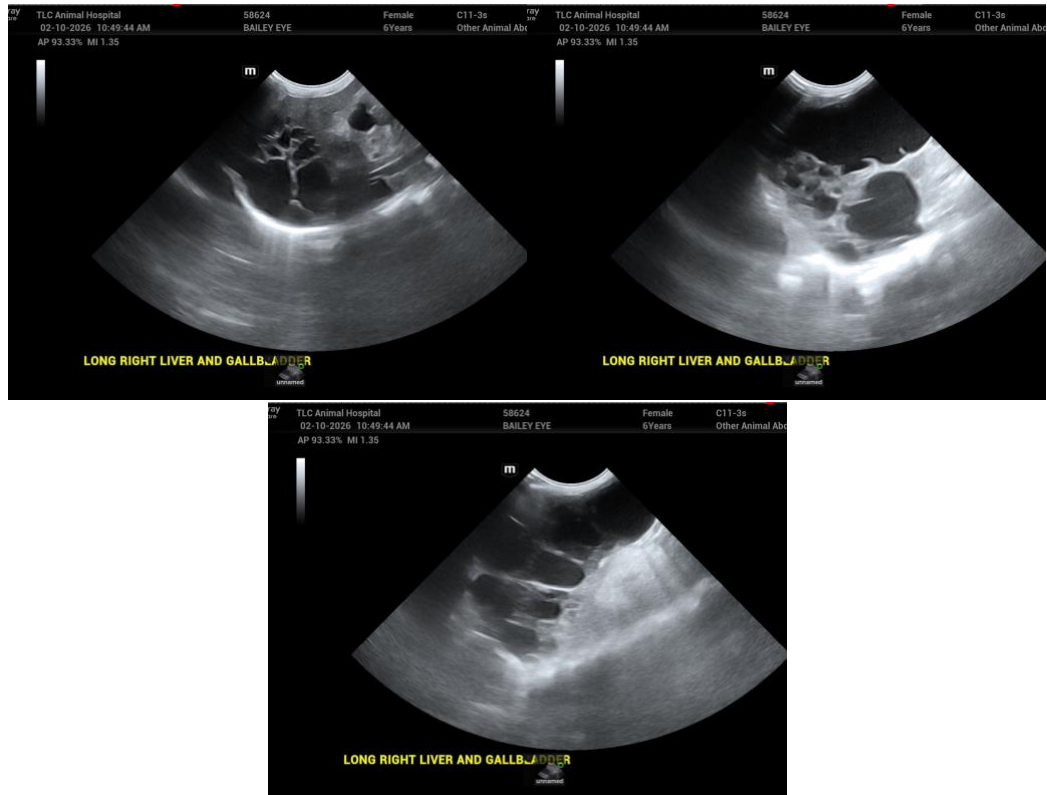
Dr. Priscilla Rubio

## INVOICE

13697

## DATE

02/10/26



The information and recommendations provided are based on the images presented by the referring veterinarian/sonographer. No evaluation can be communicated regarding pathology that was not visible in the image/video clips provided.

Thank you for this referral. If the clinical or image interpretation does not parallel your findings or if I can be of any further assistance, please contact me.

**Eric Lindquist, DMV, DABVP(CFM), Cert. IVUSS,**

CEO, Owner, Founder -- SonoPath.com

[info@SonoPath.com](mailto:info@SonoPath.com)