SonoPath
Clinical Sonography & Telecytology

EDUCATIONAL TELECONSULTATION SERVICES™

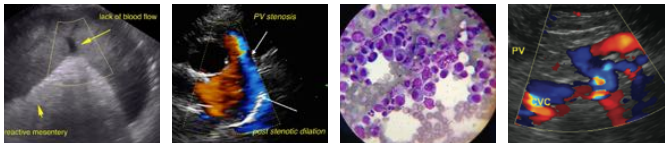

SonoPath.com™
1-800-838-4268 info@sonopath.com

PATIENT
Penny McDermott

SPECIES
Canine

BREED
Fox Terrier

SEX
Spayed female

AGE
10 years

WEIGHT
15.7 lbs

INTERPRETED BY
Eric Lindquist, DMV
DABVP, Cert. IVUSS

IMAGING PERFORMED BY
Christina

HOSPITAL NAME
Animal Health VC

REFERRING VET
Dr. Hughes

INVOICE
42713

DATE
2/10/23

PRESENTING CLINICAL SIGNS

History: P presented 1/27/23 with vomiting for 3 days, lethargy, shaking and not eating for approx. 3 days. Focal US done at that time with only gas seen in stomach, duodenum was hard to discern layering so suspicious of mass, and renal cysts. O opted to try meds before doing complete US. Presented 2/10/23, P vomits without Cerenia oral on board, only eating canned.
Abnormal PE/Chem/CBC/UA Results: Bloodwork done on 1/27/23 all WNL

ULTRASONOGRAPHIC EXAMINATION OF THE ABDOMEN

Urinary System

The **urinary bladder**, trigone, and pelvic urethra presented normal thicknesses and normal tone. The ureters were not visible which is normal. No uroliths or sediment were visualized and anechoic urine was present. No evidence of inflammatory or neoplastic changes was noted. Ureteral papillae were normal.

The **kidneys** revealed largely normal size and structure, corticomedullary definition and ratio (cortex 1/3 of medulla) were essentially maintained with some age-related loss of curvilinear patterns regarding the capsule and C/M junction. The cortices presented largely uniform texture with some increased echogenicity expected for his age patient. Medullary structure differed distinctly from that of the cortex. The right kidney revealed polycystic cortical changes that measured up to 1.5 cm. The right kidney measured 5.0 cm in length with slight pyelectasia. The caudal pole revealed a cystic lesion that measured 1.23 cm. Pinpoint mineralization was noted.

Adrenal Glands

Both **adrenal glands** were visualized and recognized as having normal shape, size, position and echogenicity for this breed. The phrenic vasculature, glandular echogenicity and detail were unremarkable. Capsule, cortex, and medullary definition were normal for this age patient. The left adrenal gland measured 0.4 cm at the cranial pole and 0.48 cm at the caudal pole.

Spleen

The **spleen** presented a smooth homogeneous parenchyma hyperechoic to liver and renal cortical parenchyma. The capsule was smooth without noticeable expansion or deviation from within the spleen or adjacent pathology. The splenic vasculature demonstrated normal volume without signs of congestion or thrombosis. No sonographic evidence of acute or chronic inflammatory, neoplastic, or infarctual changes was noted.

Liver

The **liver** was uniformly swollen with minor, excessive gallbladder debris and over distension with dependent and suspended bile without evidence of overt mucocele formation. However, excessive sludge was present. The liver presented coarse architecture with mildly increased portal markings and subtle, mixed echogenic changes. This is consistent with vacuolar hepatopathy and some level of remodeling and history of inflammatory component. There was no overt suspicion of neoplasia.

SonoPath
Clinical Sonography & Telecytology

EDUCATIONAL TELECONSULTATION SERVICES™

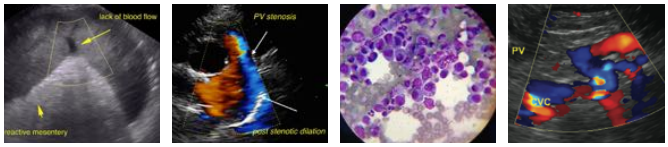

SonoPath.com™
1-800-838-4268 info@sonopath.com

PATIENT

Penny McDermott

SPECIES

Canine

BREED

Fox Terrier

SEX

Spayed female

AGE

10 years

WEIGHT

15.7 lbs

INTERPRETED BY

Eric Lindquist, DMV
DABVP, Cert. IVUSS

IMAGING PERFORMED BY

Christina

HOSPITAL NAME

Animal Health VC

REFERRING VET

Dr. Hughes

INVOICE

42713

DATE

2/10/23

Gastrointestinal

There was some residual chyme and gas was noted in the **stomach**, yet not pathological. This is consistent with end post prandial presentation. Transit of chyme into the small intestine was normal. Curvilinear patterns were maintained throughout the GI tract. No evidence of pathology. The pylorus was patent. Small and large intestine demonstrated normal luminal chyme and stool consistency respectively. No obstructive or overt infiltrative disease was noted. No associated abnormal lymphatic activity was noted.

Pancreas

Mild **pancreatic** remodeling was noted.

ULTRASONOGRAPHIC FINDINGS

Polycystic right kidney, minor degenerative changes.

Minor pancreatic remodeling.

Partial retention of ingesta, consistent with post prandial or delayed outflow issue.

INTERPRETATION OF THE FINDINGS & FURTHER RECOMMENDATIONS

There was no evidence of masses. 24-hour n.p.o., GI protectant protocol, hydrolyzed canned b.i.d. feedings and a clinical trial of the following can be considered. Otherwise, endoscopy is indicated. There was no evidence of foreign matter. The material in the stomach is most consistent with ingesta.

Part or all of this protocol may be considered based on your clinical impression of the patient:

Recommend pain management when anorexic with **Buprenorphine** (0.01-0.02 mg/kg IM or SC), clinical trial of **Zithromax** (50 mg sid/cat x 10 days, 3 weeks if bartonella +), **Prednisolone** (0.5-2 mg/kg tapering over 1 week to minimal effective dose), and **B12 injections** if weight loss (Cyanobalamine 250 mcg sub-q once-weekly x six weeks, then every other week for six weeks and then once-monthly, long-term if necessary), **novel-protein or hydrolyzed diet (***Hydrolyzed diets have been shown to be more effective in dietary intolerance case management compared to hypoallergenic diets***)** or the **magical Purina DM** (changing protein source is crucial and may need rotation every 6 months if clinical signs recur) Diet trials is a whatever works phenomenon. If vomiting becomes a persistent issue then endoscopy would be warranted and/or recheck sonogram to assess more emerging disease. One diet does not work for all patients so different trials may be necessary or protein source rotation every 6 months as new sensitivities develop.

SonoPath

Clinical Sonography & Telecytology

EDUCATIONAL TELECONSULTATION SERVICES™

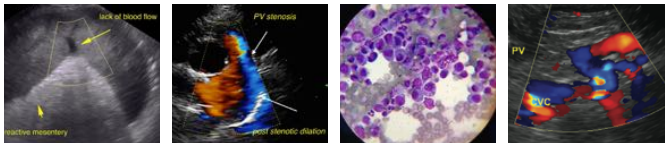

SonoPath.com™
1-800-838-4268 info@sonopath.com

PATIENT

Penny McDermott

SPECIES

Canine

BREED

Fox Terrier

SEX

Spayed female

AGE

10 years

WEIGHT

15.7 lbs

INTERPRETED BY

Eric Lindquist, DMV
DABVP, Cert. IVUSS

IMAGING PERFORMED BY

Christina

HOSPITAL NAME

Animal Health VC

REFERRING VET

Dr. Hughes

INVOICE

42713

DATE

2/10/23

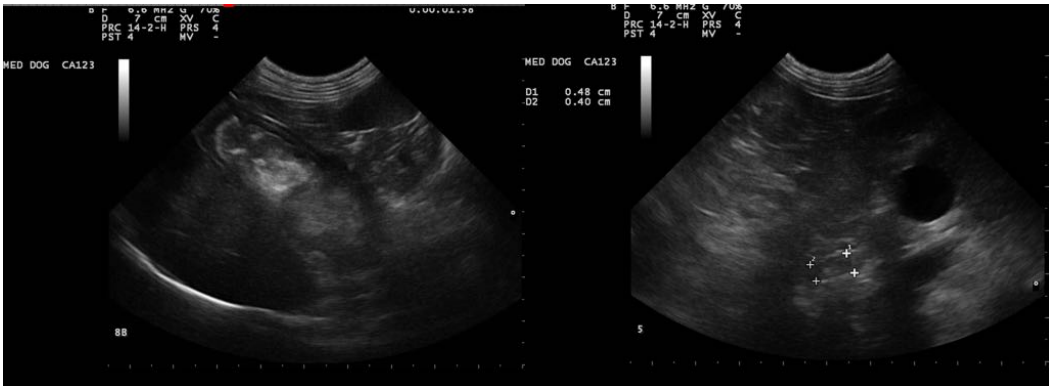

The information and recommendations provided are based on the images presented by the referring veterinarian/sonographer. No evaluation can be communicated regarding pathology that was not visible in the image/video clips provided.

Thank you for this referral. If the clinical or image interpretation does not parallel your findings or if I can be of any further assistance please contact me.

Eric Lindquist, DMV, DABVP, Cert. IVUSS, CEO of SonoPath.com
info@SonoPath.com