



PATIENT

Nova Walsh

PRESENTING CLINICAL SIGNS

Severe UTI, after spay at other hospital vomiting, severe abd inflammation.

SPECIES

Canine

ULTRASONOGRAPHIC EXAMINATION OF THE HEART & ABDOMEN

BREED

Bulldog

CANINE CARDIAC PARAMETERS	MR VMAX (m/s)	TR VMAX (m/s)	LA/AO (Boon method)	LA/AO (Heart Base; Swe)	FS (%)	EF (%)	EPSS (cm)
NORMAL PARAMETER	4.5-5.5	<2.7	1.3	<1.6	28-40	40-100	<0.6
PATIENT			NM	1.6			NM
CANINE CARDIAC PARAMETERS	HR (BPM)	AV VMAX (m/s)	PV MAX (m/s)	BODY WEIGHT (kg)	LA 2D short axis Base view (cm)	LVIDd Avg; 2D and m-mode short axis (cm)	LVIDs Avg; 2D and m-mode short axis (cm)
NORMAL PARAMETER	50-100	0.7-1.7	0.7-1.6	BELOW	BELOW	BELOW	BELOW
PATIENT		1.6	1.5				

SEX

Female

AGE

4

WEIGHT

41

INTERPRETED BY

Eric Lindquist, DMV

DABVP, Cert. IVUSS

IMAGING PERFORMED BY

Jenn

HOSPITAL NAME

Rockaway AH

REFERRING VET

Dr. Maniar

INVOICE

45038

DATE

2/10/23

Cardiac Presentation

The echocardiogram in this patient demonstrated normal **left atrial** size based on 3 separate methods of LA evaluation. The cranial and caudal **mitral** valve leaflets presented normal linear structure, extension in systole, and union in diastole with normal kinesis. The **left ventricle** revealed concentric hypertrophy. The **myocardium** presented normal echogenicity without subjective evidence of significant fibrotic or ischemic disease. **Contractility** of the ventricular walls was adequate and in normal range for this patient evidenced by the fractional shortening measurement and subjective evaluation of the different regions of the myocardium. The **left ventricular outflow** tract demonstrated normal laminar flow and subjective structural integrity. The **right atrium** and auricle revealed normal size, structure and content. No evidence of masses was noted. **Tricuspid** valvular assessment demonstrated adequate linear morphology and kinesis. The **right ventricle** was of normal size (1/3 diameter of LV), chordae structure, myocardial echogenicity and thickness. **Pulmonary outflow** tract assessment revealed normal valve structure, laminar flow, and diameter (approx. 1:1 pa/ao ratio). No visible **pericardial** or free pleura fluid was noted. The cranial **mediastinum and pericardial and extra-cardiac regions** were free of masses in the visible window. Occasional arrhythmia noted.

Urinary System

The **urinary bladder**, trigone, and pelvic urethra presented normal thicknesses and normal tone. The ureters were not visible which is normal. No uroliths or sediment were visualized and anechoic urine was present. No evidence of inflammatory or neoplastic changes were noted. Ureteral papillae were normal.

The **kidneys** revealed abnormal increased cortical echogenicity and hyperechoic medullary rim sign. Some loss of mural detail noted. The left kidney measured 7.0 cm. The right kidney measured 6.5 cm. Subnormal blood flow on power doppler assessment.



PATIENT

Nova Walsh

SPECIES

Canine

BREED

Bulldog

SEX

Female

AGE

4

WEIGHT

41

INTERPRETED BY

Eric Lindquist, DMV

DABVP, Cert. IVUSS

IMAGING PERFORMED BY

Jenn

HOSPITAL NAME

Rockaway AH

REFERRING VET

Dr. Maniar

INVOICE

45038

DATE

2/10/23

Adrenal Glands

The **left adrenal gland** was not visualized and was obscured by inflammation and pathology localized between the caudal aspect of the left kidney and the sublumber space.

The **right adrenal gland** was not visualized.

Spleen

The **spleen** presented a smooth homogeneous parenchyma hyperechoic to liver and renal cortical parenchyma. The capsule was smooth without noticeable expansion or deviation from within the spleen or adjacent pathology. The splenic vasculature demonstrated normal volume without signs of congestion or thrombosis. No sonographic evidence of acute or chronic inflammatory, neoplastic, or infarctual changes were noted.

Liver

The **liver** images submitted revealed subjectively normal liver size, contour, and structure. Parenchymal echogenicity was naturally coarse and hypoechoic to the spleen. Vascular and biliary tracts were of normal volume with no evidence of congestion. The gallbladder presented acceptably thin walls with primarily anechoic content. The cystic and common bile ducts were normal. No pathological hepatic lymphadenopathy was evident. No overt structural evidence of inflammatory, infiltrative or regenerative pathology was evident.

Gastrointestinal

Examination of the **gastrointestinal tract** revealed a stomach and intestine free of stasis, of normal wall thickness, acceptable curvilinear mural detail, and peristaltic activity. Small and large intestine demonstrated normal luminal chyme and stool consistency respectively. No obstructive or overt infiltrative disease was noted. No associated abnormal lymphatic activity was noted.

Pancreas

The base and limbs of the **pancreas** were observed to be largely isoechoic to surrounding omental fat. Pancreatic duct and capsular contour were acceptably normal and parenchyma respected normal curvilinear patterns. No overt evidence of active inflammatory or neoplastic disease was noted.

Free Abdomen

The mid abdomen revealed a mass with regional inflammation and distorted architecture, measuring approximately 3.0 cm. A sublumber hematoma was also noted.

ULTRASONOGRAPHIC FINDINGS

- Undifferentiated mass in the mid abdomen with sublumber hematoma, possibly left adrenal origin of the mass
- Chronic renal changes

INTERPRETATION OF THE FINDINGS & FURTHER RECOMMENDATIONS

Recommend abdominal CT for surgical planning and chest CT for assessment of metastatic disease. This may be granulomatous secondary to surgery. Blood pressure measurements recommended as well as EKG, given the arrhythmogenic activity and left ventricular hypertrophy.

SonoPath CT Services are offered at the [Blairstown Animal Hospital](#). Blairstown animal hospital is just a 30-minute drive west on route 80 from the route 80/287 interchange/Parsippany, New Jersey. More information can be found at:



PATIENT

Nova Walsh

<https://sonopath.com/resources/sonopaths-teleconsultation-services-and-sdep-certification/sonopath-ct-services>

SPECIES

Canine

BREED

Bulldog

SEX

Female

AGE

4

WEIGHT

41

INTERPRETED BY

Eric Lindquist, DMV

DABVP, Cert. IVUSS

IMAGING PERFORMED BY

Jenn

HOSPITAL NAME

Rockaway AH

REFERRING VET

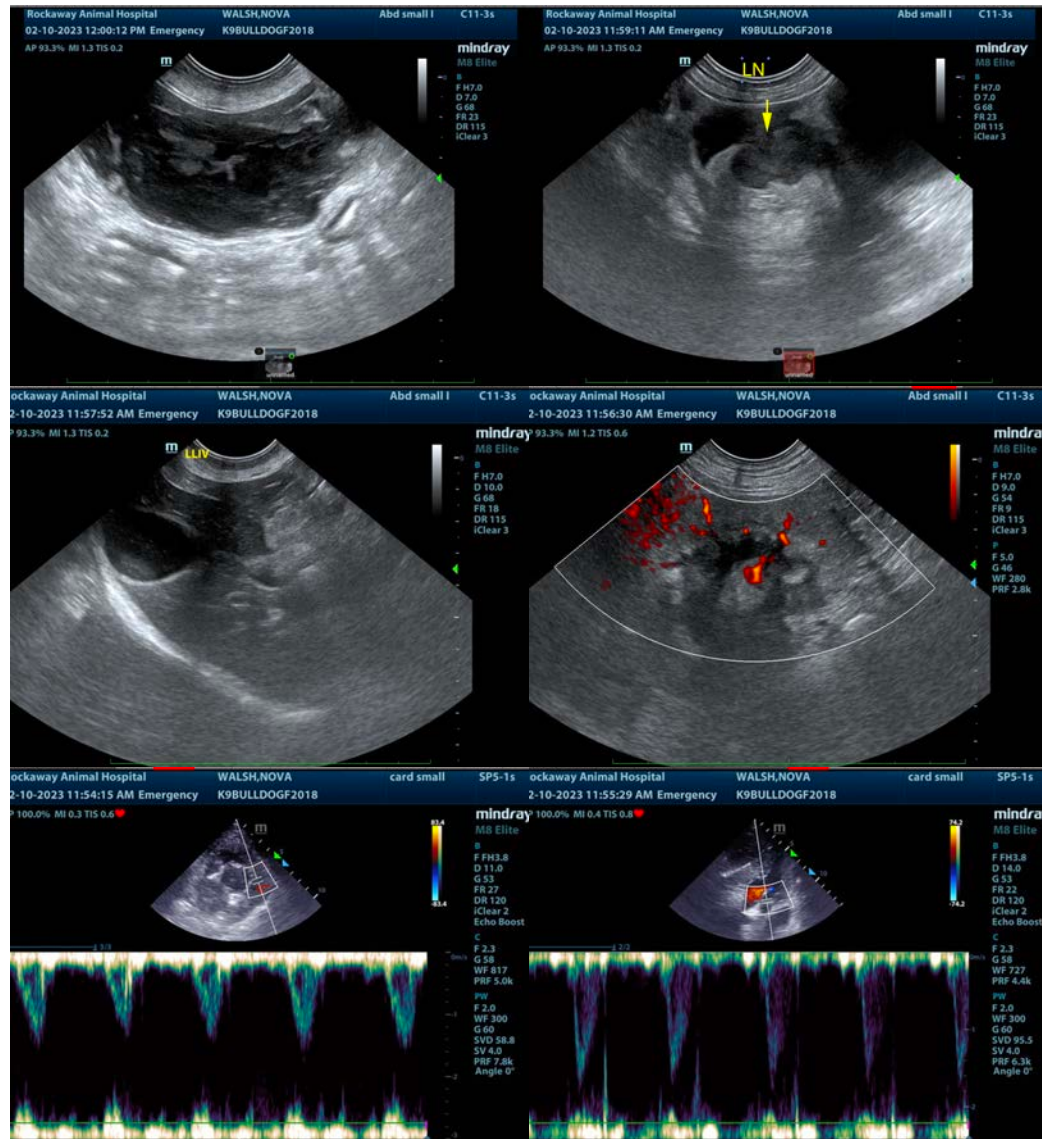
Dr. Maniar

INVOICE

45038

DATE

2/10/23





PATIENT

Nova Walsh

SPECIES

Canine

BREED

Bulldog

SEX

Female

AGE

4

WEIGHT

41

INTERPRETED BY

Eric Lindquist, DMV

DABVP, Cert. IVUSS

IMAGING PERFORMED BY

Jenn

HOSPITAL NAME

Rockaway AH

REFERRING VET

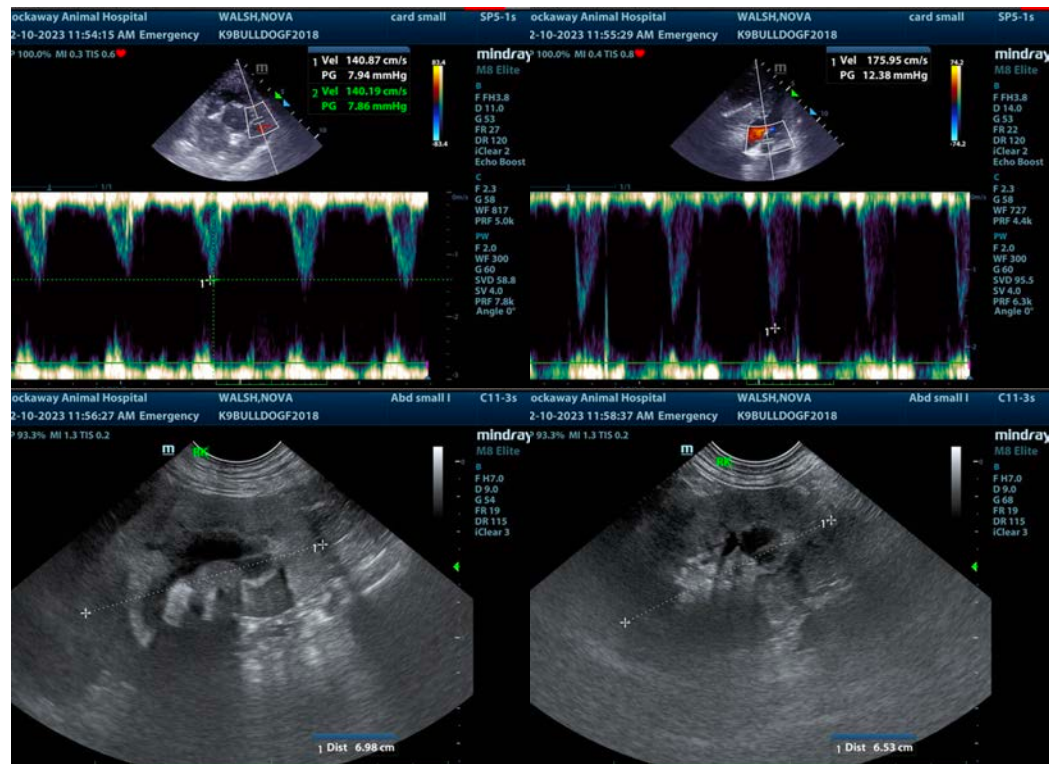
Dr. Maniar

INVOICE

45038

DATE

2/10/23



The information and recommendations provided are based on the images presented by the referring veterinarian/sonographer. No evaluation can be communicated regarding pathology that was not visible in the image/video clips provided.

Thank you for this referral. If the clinical or image interpretation does not parallel your findings or if I can be of any further assistance please contact me.

Eric Lindquist, DMV, DABVP, Cert. IVUSS, CEO of SonoPath.com

info@SonoPath.com