SonoPath
Clinical Sonography & Telecytology

EDUCATIONAL TELECONSULTATION SERVICES™

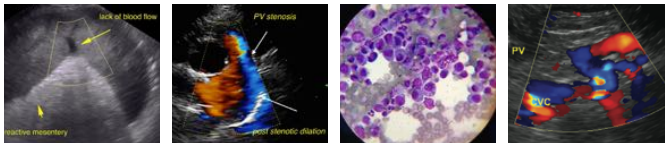

SonoPath.com™
1-800-838-4268 info@sonopath.com

PATIENT
Daisy Bender

SPECIES
Feline

BREED
Domestic Shorthair

SEX
Spayed female

AGE
5 years

WEIGHT
5.4 lbs

INTERPRETED BY
Eric Lindquist, DMV
DABVP, Cert. IVUSS

IMAGING PERFORMED BY
Jenn

HOSPITAL NAME
Rockaway AH

REFERRING VET
Dr. Maniar

INVOICE
42687

DATE
2/10/23

PRESENTING CLINICAL SIGNS

History: presented for not eating since dental

ULTRASONOGRAPHIC EXAMINATION OF THE ABDOMEN

Urinary System

The **urinary bladder**, trigone, and pelvic urethra presented normal thicknesses and normal tone. The ureters were not visible which is normal. No uroliths or sediment were visualized and anechoic urine was present. No evidence of inflammatory or neoplastic changes was noted. Ureteral papillae were normal.

The **kidneys** revealed normal size and structure, corticomedullary definition and ratio for this age. The cortices presented largely uniform texture with normal echogenic relationship to liver and spleen. Medullary structure differed distinctly from the cortex and no evidence of pelvic dilation was present. The capsules were acceptably uniform without significant irregularities. The left kidney measured 3.37 cm. The right kidney measured 3.61 cm.

Adrenal Glands

Both **adrenal glands** were visualized and recognized as having normal shape, size, position and echogenicity for this breed. The phrenic vasculature, glandular echogenicity and detail were unremarkable. Capsule, cortex, and medullary definition were normal for this age patient.

Spleen

The **spleen** in this patient was uniform, yet volume contracted. Hydration status should be assessed.

Liver

The **liver** was diffusely hyperechoic to the falciform fat. The gallbladder and common bile duct were unremarkable. This is most consistent with lipidosis.

Gastrointestinal

Examination of the **gastrointestinal tract** revealed a stomach and intestine free of stasis, of normal wall thickness, acceptable curvilinear mural detail, and peristaltic activity. Small and large intestine demonstrated normal luminal chyme and stool consistency respectively. No obstructive or overt infiltrative disease was noted. No associated abnormal lymphatic activity was noted.

SonoPath
Clinical Sonography & Telecytology

EDUCATIONAL TELECONSULTATION SERVICES™

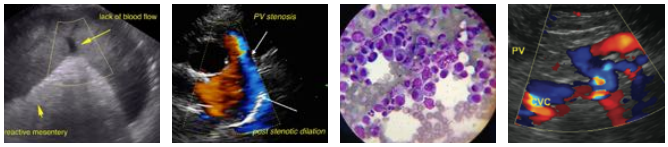

SonoPath.com™
1-800-838-4268 info@sonopath.com

PATIENT
Daisy Bender

SPECIES
Feline

BREED
Domestic Shorthair

SEX
Spayed female

AGE
5 years

WEIGHT
5.4 lbs

INTERPRETED BY
Eric Lindquist, DMV DABVP, Cert. IVUSS

IMAGING PERFORMED BY
Jenn

HOSPITAL NAME
Rockaway AH

REFERRING VET
Dr. Maniar

INVOICE
42687

DATE
2/10/23

Pancreas

The base and limbs of the **pancreas** were observed to be largely isoechoic to surrounding omental fat. Pancreatic duct and capsular contour were acceptably normal and parenchyma respected normal curvilinear patterns. No overt evidence of active inflammatory or neoplastic disease was noted.

ULTRASONOGRAPHIC EXAMINATION OF THE HEART

The echocardiogram in this patient demonstrated normal **left atrial** size based on 3 separate methods of LA evaluation. The cranial and caudal **mitral** valve leaflets presented normal linear structure, extension in systole, and union in diastole with normal kinesis. The **left ventricle** presented thicknesses with linear contour and was not dilated nor restricted. The **myocardium** presented normal echogenicity without subjective evidence of significant fibrotic or ischemic disease. **Contractility** of the ventricular walls was adequate and in normal range for this patient evidenced by the fractional shortening measurement and subjective evaluation of the different regions of the myocardium. The **left ventricular outflow** tract demonstrated normal laminar flow and subjective structural integrity. The **right atrium** and auricle revealed normal size, structure and content. No evidence of masses was noted. **Tricuspid** valvular assessment demonstrated adequate linear morphology and kinesis. The **right ventricle** was of normal size (1/3 diameter of LV), chordae structure, myocardial echogenicity and thickness. **Pulmonary outflow** tract assessment revealed normal valve structure, laminar flow, and diameter (approx.1:1 pa/ao ratio). No visible **pericardial** or free pleura fluid was noted. The cranial **mediastinum and pericardial and extra-cardiac regions** were free of masses in the visible window.

CANINE CARDIAC PARAMETERS	MR VMAX (m/s)	TR VMAX (m/s)	LA/AO (Boon method)	LA/AO (Heart Base;)	FS (%)	EF (%)	EPSS (cm)
NORMAL PARAMETER	4.5-5.5	<2.7	1.3	<1.6	28-40	40-100	<0.6
PATIENT			1.34	1.2	40		0.1
CANINE CARDIAC PARAMETERS	**HR** (BPM)	**AV VMAX** (m/s)	**PV MAX** (m/s)	**BODY WEIGHT** (kg)	**LA** 2D short axis Base view (cm)	**LVIDd** Avg; 2D and m-mode short axis (cm)	**LVIDs** Avg; 2D and m-mode short axis (cm)
NORMAL PARAMETER	50-100	0.7-1.7	0.7-1.6	BELOW	BELOW	BELOW	BELOW
PATIENT			0.5	15	1.2	0.5	

ULTRASONOGRAPHIC FINDINGS

Normal echocardiogram.

Hyperechoic liver.

Volume contracted spleen.

Otherwise, unremarkable abdomen.

SonoPath
Clinical Sonography & Telecytology
EDUCATIONAL TELECONSULTATION SERVICES™

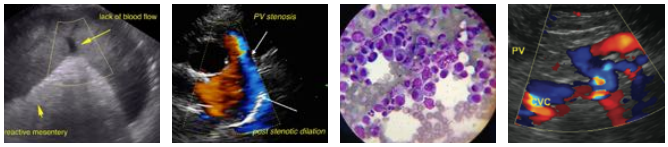

SonoPath.com™
1-800-838-4268 info@sonopath.com

PATIENT

Daisy Bender

SPECIES

Feline

BREED

Domestic Shorthair

SEX

Spayed female

AGE

5 years

WEIGHT

5.4 lbs

INTERPRETED BY

Eric Lindquist, DMV
DABVP, Cert. IVUSS

IMAGING PERFORMED BY

Jenn

HOSPITAL NAME

Rockaway AH

REFERRING VET

Dr. Maniar

INVOICE

42687

DATE

2/10/23

INTERPRETATION OF THE FINDINGS & FURTHER RECOMMENDATIONS

There was no evidence of pathology related to the clinical signs. Hydration status should be evaluated in this patient. If liver enzyme elevations are present then 25-gauge FNA is indicated. There is a potential hepatic lipidosis. There was no other evidence of pathology related to the clinical history.

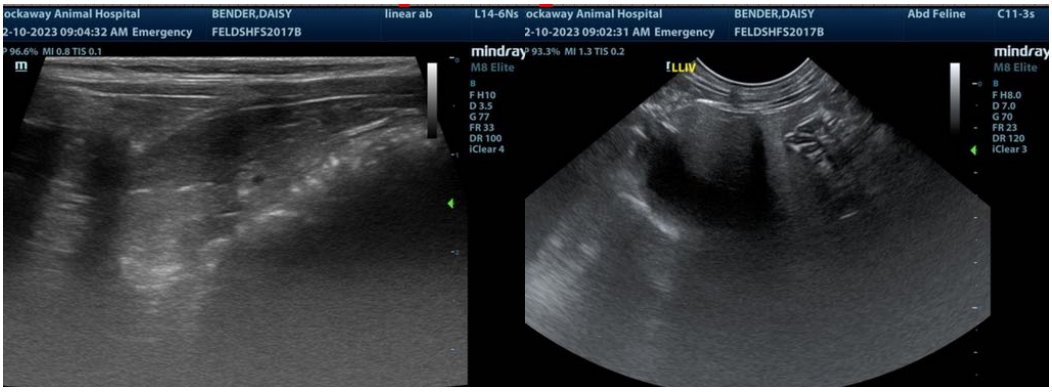

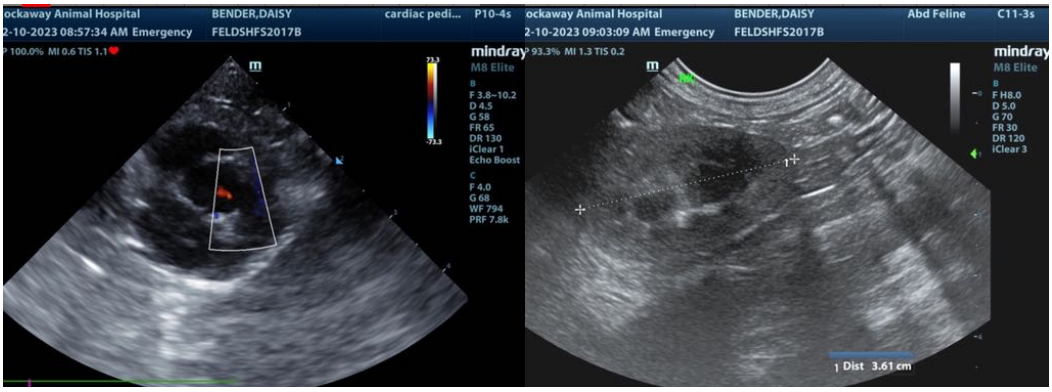

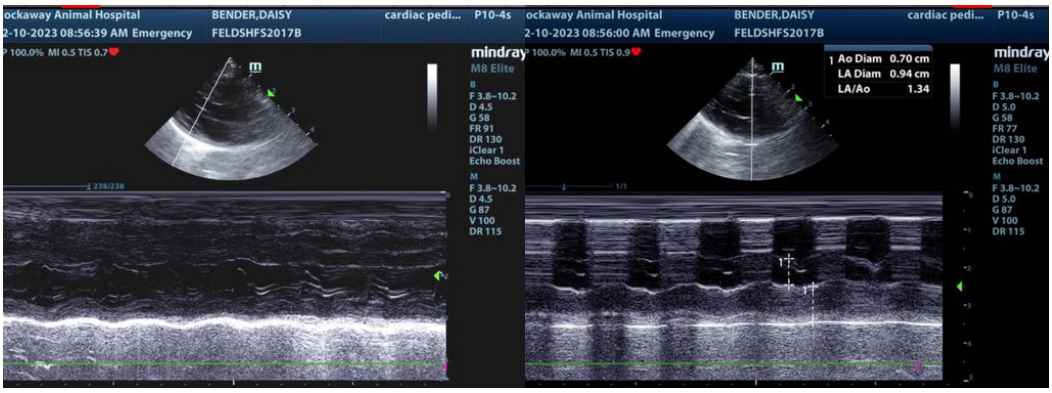

SonoPath
Clinical Sonography & Telecytology

EDUCATIONAL TELECONSULTATION SERVICES™

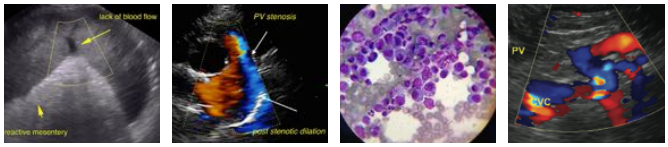

SonoPath.com™
1-800-838-4268 info@sonopath.com

PATIENT

Daisy Bender

SPECIES

Feline

BREED

Domestic Shorthair

SEX

Spayed female

AGE

5 years

WEIGHT

5.4 lbs

INTERPRETED BY

Eric Lindquist, DMV
DABVP, Cert. IVUSS

IMAGING PERFORMED BY

Jenn

HOSPITAL NAME

Rockaway AH

REFERRING VET

Dr. Maniar

INVOICE

42687

DATE

2/10/23

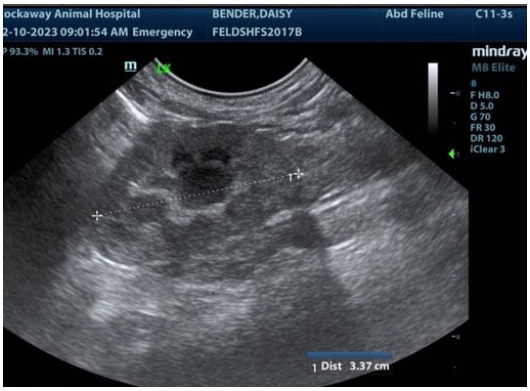

The information and recommendations provided are based on the images presented by the referring veterinarian/sonographer. No evaluation can be communicated regarding pathology that was not visible in the image/video clips provided.

Thank you for this referral. If the clinical or image interpretation does not parallel your findings or if I can be of any further assistance please contact me.

Eric Lindquist, DMV, DABVP, Cert. IVUSS, CEO of SonoPath.com
info@SonoPath.com