

**DATE**

2/10/23

**PRESENTING CLINICAL SIGNS**

Presented for weight loss. History of vomiting, improved with home cooked diet. Lab work showed elevated liver enzymes.

**PATIENT**

Chelsea Croucher

Current Medications: 1/30 Amoxi 150mg BID, Metro 125mg BID, Denamarin Advanced.

Lab Results: ALT 888, ALKP 299, GGT 19.

Date of Previous IntraPet Ultrasound: No previous.

**SPECIES**

Canine

Sedation: Not required to complete full diagnostic ultrasound.

Stat Report: Not requested.

Imaging Performed By: Rachel Brillhart, RDMS.

**BREED**

Bichon Frise X

**ULTRASONOGRAPHIC EXAMINATION OF THE ABDOMEN****Urinary System****SEX**

Spayed Female

The **urinary bladder**, trigone, and pelvic urethra presented normal thicknesses and normal tone. The ureters were not visible which is normal. No uroliths or sediment were visualized and anechoic urine was present. No evidence of inflammatory or neoplastic changes were noted. Ureteral papillae were normal.

**AGE**

11/1/09

The **kidneys** revealed normal size and structure, corticomedullary definition and ratio for this age. The cortices presented largely uniform texture with normal echogenic relationship to liver and spleen. Medullary structure differed distinctly from the cortex and no evidence of pelvic dilation was present. The capsules were acceptably uniform without significant irregularities. The left kidney measured 3.93 cm with an anechoic cyst of 0.26 cm and slight pinpoint mineralizations noted. The right kidney measured 4.31 cm.

**WEIGHT**

16 Pounds

**Adrenal Glands****INTERPRETED BY**Eric Lindquist, DMV  
DABVP, Cert. IVUSS

Both **adrenal glands** were visualized and recognized as having normal shape, size, position and echogenicity for this breed. The phrenic vasculature, glandular echogenicity and detail were unremarkable. Capsule, cortex, and medullary definition were normal for this age patient. The left adrenal gland measured 2.07 cm x 0.54 cm at the cranial pole and 0.55 cm at the caudal pole. The right adrenal gland measured 1.82 cm x 0.80 cm at the cranial pole and 0.63 cm at the caudal pole.

**HOSPITAL NAME**

Hickory Vet Hospital

**Spleen**

The **spleen** presented subtle micronodular changes up to 0.38 cm, fairly uniform parenchyma otherwise. Vascularity appeared normal.

**REFERRING VET**

Dr. Lyle

**Liver**

The **liver** was uniformly swollen with minor, excessive gallbladder debris and over distension with dependent and suspended bile without evidence of overt mucocele formation. However, excessive sludge was present. The liver presented coarse architecture with mildly increased portal markings and subtle, mixed echogenic changes. This is consistent with vacuolar hepatopathy and some level of remodeling and history of inflammatory component. There was no overt suspicion of neoplasia. Micronodular changes noted, non-disruptive.

**INVOICE**

45070

**Gastrointestinal**

Examination of the **gastrointestinal tract** revealed a stomach and intestine free of stasis, of normal wall thickness, acceptable curvilinear mural detail, and peristaltic activity. Small and large intestine demonstrated normal luminal chyme and stool consistency respectively. No obstructive or overt infiltrative disease was noted. No associated abnormal lymphatic activity was noted.

## Pancreas

The base and limbs of the **pancreas** were observed to be largely isoechoic to surrounding omental fat. Some parenchymal remodeling, however, with mild deviation from curvilinear normalcy was observed. Pancreatic duct and capsular irregularities were present consistent with age related changes. If pain upon imaging (+ Murphy sign) was present or if the patient is focally painful in subxyphoid palpation then low-grade smoldering chronic pancreatitis should be suspected.

## Free Abdomen

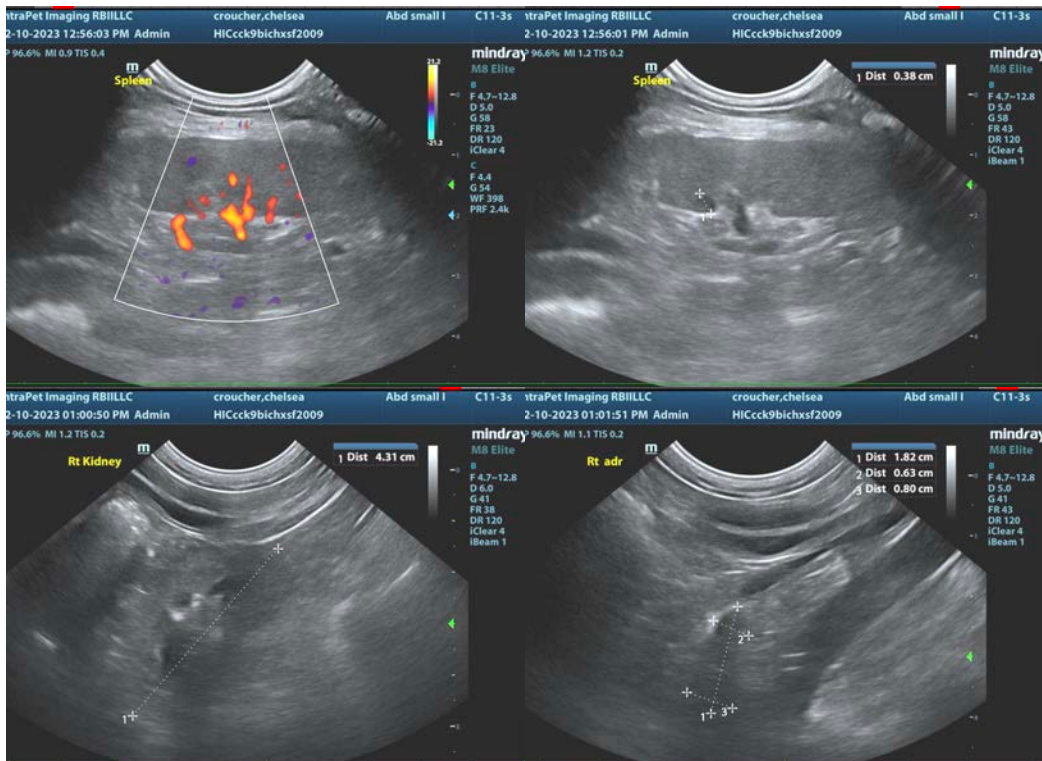
Rapid view of the heart revealed no evident pathology.

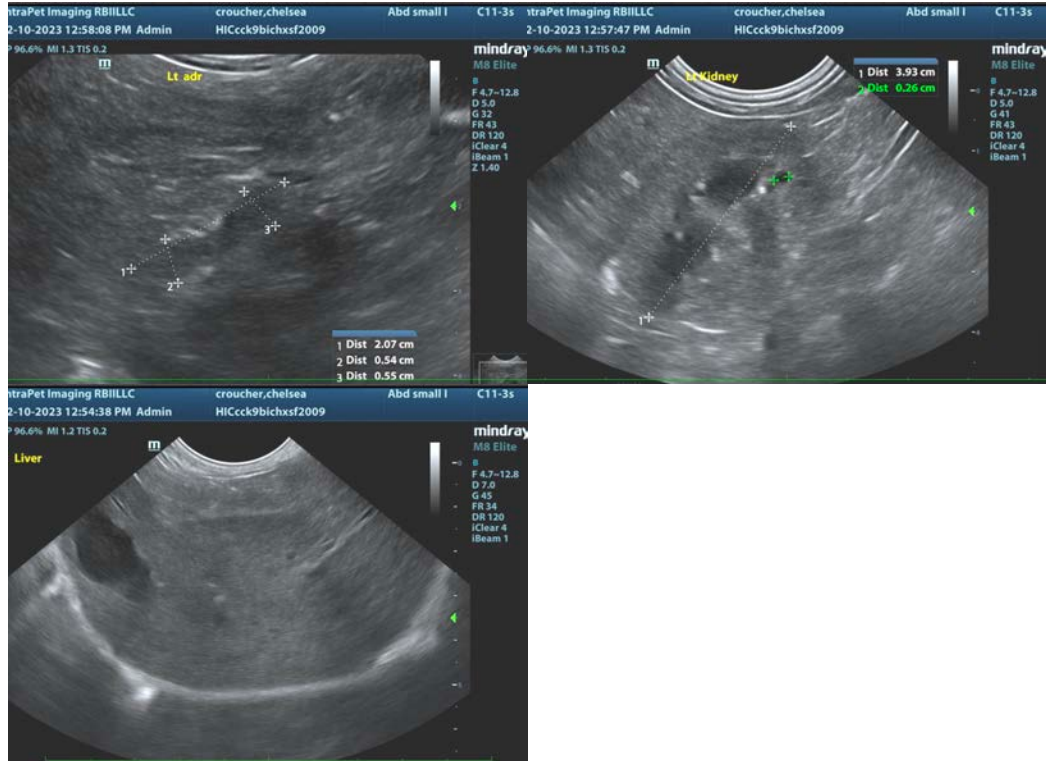
## ULTRASONOGRAPHIC FINDINGS

- Pinpoint renal mineralizations
- Undefined splenic and hepatic nodular changes
- Age related pancreatic changes

## INTERPRETATION OF THE FINDINGS & FURTHER RECOMMENDATIONS

Splenic and hepatic changes are likely benign, yet FNA ideal, especially given the weight loss to rule out emerging round cell neoplasia. Otherwise, supportive care warranted. Maldigestion panel, three view chest radiographs and full CNS examination is recommended to examine for occult disease that could be responsible for the weight loss. Evaluation for competitive eating environments should also be considered.





The information and recommendations provided are based on the images presented by the referring veterinarian/sonographer. No evaluation can be communicated regarding pathology that was not visible in the image/video clips provided.

Thank you for this referral. If the clinical or image interpretation does not parallel your findings or if I can be of any further assistance please contact me.

**Eric Lindquist**, DMV, DABVP, Cert. IVUSS, CEO of SonoPath.com  
[info@SonoPath.com](mailto:info@SonoPath.com)