SonoPath
Clinical Sonography & Telecytology

EDUCATIONAL TELECONSULTATION SERVICES™

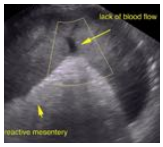

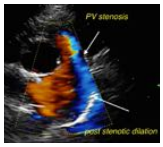

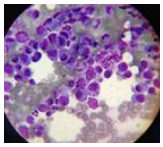
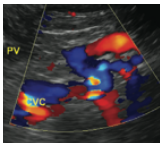

SonoPath.com™
1-800-838-4268 info@sonopath.com

PATIENT
Bella Goddard

SPECIES
Feline

BREED
Domestic Shorthair

SEX
Spayed female

AGE
11 years

WEIGHT
9.3 lbs

INTERPRETED BY
Eric Lindquist, DMV
DABVP, Cert. IVUSS

IMAGING PERFORMED BY
Dr. Griffin

HOSPITAL NAME
Northside VC

REFERRING VET
Dr. Griffin

INVOICE
42712

DATE
2/10/23

PRESENTING CLINICAL SIGNS

History: Chronic IBD that was managed with pred, recently became diabetic and MedVet switched from pred to budesamide, dewormed due to chronic high eos
Abnormal PE/Chem/CBC/UA Results: PE: Severe diabetic neuropathy, sarcopenia , abdominal distension CBC: WBC 57%, Neu 26, lym 7.88, Mono, 1.83, Eos 16 Fecal: Negative CHEM:Glucose 478,Crea 0.6,BUN 14 U/A: cystocentesis WBC >50, RBC <1. Rods and Cocci present, Protein 30 mg/dL, Glucose 1000 mg/dL, Bld 10

ULTRASONOGRAPHIC EXAMINATION OF THE ABDOMEN

Urinary System

The **urinary bladder**, trigone, and pelvic urethra presented normal thicknesses and normal tone. The ureters were not visible which is normal. No uroliths or sediment were visualized and anechoic urine was present. No evidence of inflammatory or neoplastic changes was noted. Ureteral papillae were normal.

The **kidneys** are irregular in contour with cortical infarcts that are at the upper limits of normal in size. Thickened irregular cortices were noted. The right kidney measured 4.1 cm. The left kidney measured 3.6 cm.

Adrenal Glands

Both **adrenal glands** were visualized and recognized as having normal shape, size, position and echogenicity for this breed. The phrenic vasculature, glandular echogenicity and detail were unremarkable. Capsule, cortex, and medullary definition were normal for this age patient.

Spleen

The **spleen** presented a smooth homogeneous parenchyma hyperechoic to liver and renal cortical parenchyma. The capsule was smooth without noticeable expansion or deviation from within the spleen or adjacent pathology. The splenic vasculature demonstrated normal volume without signs of congestion or thrombosis. No sonographic evidence of acute or chronic inflammatory, neoplastic, or infarctual changes was noted.

Liver

The **liver** was mildly enlarged with slightly coarse architecture. The gallbladder and common bile duct were unremarkable.

Gastrointestinal

The **gastrointestinal** presentation revealed mild uniform prominence of the gastric mucosa as well as areas of "ropey" small intestinal wall with slight disruption of the normal 1:3 muscularis/mucosal ratio. The intestinal submucosa was slightly irregular, thickened and hyperechoic suggestive of low grade,

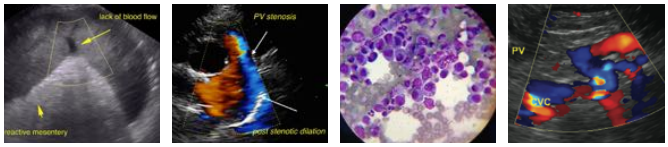

SonoPath.com
1-800-838-4268 info@sonopath.com

PATIENT

Bella Goddard

SPECIES

Feline

BREED

Domestic Shorthair

SEX

Spayed female

AGE

11 years

WEIGHT

9.3 lbs

INTERPRETED BY

Eric Lindquist, DMV
DABVP, Cert. IVUSS

IMAGING PERFORMED BY

Dr. Griffin

HOSPITAL NAME

Northside VC

REFERRING VET

Dr. Griffin

INVOICE

42712

DATE

2/10/23

chronic disease. The mesenteric lymph nodes are enlarged, hypoechoic, rounded and peripherally inflamed. The architecture was distorted and measured up to 2.7 cm. The cluster of lymph nodes measures 3.7 x 2.7 cm.

Pancreas

The base and limbs of the **pancreas** were observed to be largely isoechoic to surrounding omental fat. Pancreatic duct and capsular contour were acceptably normal and parenchyma respected normal curvilinear patterns. No overt evidence of active inflammatory or neoplastic disease was noted.

Free Abdomen

Reactive mesentery was noted associated with the intestinal tract.

ULTRASONOGRAPHIC FINDINGS

Mesenteric lymph node mass.

Diffuse intestinal thickening.

Regional enlarged lymph nodes.

Hepatic enlargement.

INTERPRETATION OF THE FINDINGS & FURTHER RECOMMENDATIONS

Given the history in this patient partially suppressed lymphoma is likely. FNA of the lymph nodes and liver is recommended for staging purposes. Treatment for UTI is warranted given the pyuria over a 4 week period is recommended. There is a potential that the lymphoma pattern may also be in the kidneys given minor, irregular contour.

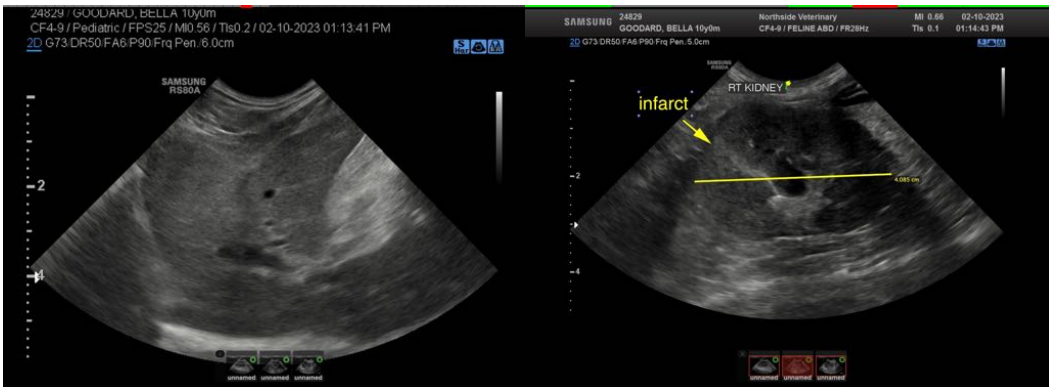

SonoPath

Clinical Sonography & Telecytology

EDUCATIONAL TELECONSULTATION SERVICES™

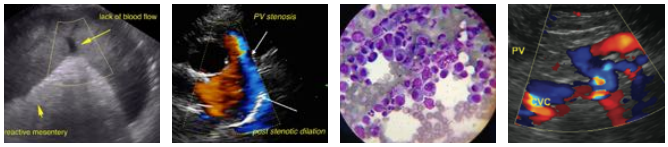

SonoPath.com™
1-800-838-4268 info@sonopath.com

PATIENT

Bella Goddard

SPECIES

Feline

BREED

Domestic Shorthair

SEX

Spayed female

AGE

11 years

WEIGHT

9.3 lbs

INTERPRETED BY

Eric Lindquist, DMV
DABVP, Cert. IVUSS

IMAGING PERFORMED BY

Dr. Griffin

HOSPITAL NAME

Northside VC

REFERRING VET

Dr. Griffin

INVOICE

42712

DATE

2/10/23

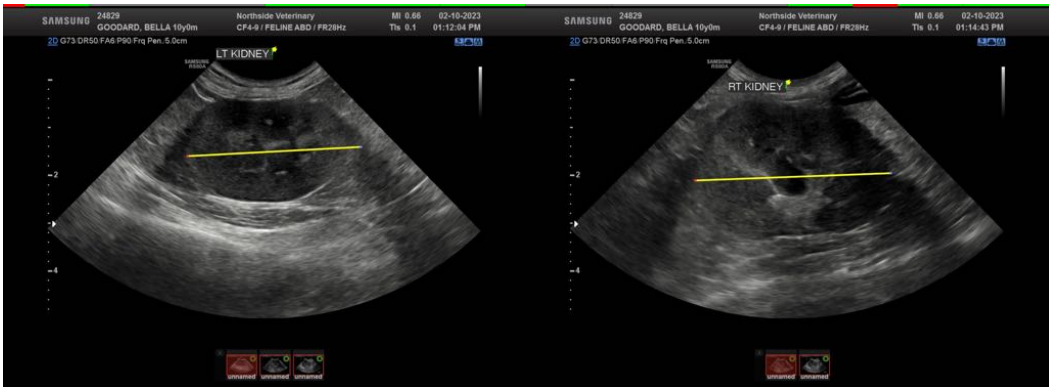

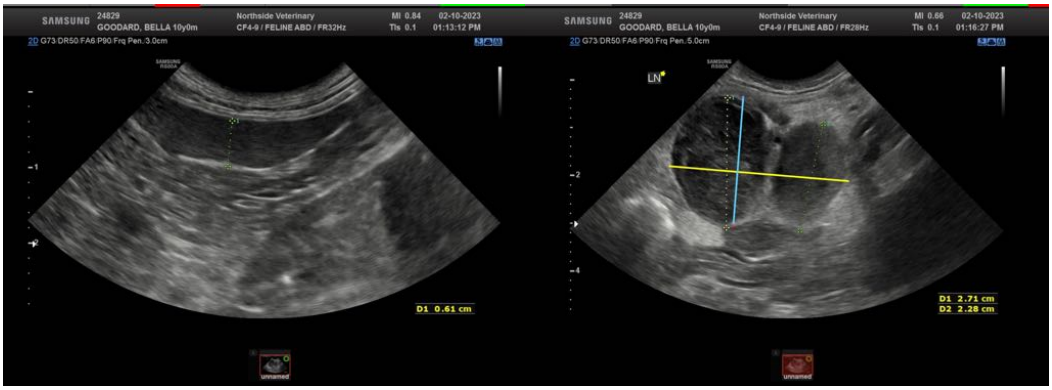

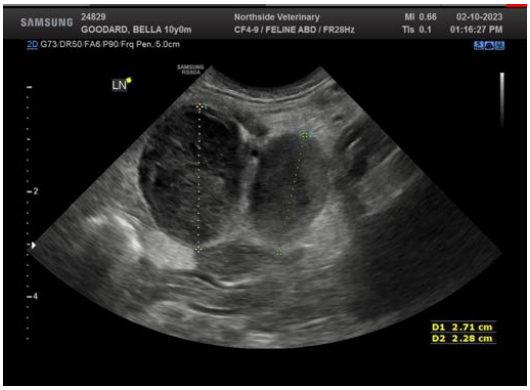

The information and recommendations provided are based on the images presented by the referring veterinarian/sonographer. No evaluation can be communicated regarding pathology that was not visible in the image/video clips provided.

Thank you for this referral. If the clinical or image interpretation does not parallel your findings or if I can be of any further assistance please contact me.

Eric Lindquist, DMV, DABVP, Cert. IVUSS, CEO of SonoPath.com
info@SonoPath.com