SonoPath
Clinical Sonography & Telecytology

EDUCATIONAL TELECONSULTATION SERVICES™

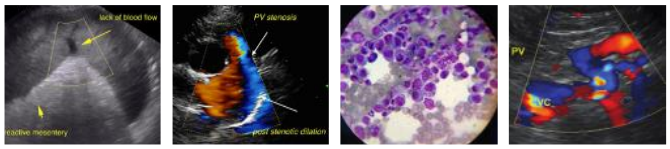

SonoPath.com
1-800-838-4268 info@sonopath.com

PATIENT

Zoey Penrod

SPECIES

Canine

BREED

Yorkie

SEX

Spayed Female

AGE

8 Years

WEIGHT

3.1 kg

INTERPRETED BY

Eric Lindquist, DMV
DABVP, Cert. IVUSS

IMAGING PERFORMED BY

Dr. Hayley Biederbeck

HOSPITAL NAME

Lomsnes VH

REFERRING VET

Dr. Hayley Biederbeck

INVOICE

13871

DATE

2/10/22

PRESENTING CLINICAL SIGNS

History: Ultrasound for neighboring vet clinic. Chronically elevated liver values, getting worse. Clinically doing well. Is on liver complete and dental diet

Abnormal PE/Chem/CBC/UA Results: ALT 201 (10-118), in 2018 ALT was 137. BUN 29 (7-25) . tbili, alkp, albumin, glc normal. Bile acids-pre-normal. Post elevated - 69.6 (0-29.9)

ULTRASONOGRAPHIC EXAMINATION OF THE ABDOMEN

Urinary System

The **urinary bladder**, trigone, and pelvic urethra presented normal thicknesses and normal tone. The ureters were not visible which is normal. No uroliths or sediment were visualized and anechoic urine was present. No evidence of inflammatory or neoplastic changes were noted. Ureteral papillae were normal.

The **kidneys** revealed normal size and structure, corticomedullary definition and ratio for this age. The cortices presented largely uniform texture with normal echogenic relationship to liver and spleen. Medullary structure differed distinctly from the cortex and no evidence of pelvic dilation was present. The capsules were acceptably uniform without significant irregularities. The right kidney measured 3.0 cm. The left kidney measured 3.0 cm.

Adrenal Glands

Both **adrenal glands** were visualized and recognized as having normal shape, size, position and echogenicity for this breed. The phrenic vasculature, glandular echogenicity and detail were unremarkable. Capsule, cortex, and medullary definition were normal for this age patient. The right adrenal gland measured 4.0 mm. The left adrenal gland measured 4.0 mm.

Spleen

The **spleen** presented a smooth homogeneous parenchyma hyperechoic to liver and renal cortical parenchyma. The capsule was smooth without noticeable expansion or deviation from within the spleen or adjacent pathology. The splenic vasculature demonstrated normal volume without signs of congestion or thrombosis. No sonographic evidence of acute or chronic inflammatory, neoplastic, or infarctual changes were noted. Caudal folding of the spleen was noted.

Liver

The **liver** was normal in size and contour. Minor coarse architecture and mild increased portal markings were noted in the liver. Minor striating gallbladder debris was noted.

Gastrointestinal

Examination of the **gastrointestinal tract** revealed a stomach and intestine free of stasis, of normal wall thickness, acceptable curvilinear mural detail, and peristaltic activity. Small and large intestine demonstrated normal luminal chyme and stool consistency respectively. No obstructive or overt infiltrative disease was noted. No associated abnormal lymphatic activity was noted.

Pancreas

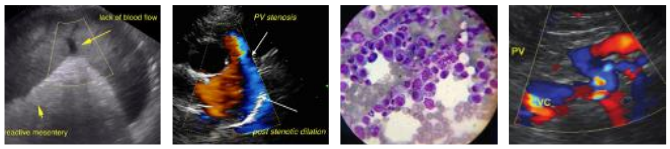

SonoPath.com
1-800-838-4268 info@sonopath.com

PATIENT

Zoey Penrod

SPECIES

Canine

BREED

Yorkie

SEX

Spayed Female

AGE

8 Years

WEIGHT

3.1 kg

INTERPRETED BY

Eric Lindquist, DMV
DABVP, Cert. IVUSS

IMAGING PERFORMED BY

Dr. Hayley Biederbeck

HOSPITAL NAME

Lomsnes VH

REFERRING VET

Dr. Hayley Biederbeck

INVOICE

13871

DATE

2/10/22

The base and limbs of the **pancreas** were observed to be largely isoechoic to surrounding omental fat. Pancreatic duct and capsular contour were acceptably normal and parenchyma respected normal curvilinear patterns. No overt evidence of active inflammatory or neoplastic disease was noted.

ULTRASONOGRAPHIC FINDINGS

- Nonspecific inflammatory hepatopathy
- Minor excessive gallbladder debris, not to the level of mucocele formation
- Splenic fold

INTERPRETATION OF THE FINDINGS & FURTHER RECOMMENDATIONS

FNA of the liver warranted to assess any inflammatory cell type. Ursodiol therapy also indicated. A clinical trial of the following may prove effective. Portal hypoplasia/microvascular dysplasia possible. No evidence of portosystemic shunting.

Hepatic Support for Bile Acid Elevation +/- Hepatic Encephalopathy

Royal Canin Hepatic Support diet or Hills L/D, **Metronidazole** (7.5 mg/kg PO bid) over the next 14 days, **Lactulose** (Oral: 3.1-3.7 g/5 ml lactulose in a syrup base) long term to target 2-3 soft stools/day, with a **high-quality protein supplement** of minor amount of **yogurt** or **cheddar cheese**. Monitor bile acids, with attention paid to dropping albumin, BUN or cholesterol. SAMe and nutraceuticals as needed. **Ursodiol (**10-15 mg/kg p.o. q24h) can be considered as hepatoprotectant and to enhance bile flow. **Zinc** serum level keep between 200—500 ug/dl. If deficient then Tx zinc acetate 1-3 mg/kg/day. Gastrointestinal protectants are recommended if the patient is anorexic.

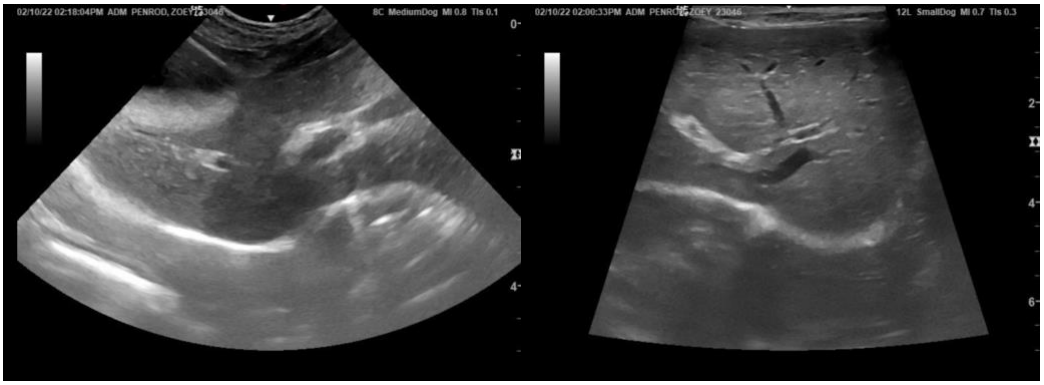

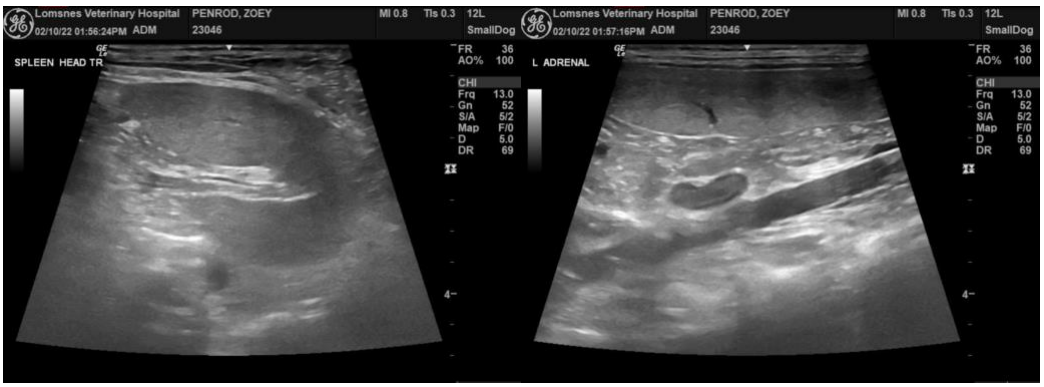

SonoPath
Clinical Sonography & Telecytology

EDUCATIONAL TELECONSULTATION SERVICES™

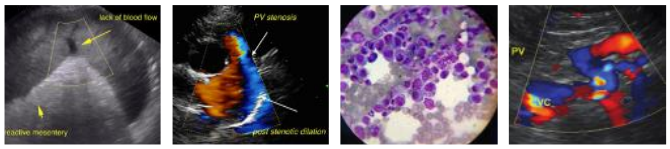

SonoPath.com
1-800-838-4268 info@sonopath.com

PATIENT

Zoey Penrod

SPECIES

Canine

BREED

Yorkie

SEX

Spayed Female

AGE

8 Years

WEIGHT

3.1 kg

INTERPRETED BY

Eric Lindquist, DMV
DABVP, Cert. IVUSS

IMAGING PERFORMED BY

Dr. Hayley Biederbeck

HOSPITAL NAME

Lomsnes VH

REFERRING VET

Dr. Hayley Biederbeck

INVOICE

13871

DATE

2/10/22

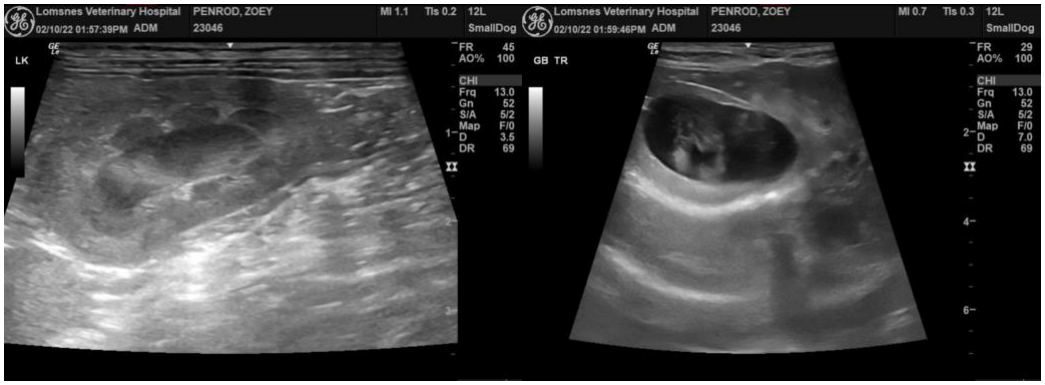

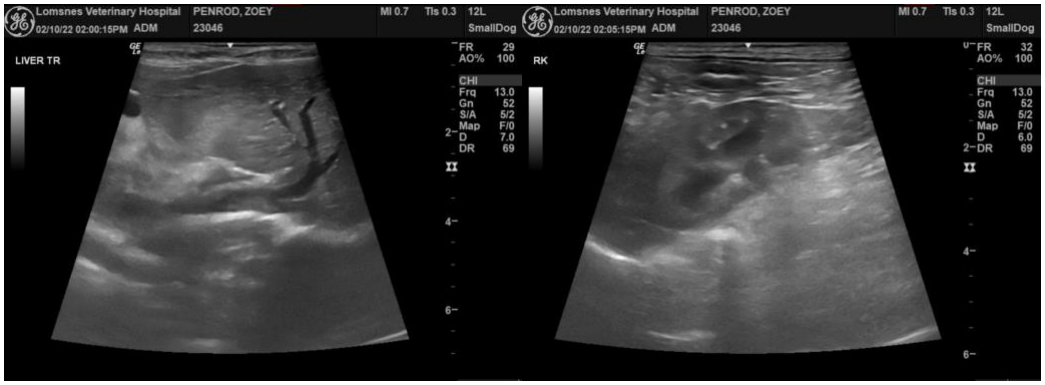

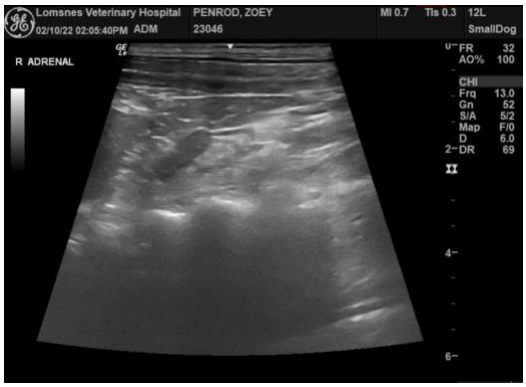

The information and recommendations provided are based on the images presented by the referring veterinarian. No evaluation can be communicated regarding pathology that was not visible in the image/video clips provided.

Thank you for this referral. If the clinical or image interpretation does not parallel your findings or if I can be of any further assistance please contact me.

Eric Lindquist, DMV, DABVP, Cert. IVUSS, CEO of SonoPath.com
info@SonoPath.com