



PATIENT

Zoe Stepling

SPECIES

Canine

BREED

Labrador Retriever

SEX

Spayed female

AGE

10 years

WEIGHT

74 lbs

INTERPRETED BY

Eric Lindquist, DMV
DABVP, Cert. IVUSS

IMAGING PERFORMED BY

Dr. Bray

HOSPITAL NAME

Taylorville VC

REFERRING VET

Dr. Bray

INVOICE

42510

DATE

2/1/23

PRESENTING CLINICAL SIGNS

History: For the past few months p has had episodes of decreased appetite or skipping a meal, excessive panting and lethargy. Owner wasn't sure if p was in pain. No lameness seen but p is overweight and older. Episodes last ~24 to 48 hours then she seems better. No V/D/C/S. On joint supplements and Simparica Trio

Abnormal PE/Chem/CBC/UA Results: P is very anxious/excited in clinic. Overweight by ~14lbs with lipomas. Besides weight, lipomas, and some mild dental disease, PE is pretty unremarkable. CBC/Chem/TT4 WNL, UA WNL except USG of 1.012.

ULTRASONOGRAPHIC EXAMINATION OF THE ABDOMEN

Urinary System

The **urinary bladder**, trigone, and pelvic urethra presented normal thicknesses and normal tone. The ureters were not visible which is normal. No uroliths or sediment were visualized and anechoic urine was present. No evidence of inflammatory or neoplastic changes was noted. Ureteral papillae were normal.

The **kidneys** revealed largely normal size and structure, corticomedullary definition and ratio (cortex 1/3 of medulla) were essentially maintained with some age-related loss of curvilinear patterns regarding the capsule and C/M junction. The cortices presented largely uniform texture with some increased echogenicity expected for his age patient. Medullary structure differed distinctly from that of the cortex and no evidence of pelvic dilation was present. The kidneys each measured 6.0 cm.

Adrenal Glands

Both **adrenal glands** were visualized and recognized as having normal shape, size, position and echogenicity for this breed. The phrenic vasculature, glandular echogenicity and detail were unremarkable. Capsule, cortex, and medullary definition were normal for this age patient. The left adrenal gland measured 0.5 cm. The right adrenal gland measured 0.85 cm at the cranial pole and 0.5 cm at the caudal pole.

Spleen

The **spleen** presented a smooth homogeneous parenchyma hyperechoic to liver and renal cortical parenchyma. The capsule was smooth without noticeable expansion or deviation from within the spleen or adjacent pathology. The splenic vasculature demonstrated normal volume without signs of congestion or thrombosis. No sonographic evidence of acute or chronic inflammatory, neoplastic, or infarctual changes was noted.

Liver

The **liver** images from right and left intercostal as well as subcostal views revealed subjectively normal liver size, contour, and structure. Some age-related parenchymal remodeling was noted but likely not clinically significant at this time. Vascular and biliary tracts were of normal volume and no evidence of congestion was noted. The gallbladder presented some dependent debris with essentially normal



PATIENT

Zoe Stepling

contour. The cystic and common bile ducts were normal. No overt evidence of active inflammatory, infiltrative or regenerative pathology was noted but should be paired with current or past LE elevations regarding any clinical significance to this presentation. The hepatic lymph nodes were unremarkable.

SPECIES

Canine

Gastrointestinal

Examination of the **gastrointestinal tract** revealed a stomach and intestine free of stasis, of normal wall thickness, acceptable curvilinear mural detail, and peristaltic activity. Small and large intestine demonstrated normal luminal chyme and stool consistency respectively. No obstructive or overt infiltrative disease was noted. No associated abnormal lymphatic activity was noted.

BREED

Labrador Retriever

SEX

Spayed female

Pancreas

The base and limbs of the **pancreas** were observed to be largely isoechoic to surrounding omental fat. Pancreatic duct and capsular contour were acceptably normal and parenchyma respected normal curvilinear patterns. No overt evidence of active inflammatory or neoplastic disease was noted.

AGE

10 years

ULTRASONOGRAPHIC FINDINGS

Structurally unremarkable abdomen with age related changes.

WEIGHT

74 lbs

INTERPRETATION OF THE FINDINGS & FURTHER RECOMMENDATIONS

There was no evidence of pathology that would be responsible for the clinical signs. Assessment for pain related, CNS and thoracic disease is warranted as cause of the clinical issues.

INTERPRETED BY

Eric Lindquist, DMV
DABVP, Cert. IVUSS

IMAGING PERFORMED BY

Dr. Bray

HOSPITAL NAME

Taylorville VC

REFERRING VET

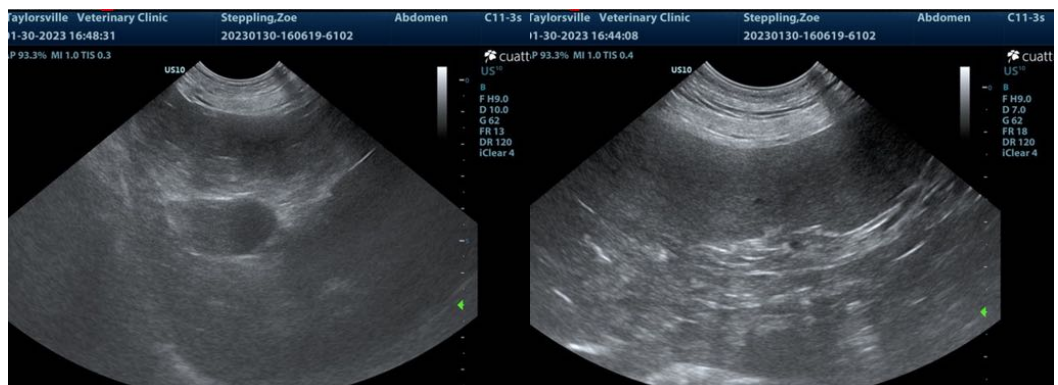
Dr. Bray

INVOICE

42510

DATE

2/1/23





PATIENT

Zoe Stepling

SPECIES

Canine

BREED

Labrador Retriever

SEX

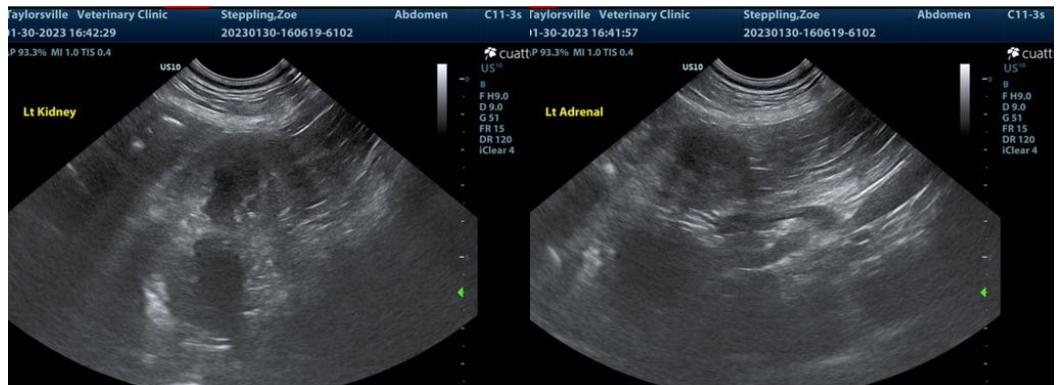
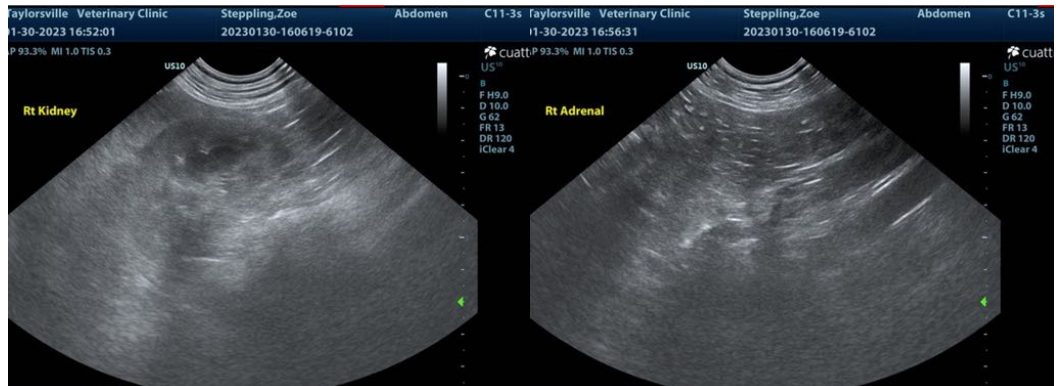
Spayed female

AGE

10 years

WEIGHT

74 lbs



INTERPRETED BY

Eric Lindquist, DMV
DABVP, Cert. IVUSS

IMAGING PERFORMED BY

Dr. Bray

HOSPITAL NAME

Taylorville VC

REFERRING VET

Dr. Bray

INVOICE

42510

DATE

2/1/23

The information and recommendations provided are based on the images presented by the referring veterinarian/sonographer. No evaluation can be communicated regarding pathology that was not visible in the image/video clips provided.

Thank you for this referral. If the clinical or image interpretation does not parallel your findings or if I can be of any further assistance please contact me.

Eric Lindquist, DMV, DABVP, Cert. IVUSS, CEO of SonoPath.com
info@SonoPath.com