



**PATIENT**

Rosco Jackson

**SPECIES**

Canine

**BREED**

Basset Hound

**SEX**

Neutered Male

**AGE**

9.5 Years

**WEIGHT**

88 Lbs.

**INTERPRETED BY**

Eric Lindquist, DMV  
DABVP, Cert. IVUSS

**IMAGING PERFORMED BY**

A. Rodriguez

**HOSPITAL NAME**

Foxfield VS

**REFERRING VET**

A. Rodriguez

**INVOICE**

13718

**DATE**

2/1/22

**PRESENTING CLINICAL SIGNS**

History: Painful abdomen on palpation

Abnormal PE/Chem/CBC/UA Results: Pending

**ULTRASONOGRAPHIC EXAMINATION OF THE ABDOMEN**

**Urinary System**

The **urinary bladder**, trigone, and pelvic urethra presented normal thicknesses and normal tone. The ureters were not visible which is normal. No uroliths or sediment were visualized and anechoic urine was present. No evidence of inflammatory or neoplastic changes were noted. Ureteral papillae were normal. The pelvic urethra was imaged 3.0 cm beyond the cystourethral junction.

The **kidneys** revealed normal size and structure, corticomedullary definition and ratio for this age. The cortices presented largely uniform texture with normal echogenic relationship to liver and spleen. Medullary structure differed distinctly from the cortex and no evidence of pelvic dilation was present. The capsules were acceptably uniform without significant irregularities. The left kidney measured 6.8 cm. The right kidney measured 8.3 cm.

**Adrenal Glands**

The **adrenal glands** appeared slightly enlarged and swollen. No evidence of focal capsular expansion or invasion into the phrenic veins were noted. No overt suspicion of neoplasia was noted. This is considered likely a hyperplastic change associated with stress or adrenal endocrinopathy (PDH). If isosthenuria is persistently present and the patient morphologically suggests Cushing's disease, then ACTH testing would be indicated. The right adrenal gland measured 2.97 cm x 1.08 cm. The left adrenal gland measured 3.02 cm x 1.04 cm.

**Spleen**

The **spleen** presented a smooth homogeneous parenchyma hyperechoic to liver and renal cortical parenchyma. The capsule was smooth without noticeable expansion or deviation from within the spleen or adjacent pathology. The splenic vasculature demonstrated normal volume without signs of congestion or thrombosis. No sonographic evidence of acute or chronic inflammatory, neoplastic, or infarctual changes were noted.

**Liver**

The **liver** images submitted revealed subjectively normal liver size, contour, and structure. Parenchymal echogenicity was naturally coarse and hypoechoic to the spleen. Vascular and biliary tracts were of normal volume with no evidence of congestion. The gallbladder presented acceptably thin walls with primarily anechoic content. The cystic and common bile ducts were normal. No pathological hepatic lymphadenopathy was evident. No overt structural evidence of inflammatory, infiltrative or regenerative pathology was evident.

**Gastrointestinal**

The **stomach** was filled with ingesta, consistent with postprandial presentation. The small intestine and colon were unremarkable.

**Pancreas**



**PATIENT**

Rosco Jackson

The base and limbs of the **pancreas** were observed to be largely isoechoic to surrounding omental fat. Pancreatic duct and capsular contour were acceptably normal and parenchyma respected normal curvilinear patterns. No overt evidence of active inflammatory or neoplastic disease was noted.

**SPECIES**

Canine

**ULTRASONOGRAPHIC FINDINGS**

- Bilateral adrenal hypertrophy
- Stomach ingesta
- Structurally unremarkable abdomen

**BREED**

Basset Hound

**INTERPRETATION OF THE FINDINGS & FURTHER RECOMMENDATIONS**

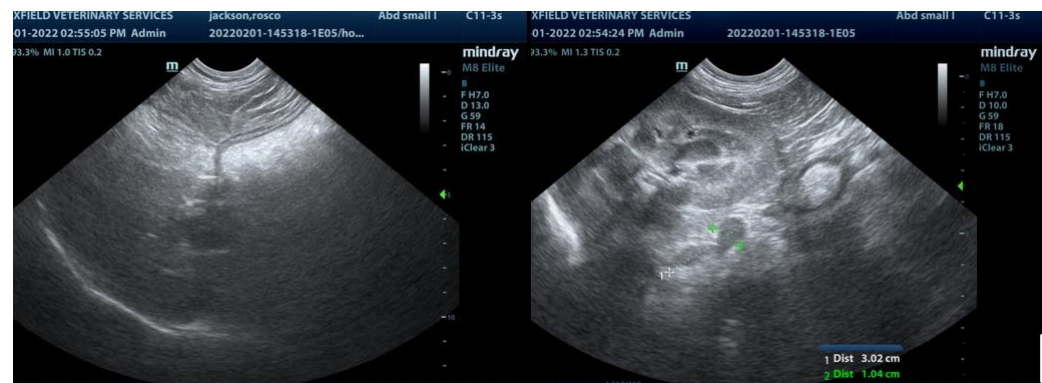
No evidence of visceral disease to be responsible for the tense abdomen. Referred back pain should be considered.

**SEX**

Neutered Male

**AGE**

9.5 Years

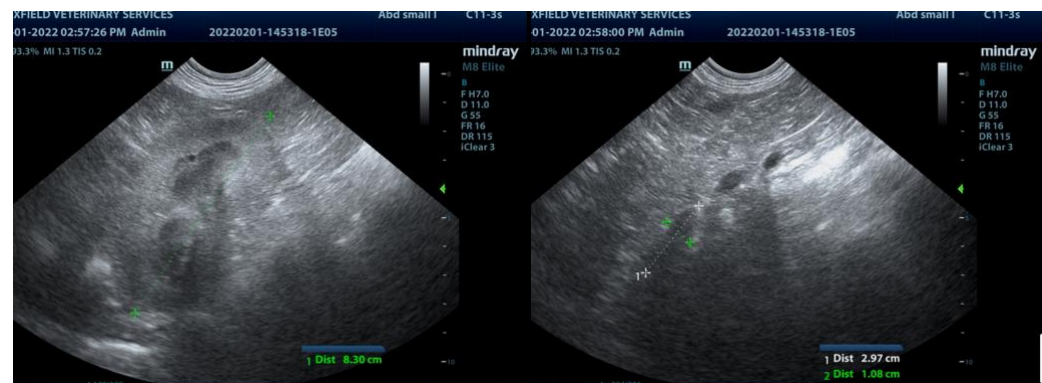


**WEIGHT**

88 Lbs.

**INTERPRETED BY**

Eric Lindquist, DMV  
DABVP, Cert. IVUSS



**IMAGING PERFORMED BY**

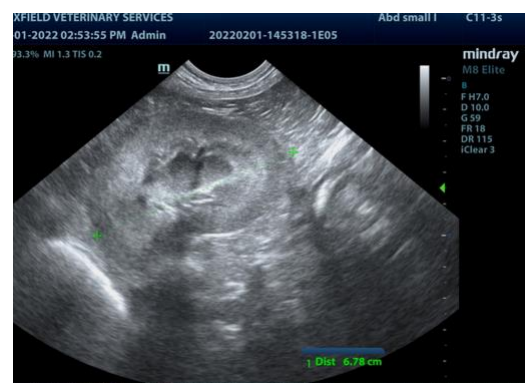A. Rodriguez

**HOSPITAL NAME**

Foxfield VS

**REFERRING VET**

A. Rodriguez



**INVOICE**

13718

**DATE**

2/1/22



**PATIENT**

Rosco Jackson

The information and recommendations provided are based on the images presented by the referring veterinarian. No evaluation can be communicated regarding pathology that was not visible in the image/video clips provided.

**SPECIES**

Canine

Thank you for this referral. If the clinical or image interpretation does not parallel your findings or if I can be of any further assistance please contact me.

**BREED**

Basset Hound

**Eric Lindquist**, DMV, DABVP, Cert. IVUSS, CEO of SonoPath.com  
info@SonoPath.com

**SEX**

Neutered Male

**AGE**

9.5 Years

**WEIGHT**

88 Lbs.

**INTERPRETED BY**

Eric Lindquist, DMV  
DABVP, Cert. IVUSS

**IMAGING  
PERFORMED BY**

A. Rodriguez

**HOSPITAL NAME**

Foxfield VS

**REFERRING VET**

A. Rodriguez

**INVOICE**

13718

**DATE**

2/1/22