



PATIENT

Lola Kahn

SPECIES

Canine

BREED

Lab Retriever

SEX

Spayed Female

AGE

9 Years 8 Months

WEIGHT

74.1 Lbs.

INTERPRETED BY

Eric Lindquist, DMV
DABVP, Cert. IVUSS

IMAGING PERFORMED BY

Sarah Green

HOSPITAL NAME

Healing Spirit Animal
Wellness

REFERRING VET

Sarah Green

INVOICE

13719

DATE

2/1/22

PRESENTING CLINICAL SIGNS

History: Presented due to recent onset hyporexia and vomiting

Abnormal PE/Chem/CBC/UA Results: subdued, sensitive on abdominal palpation, CBC, chem, cPL all unremarkable, T4=0.9 (1.1-4.0) ug/dL

ULTRASONOGRAPHIC EXAMINATION OF THE ABDOMEN

Urinary System

The **urinary bladder**, trigone, and pelvic urethra presented normal thicknesses and normal tone. The ureters were not visible which is normal. No uroliths or sediment were visualized and anechoic urine was present. No evidence of inflammatory or neoplastic changes were noted. Ureteral papillae were normal. The pelvic urethra was imaged 2.0 cm beyond the cystourethral junction.

The **kidneys** revealed normal size and structure, corticomedullary definition and ratio for this age. The cortices presented largely uniform texture with normal echogenic relationship to liver and spleen. Medullary structure differed distinctly from the cortex and no evidence of pelvic dilation was present. The capsules were acceptably uniform without significant irregularities. The left kidney measured 6.0 cm. The right kidney measured 6.0 cm.

Adrenal Glands

Both **adrenal glands** were not visualized.

Spleen

The **spleen** presented subtle micronodular changes.

Liver

The **liver** was mildly enlarged with slight coarse architecture. The gallbladder and common bile duct were unremarkable.

Gastrointestinal

Examination of the **gastrointestinal tract** revealed a stomach and intestine free of stasis, of normal wall thickness, acceptable curvilinear mural detail, and peristaltic activity. Small and large intestine demonstrated normal luminal chyme and stool consistency respectively. No obstructive or overt infiltrative disease was noted. No associated abnormal lymphatic activity was noted.

Pancreas

The base and limbs of the **pancreas** were observed to be largely isoechoic to surrounding omental fat. Pancreatic duct and capsular contour were acceptably normal and parenchyma respected normal curvilinear patterns. No overt evidence of active inflammatory or neoplastic disease was noted.

Free Abdomen

The mesenteric **lymph nodes** were enlarged, hypoechoic and irregular with enhanced mesentery, suggestive for inflammation. The largest lymph node measured 2.5 cm x 0.8 cm encompassing the mesenteric artery. Other caudal abdominal lymph nodes were also mildly enlarged and hypoechoic.

ULTRASONOGRAPHIC FINDINGS



PATIENT

Lola Kahn

- Mesenteric and abdominal lymphadenopathy
- Subtle splenohepatic heterogeneous changes

INTERPRETATION OF THE FINDINGS & FURTHER RECOMMENDATIONS

SPECIES

Canine

FNA of the spleen, liver and accessible lymph nodes warranted. Screening for Addisons warranted given that the adrenals were not overtly visualized. I'm concerned for emerging round cell neoplasia in this patient or possible occult Addisons. Chest radiographs and full CNS examination also warranted to assess for comorbidities.

BREED

Lab Retriever

SEX

Spayed Female

AGE

9 Years 8 Months

WEIGHT

74.1 Lbs.

INTERPRETED BY

Eric Lindquist, DMV
DABVP, Cert. IVUSS

IMAGING PERFORMED BY

Sarah Green

HOSPITAL NAME

Healing Spirit Animal
Wellness

REFERRING VET

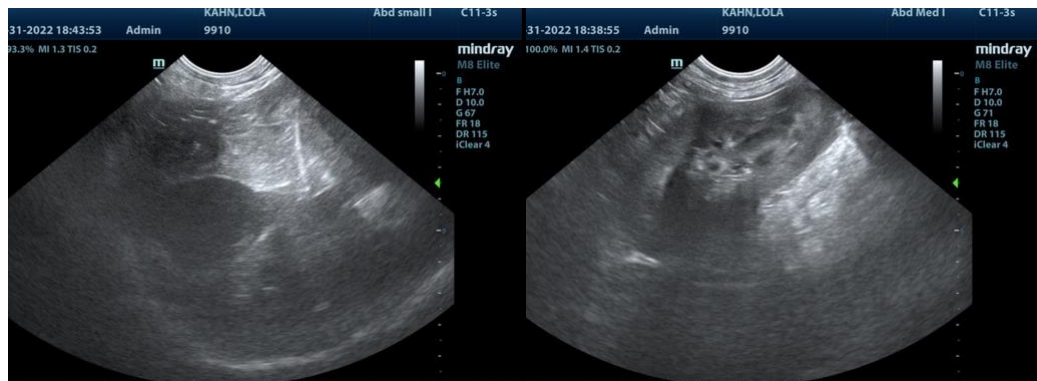
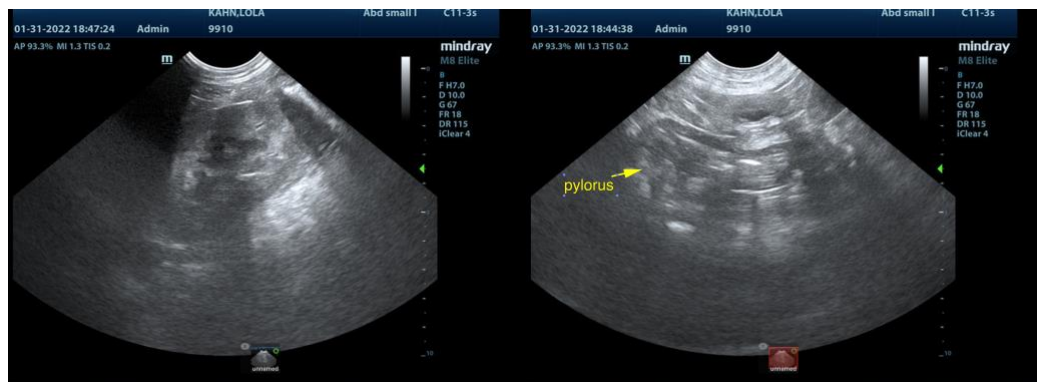
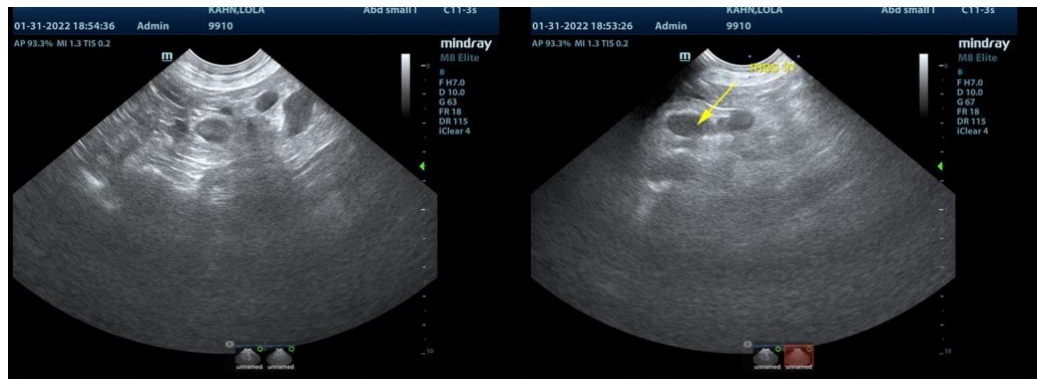
Sarah Green

INVOICE

13719

DATE

2/1/22



The information and recommendations provided are based on the images presented by the referring veterinarian. No evaluation can be communicated regarding pathology that was not visible in the image/video clips provided.

Thank you for this referral. If the clinical or image interpretation does not parallel your findings or if I



PATIENT

can be of any further assistance please contact me.

Lola Kahn

SPECIES

Eric Lindquist, DMV, DABVP, Cert. IVUSS, CEO of SonoPath.com
info@SonoPath.com

Canine

BREED

Lab Retriever

SEX

Spayed Female

AGE

9 Years 8 Months

WEIGHT

74.1 Lbs.

INTERPRETED BY

Eric Lindquist, DMV
DABVP, Cert. IVUSS

**IMAGING
PERFORMED BY**

Sarah Green

HOSPITAL NAME

Healing Spirit Animal
Wellness

REFERRING VET

Sarah Green

INVOICE

13719

DATE

2/1/22