



**PATIENT PRESENTING CLINICAL SIGNS**

Cha Ching Castray  
Conroy  
Inappetent, not drinking normally, some soft stool. On clindamycin  
CBC: neuts 13.05 high, RBCs 9.6 high, HCT 64.75; chem WNL

**SPECIES**

Canine

**ULTRASONOGRAPHIC EXAMINATION OF THE ABDOMEN**

**Urinary System**

**BREED**

Schnauzer Mix

The **urinary bladder**, trigone, and pelvic urethra presented normal thicknesses and normal tone. The ureters were not visible which is normal. No uroliths or sediment were visualized and anechoic urine was present. No evidence of inflammatory or neoplastic changes was noted. Ureteral papillae were normal.

**SEX**

Neutered male

The residual prostate was mildly heterogenous and measured 0.8 cm.

**AGE**

11 years

The **kidneys** revealed largely normal size and structure, corticomedullary definition and ratio (cortex 1/3 of medulla) were essentially maintained with some age-related loss of curvilinear patterns regarding the capsule and C/M junction. The cortices presented largely uniform texture with some increased echogenicity expected for this age patient. Medullary structure differed distinctly from that of the cortex and no evidence of pelvic dilation was present. Slight mineralization was noted in the left kidney. The left kidney measured 4.43 cm. The right kidney measured 4.52 cm.

**WEIGHT**

13.2 lbs

**Adrenal Glands**

Both **adrenal glands** were visualized and recognized as having normal shape, size, position and echogenicity for this breed. The phrenic vasculature, glandular echogenicity and detail were unremarkable. Capsule, cortex, and medullary definition were normal for this age patient. The left adrenal gland measured 2.01 x 0.73 cm at the caudal pole and 0.73 cm at the cranial pole. The right adrenal gland measured 2.1 x 0.91 cm at the cranial pole and 0.68 cm at the caudal pole.

**INTERPRETED BY**

Eric Lindquist, DMV  
DABVP, Cert. IVUSS

**IMAGING**

**PERFORMED BY**

Diane McFadden, RVT

**Spleen**

The **spleen** presented a smooth homogeneous parenchyma hyperechoic to liver and renal cortical parenchyma. The capsule was smooth without noticeable expansion or deviation from within the spleen or adjacent pathology. The splenic vasculature demonstrated normal volume without signs of congestion or thrombosis. No sonographic evidence of acute or chronic inflammatory, neoplastic, or infarctual changes was noted.

**HOSPITAL NAME**

Animal Hospital of  
Sussex County

**INVOICE**

95733

**Liver**

**DATE**

2/1/22

The **liver** images submitted revealed subjectively normal liver size, contour, and structure. Parenchymal echogenicity was naturally coarse and hypoechoic to the spleen. Vascular and biliary tracts were of normal volume with no evidence of congestion. The gallbladder presented acceptably thin walls with primarily anechoic content. The cystic and common bile ducts were normal. No pathological hepatic lymphadenopathy was evident. No overt structural evidence of inflammatory, infiltrative or regenerative pathology was evident.



**PATIENT**

**Gastrointestinal**

Cha Ching Castray  
Conroy

Examination of the **gastrointestinal tract** revealed a stomach and intestine free of stasis, of normal wall thickness, acceptable curvilinear mural detail, and peristaltic activity. Small and large intestine demonstrated normal luminal chyme and stool consistency respectively. No obstructive or overt infiltrative disease was noted. No associated abnormal lymphatic activity was noted.

**SPECIES**

Canine

**BREED**

Schnauzer Mix

**Pancreas**

The base and limbs of the **pancreas** were observed to be largely isoechoic to surrounding omental fat. Pancreatic duct and capsular contour were acceptably normal and parenchyma respected normal curvilinear patterns. No overt evidence of active inflammatory or neoplastic disease was noted.

**SEX**

Neutered male

**ULTRASONOGRAPHIC FINDINGS**

Structurally unremarkable abdomen.

**AGE**

11 years

Largely age related abdominal changes.

Minor, heterogenous prostate.

**WEIGHT**

13.2 lbs

Mild bilateral adrenal enlargement. Potential emerging PDH.

**INTERPRETATION OF THE FINDINGS & FURTHER RECOMMENDATIONS**

**INTERPRETED BY**

Eric Lindquist, DMV  
DABVP, Cert. IVUSS

There was no evidence of significant disease. If the patient appears Cushingoid and urine specific gravity is less than 1.020 then work-up for PDH is indicated. There is no obvious evidence of visceral pathology that would be responsible for the inappetence. Orthopedic pain such as back spasms, chest radiographs and CNS examination is indicated.

**IMAGING PERFORMED BY**

Diane McFadden, RVT

**HOSPITAL NAME**

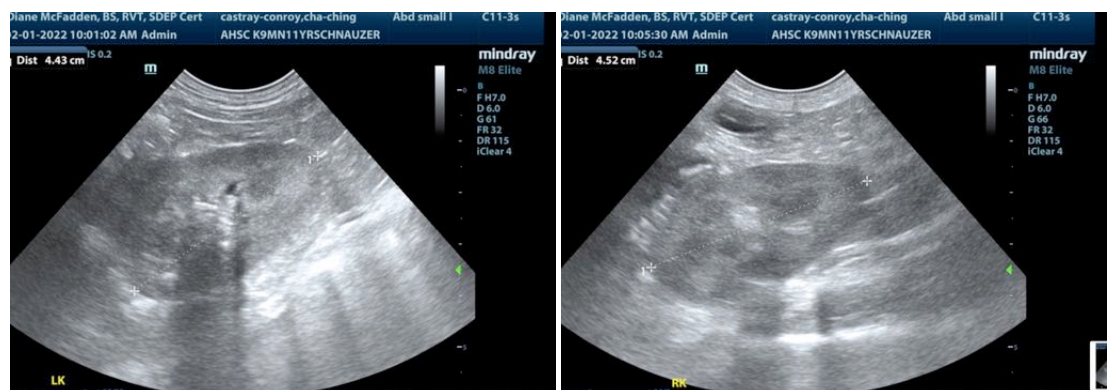
Animal Hospital of  
Sussex County

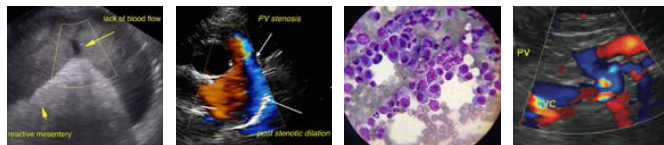
**INVOICE**

95733

**DATE**

2/1/22





**PATIENT**

Cha Ching Castray  
Conroy

**SPECIES**

Canine

**BREED**

Schnauzer Mix

**SEX**

Neutered male

**AGE**

11 years

**WEIGHT**

13.2 lbs

**INTERPRETED BY**

Eric Lindquist, DMV  
DABVP, Cert. IVUSS

**IMAGING  
PERFORMED BY**

Diane McFadden, RVT

**HOSPITAL NAME**

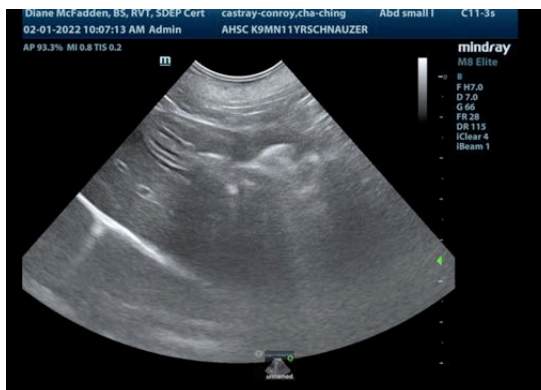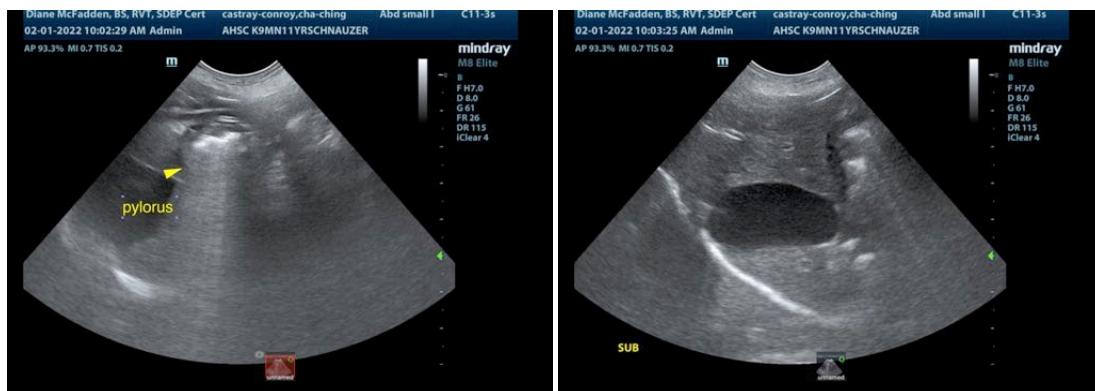
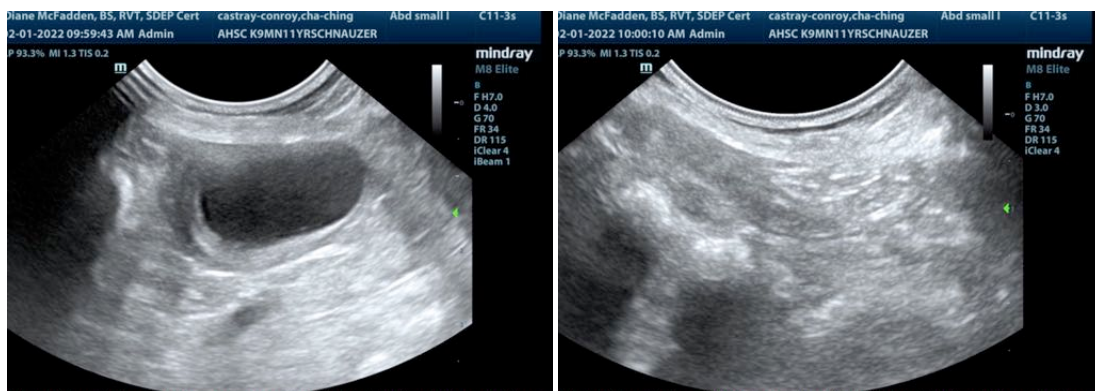
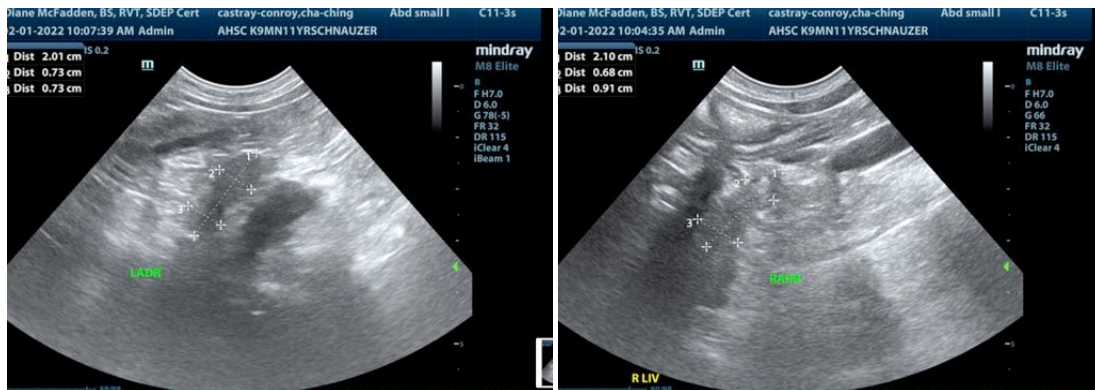
Animal Hospital of  
Sussex County

**INVOICE**

95733

**DATE**

2/1/22





**PATIENT**

Cha Ching Castray  
Conroy

The information and recommendations provided are based on the images presented by the referring veterinarian/sonographer. No evaluation can be communicated regarding pathology that was not visible in the image/video clips provided.

**SPECIES**

Canine

Thank you for this referral. If the clinical or image interpretation does not parallel your findings or if I can be of any further assistance please contact me.

**BREED**

Schnauzer Mix

**Eric Lindquist**, DMV, DABVP, Cert. IVUSS, CEO of SonoPath.com  
Info@SonoPath.com

**SEX**

Neutered male

**AGE**

11 years

**WEIGHT**

13.2 lbs

**INTERPRETED BY**

Eric Lindquist, DMV  
DABVP, Cert. IVUSS

**IMAGING  
PERFORMED BY**

Diane McFadden, RVT

**HOSPITAL NAME**

Animal Hospital of  
Sussex County

**INVOICE**

95733

**DATE**

2/1/22