



**PATIENT**

Cessna Jones

**SPECIES**

Feline

**BREED**

Domestic Longhair

**SEX**

Spayed Female

**AGE**

5 years

**WEIGHT**

11.2 lbs

**INTERPRETED BY**

Eric Lindquist, DMV  
DABVP, Cert. IVUSS

**IMAGING PERFORMED BY**

Dr. Green

**HOSPITAL NAME**

Healing Spirit AW

**REFERRING VET**

Dr. Green

**INVOICE**

95754

**DATE**

2/1/22

**PRESENTING CLINICAL SIGNS**

Protruding third eyelids, hyporexia 2-3 weeks duration.

Abnormal PE/Chem/CBC/UA Results: Pronounced protrusion of the third eyelid, OU, cornea, conjunctiva, AC, fundus all WNL. Non localized sensitivity on abdominal palpation. CBC, chem, T4, fPL all WNL

**ULTRASONOGRAPHIC EXAMINATION OF THE ABDOMEN**

**Urinary System**

The **urinary bladder**, trigone, and pelvic urethra presented normal thicknesses and normal tone. The ureters were not visible which is normal. No uroliths or sediment were visualized and anechoic urine was present. No evidence of inflammatory or neoplastic changes was noted. Ureteral papillae were normal.

The **kidneys** revealed normal size and structure, corticomedullary definition and ratio for this age. The cortices presented largely uniform texture with normal echogenic relationship to liver and spleen. Medullary structure differed distinctly from the cortex and no evidence of pelvic dilation was present. The capsules were acceptably uniform without significant irregularities. The kidneys measured 3.5 cm each.

**Adrenal Glands**

Both **adrenal glands** were visualized and recognized as having normal shape, size, position and echogenicity for this breed. The phrenic vasculature, glandular echogenicity and detail were unremarkable. Capsule, cortex, and medullary definition were normal for this age patient.

**Spleen**

The **spleen** presented a smooth homogeneous parenchyma hyperechoic to liver and renal cortical parenchyma. The capsule was smooth without noticeable expansion or deviation from within the spleen or adjacent pathology. The splenic vasculature demonstrated normal volume without signs of congestion or thrombosis. No sonographic evidence of acute or chronic inflammatory, neoplastic, or infarctual changes was noted.

**Liver**

The **liver** images submitted revealed subjectively normal liver size, contour, and structure. Parenchymal echogenicity was naturally coarse and hypoechoic to the spleen. Vascular and biliary tracts were of normal volume with no evidence of congestion. The gallbladder presented acceptably thin walls with primarily anechoic content. The cystic and common bile ducts were normal. No pathological hepatic lymphadenopathy was evident. No overt structural evidence of inflammatory, infiltrative or regenerative pathology was evident.



**PATIENT**

**Gastrointestinal**

Cessna Jones

The **stomach** revealed shadowing material that is consistent with hairball accumulation. Transit of chyme was present in the small intestine. The curvilinear patterns are maintained.

**SPECIES**

Feline

**Pancreas**

The left limb of the **pancreas** was hypoechoic and mildly irregular.

**BREED**

Domestic Longhair

**ULTRASONOGRAPHIC FINDINGS**

**SEX**

Hairball density in the stomach with slight, irregular, left pancreatic limb. Potential low-grade inflammation/pancreatitis.

Spayed Female

**AGE**

5 years

**INTERPRETATION OF THE FINDINGS & FURTHER RECOMMENDATIONS**

Given the protrusion of the third eyelid CT of the skull is recommended. Treatment for low grade pancreatitis could be considered.

**WEIGHT**

11.2 lbs

**INTERPRETED BY**

Eric Lindquist, DMV  
DABVP, Cert. IVUSS

**IMAGING PERFORMED BY**

Dr. Green

**HOSPITAL NAME**

Healing Spirit AW

**REFERRING VET**

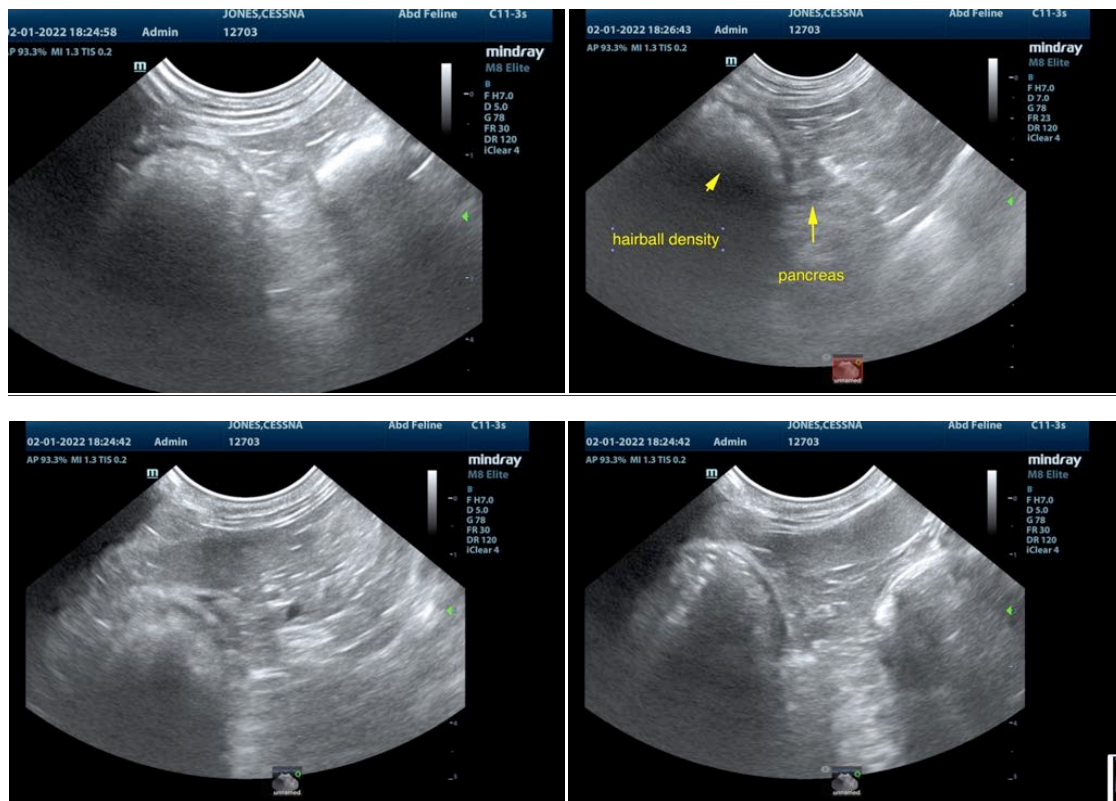
Dr. Green

**INVOICE**

95754

**DATE**

2/1/22





**PATIENT**

Cessna Jones

The information and recommendations provided are based on the images presented by the referring veterinarian/sonographer. No evaluation can be communicated regarding pathology that was not visible in the image/video clips provided.

**SPECIES**

Feline

Thank you for this referral. If the clinical or image interpretation does not parallel your findings or if I can be of any further assistance please contact me.

**BREED**

Domestic Longhair

**Eric Lindquist, DMV, DABVP, Cert. IVUSS, CEO of SonoPath.com**  
info@SonoPath.com

**SEX**

Spayed Female

**AGE**

5 years

**WEIGHT**

11.2 lbs

**INTERPRETED BY**

Eric Lindquist, DMV  
DABVP, Cert. IVUSS

**IMAGING  
PERFORMED BY**

Dr. Green

**HOSPITAL NAME**

Healing Spirit AW

**REFERRING VET**

Dr. Green

**INVOICE**

95754

**DATE**

2/1/22