



## PATIENT

Rosebud Plati

## SPECIES

Canine

## BREED

Golden Retriever

## SEX

Spayed female

## AGE

7 months

## WEIGHT

57 lbs

## INTERPRETED BY

Eric Lindquist, DMV  
DABVP, Cert. IUUSS

## IMAGING PERFORMED BY

Jenn

## HOSPITAL NAME

Rockaway AH

## REFERRING VET

Dr. Maniar

## INVOICE

69384

## DATE

12/9/25

## PRESENTING CLINICAL SIGNS

History: recheck from 12/8

## ULTRASONOGRAPHIC EXAMINATION

### *Gastrointestinal*

Gastric thickening was noted with fluid filled lumen. An obstructive pattern was noted.

### *Free Abdomen*

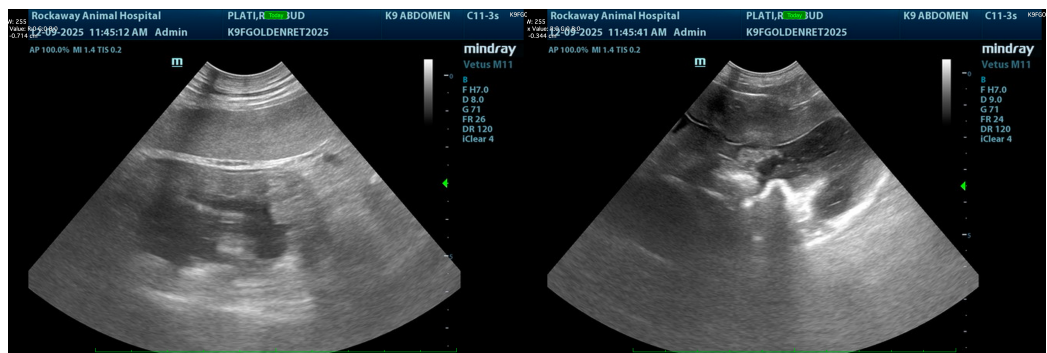
Free fluid was noted in the abdomen.

## ULTRASONOGRAPHIC FINDINGS

Concentric gastric wall thickening is persistently present. Some shadowing material is more visible in the stomach.

## INTERPRETATION OF THE FINDINGS & FURTHER RECOMMENDATIONS

Immediate exploratory surgery with GI biopsies and inspection of the GI tract is indicated.



The information and recommendations provided are based on the images presented by the referring veterinarian/sonographer. No evaluation can be communicated regarding pathology that was not visible in the image/video clips provided.

Thank you for this referral. If the clinical or image interpretation does not parallel your findings or if I can be of any further assistance please contact me.

Eric Lindquist, DMV, DABVP (CFM), Cert. IUUSS, CEO of SonoPath.com

[info@SonoPath.com](mailto:info@SonoPath.com)