



PATIENT

Lambert Schlieder

SPECIES

Feline

BREED

Domestic Shorthair

SEX

Spayed female

AGE

15 years

WEIGHT

9.6 lbs

INTERPRETED BY

Eric Lindquist, DMV
DABVP, Cert. IVUSS

IMAGING PERFORMED BY

Dr. Todd

HOSPITAL NAME

Lambs Gap AH

REFERRING VET

Dr. Todd

INVOICE

69453

DATE

12/9/25

PRESENTING CLINICAL SIGNS

History: Lambert is a fifteen year old, FS, DSH cat with a history of 1.5# weight loss in the last 10 months, progressively increasing hyperglobulinemia and a monoclonal gammopathy. Abdominal ultrasound was advised with liver and spleen FNAs to check for neoplasia. Lab results attached FYI

ULTRASONOGRAPHIC EXAMINATION OF THE ABDOMEN

Urinary System

The **urinary bladder**, trigone, and pelvic urethra presented normal thicknesses and normal tone. The ureters were not visible which is normal. No uroliths or sediment were visualized and anechoic urine was present. No evidence of inflammatory or neoplastic changes was noted. Ureteral papillae were normal.

The **kidneys** revealed largely normal size and structure, corticomedullary definition and ratio (cortex 1/3 of medulla) were essentially maintained with some age-related loss of curvilinear patterns regarding the capsule and C/M junction. The cortices presented largely uniform texture with some increased echogenicity expected for this age patient. Medullary structure differed distinctly from that of the cortex and no evidence of pelvic dilation was present. The right kidney measured 3.86 cm. The left kidney measured 3.25 cm.

Adrenal Glands

Both **adrenal glands** were visualized and recognized as having normal shape, size, position and echogenicity for this breed. The phrenic vasculature, glandular echogenicity and detail were unremarkable. Capsule, cortex, and medullary definition were normal for this age patient. The left adrenal gland measured 0.3 cm. The right adrenal gland measured 0.3 cm.

Spleen

The **spleen** presented a smooth homogeneous parenchyma hyperechoic to liver and renal cortical parenchyma. The capsule was smooth without noticeable expansion or deviation from within the spleen or adjacent pathology. The splenic vasculature demonstrated normal volume without signs of congestion or thrombosis. No sonographic evidence of acute or chronic inflammatory, neoplastic, or infarctual changes was noted.

Liver

The **liver** images submitted revealed subjectively normal liver size, contour, and structure. Parenchymal echogenicity was naturally coarse and hypoechoic to the spleen. Vascular and biliary tracts were of normal volume with no evidence of congestion. The gallbladder presented acceptably thin walls with primarily anechoic content. The cystic and common bile ducts were normal. No pathological hepatic lymphadenopathy was evident. No overt structural evidence of inflammatory, infiltrative or regenerative pathology was evident.



PATIENT

Lambert Schlieder

SPECIES

Feline

BREED

Domestic Shorthair

SEX

Spayed female

AGE

15 years

WEIGHT

9.6 lbs

INTERPRETED BY

Eric Lindquist, DMV
DABVP, Cert. IVUSS

IMAGING PERFORMED BY

Dr. Todd

HOSPITAL NAME

Lambs Gap AH

REFERRING VET

Dr. Todd

INVOICE

69453

DATE

12/9/25

Gastrointestinal

Examination of the **gastrointestinal tract** revealed a stomach and intestine free of stasis, of normal wall thickness, acceptable curvilinear mural detail, and peristaltic activity. Small and large intestine demonstrated normal luminal chyme and stool consistency respectively. The mesenteric lymph nodes were reactive.

Pancreas

The base and limbs of the **pancreas** were observed to be largely isoechoic to surrounding omental fat. Some parenchymal remodeling, however, with mild deviation from curvilinear normalcy was observed. Pancreatic duct and capsular irregularities were present consistent with age related changes. If pain upon imaging (+ Murphy sign) was present or if the patient is focally painful in subxiphoid palpation then low-grade smoldering chronic pancreatitis should be suspected.

ULTRASONOGRAPHIC FINDINGS

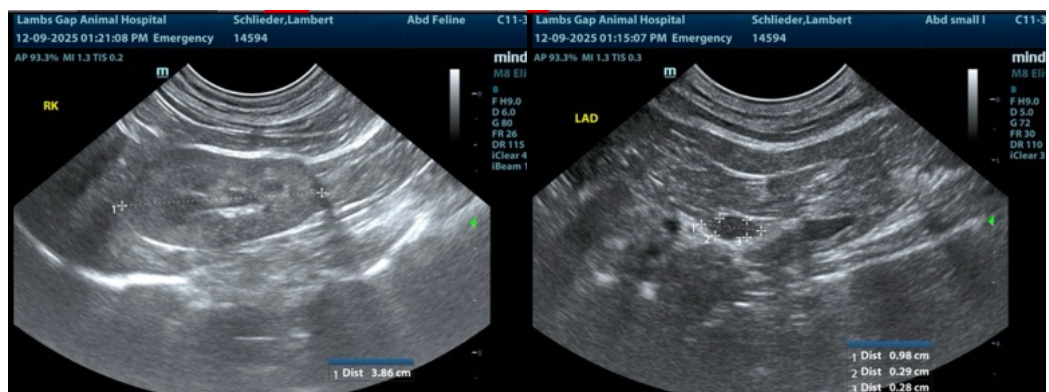
Prominent pancreas.

Reactive mesenteric lymph nodes.

Geriatric abdomen.

INTERPRETATION OF THE FINDINGS & FURTHER RECOMMENDATIONS

There was no overt cause of weight loss in this patient.





PATIENT

Lambert Schlieder

SPECIES

Feline

BREED

Domestic Shorthair

SEX

Spayed female

AGE

15 years

WEIGHT

9.6 lbs

INTERPRETED BY

Eric Lindquist, DMV
DABVP, Cert. IVUSS

IMAGING PERFORMED BY

Dr. Todd

HOSPITAL NAME

Lambs Gap AH

REFERRING VET

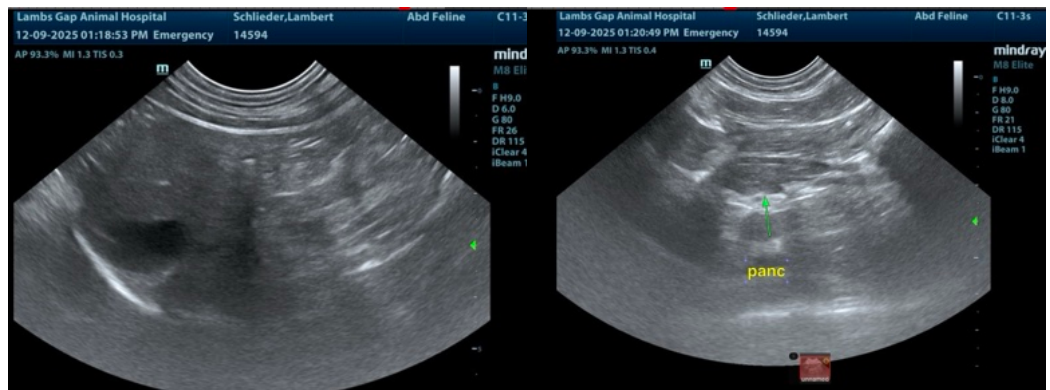
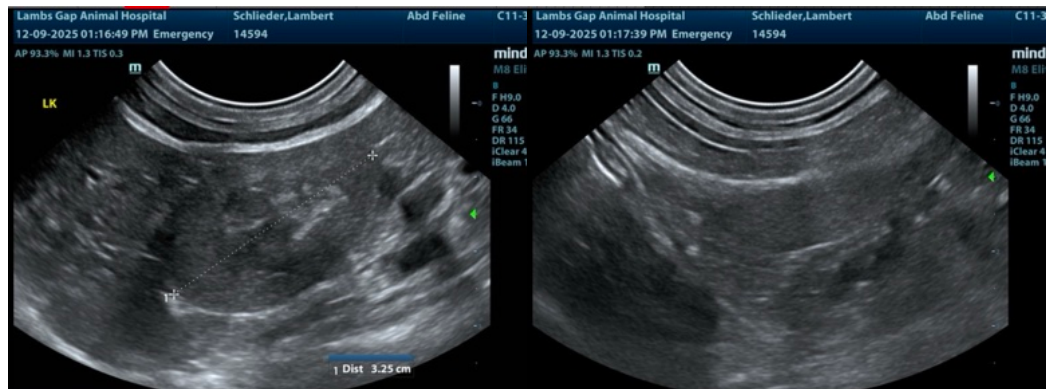
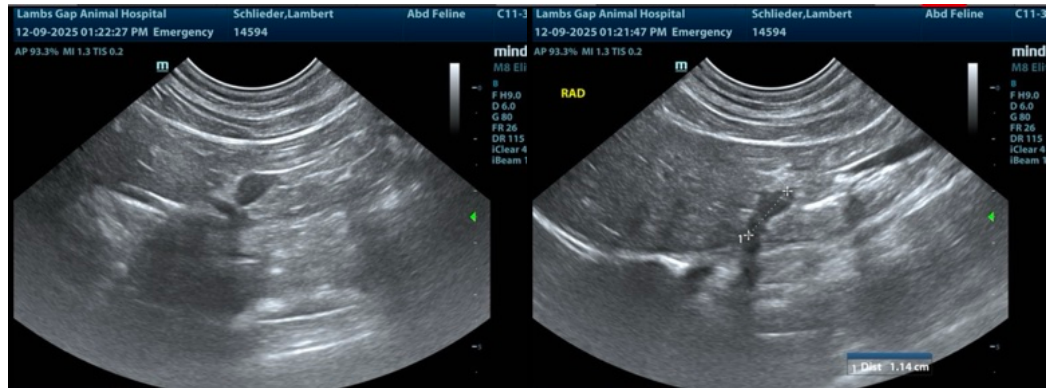
Dr. Todd

INVOICE

69453

DATE

12/9/25





PATIENT

Lambert Schlieder

SPECIES

Feline

BREED

Domestic Shorthair

SEX

Spayed female

AGE

15 years

WEIGHT

9.6 lbs

INTERPRETED BY

Eric Lindquist, DMV
DABVP, Cert. IVUSS

IMAGING PERFORMED BY

Dr. Todd

HOSPITAL NAME

Lambs Gap AH

REFERRING VET

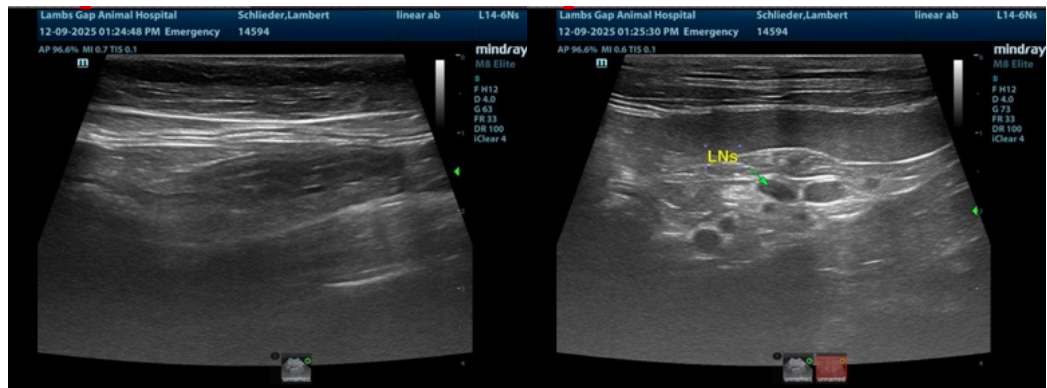
Dr. Todd

INVOICE

69453

DATE

12/9/25



The information and recommendations provided are based on the images presented by the referring veterinarian/sonographer. No evaluation can be communicated regarding pathology that was not visible in the image/video clips provided.

Thank you for this referral. If the clinical or image interpretation does not parallel your findings or if I can be of any further assistance please contact me.

Eric Lindquist, DMV, DABVP (CFM), Cert. IVUSS, CEO of SonoPath.com

info@SonoPath.com