



## PATIENT

Jethro Petrucelli

## SPECIES

Canine

## BREED

Labrador Mix

## SEX

Neutered male

## AGE

12 years

## WEIGHT

50.6 lbs

## INTERPRETED BY

Eric Lindquist, DMV  
DABVP, Cert. IVUSS

## IMAGING PERFORMED BY

Jenn

## HOSPITAL NAME

Rockaway AH

## REFERRING VET

Dr. Maniar

## INVOICE

69383

## DATE

12/9/25

## PRESENTING CLINICAL SIGNS

History: re check from 12/8 decreased appetite no vomiting

## ULTRASONOGRAPHIC EXAMINATION OF THE ABDOMEN

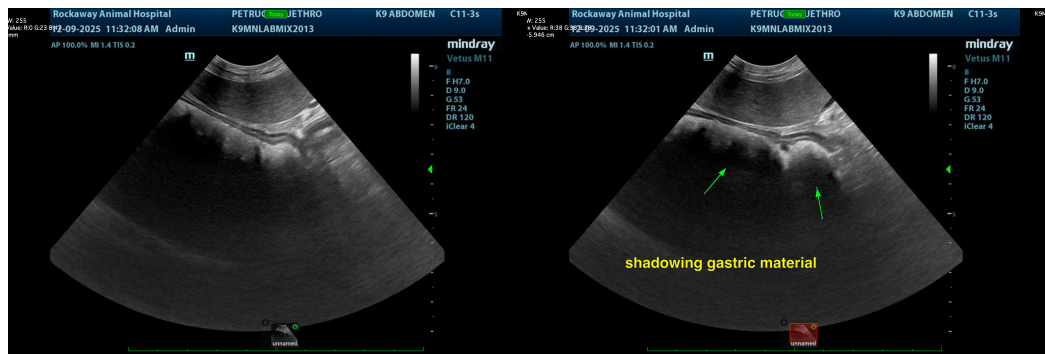
The stomach revealed soft shadowing material. The small intestine and colon were unremarkable.

## ULTRASONOGRAPHIC FINDINGS

Soft shadowing material in the stomach.

## INTERPRETATION OF THE FINDINGS & FURTHER RECOMMENDATIONS

If the patient was n.p.o. at the time of the sonogram then gastrotomy and GI biopsies are indicated.



The information and recommendations provided are based on the images presented by the referring veterinarian/sonographer. No evaluation can be communicated regarding pathology that was not visible in the image/video clips provided.

Thank you for this referral. If the clinical or image interpretation does not parallel your findings or if I can be of any further assistance please contact me.

Eric Lindquist, DMV, DABVP (CFM), Cert. IVUSS, CEO of SonoPath.com

[info@SonoPath.com](mailto:info@SonoPath.com)