



PATIENT

Fiona Liebowitz

SPECIES

Canine

BREED

Mixed

SEX

Spayed Female

AGE

5 Years

WEIGHT

42.8 lbs

INTERPRETED BY

Eric Lindquist, DMV,
DABVP (CFM), Cert.
IVUSS

IMAGING PERFORMED BY

Vicent Ravancho, CVT

HOSPITAL NAME

Animal Hospital of
Sussex County

REFERRING VET

Dr. Lovell

INVOICE

72451

DATE

12/9/25

PRESENTING CLINICAL SIGNS

Mild ALT elevation. Non Clinical. Needs Dentistry. Clinical findings: PE=WNL, Grade I periodontal dz
Current medications: Denamarin

Abnormal PE/Chem/CBC/UA Results: ALT 164 (was 215 prior to starting Denamarin 4 wks ago)

ULTRASONOGRAPHIC EXAMINATION OF THE ABDOMEN

Urinary System

The **urinary bladder**, trigone, and pelvic urethra presented normal thicknesses and normal tone. The ureters were not visible which is normal. No uroliths or sediment were visualized and anechoic urine was present. No evidence of inflammatory or neoplastic changes were noted. Ureteral papillae were normal. The pelvic urethra was imaged 2.0 cm beyond the cystourethral junction.

The **kidneys** revealed normal size and structure, corticomedullary definition and ratio for this age. The cortices presented largely uniform texture with normal echogenic relationship to liver and spleen. Medullary structure differed distinctly from the cortex and no evidence of pelvic dilation was present. The capsules were acceptably uniform without significant irregularities. Left kidney measured 4.67 cm. Right kidney measured 4.01 cm.

Adrenal Glands

Both **adrenal glands** were visualized and recognized as having normal shape, size, position and echogenicity for this breed. The phrenic vasculature, glandular echogenicity and detail were unremarkable. Capsule, cortex, and medullary definition were normal for this age patient. Right measured 3.63 cm x 1.07 cm at the cranial pole and 0.91 cm at the caudal pole. Left measured 1.67 cm x 0.62 cm at the caudal pole and 0.49 cm at the cranial pole.

Spleen

The **spleen** was mildly enlarged, uniform, and folded upon itself cranially.

Liver

The **liver** images submitted revealed subjectively normal liver size, contour, and structure. Parenchymal echogenicity was naturally coarse and hypoechoic to the spleen. Vascular and biliary tracts were of normal volume with no evidence of congestion. The gallbladder presented acceptably thin walls with primarily anechoic content. The cystic and common bile ducts were normal. No pathological hepatic lymphadenopathy was evident. No overt structural evidence of inflammatory, infiltrative or regenerative pathology was evident.

Gastrointestinal

Examination of the **gastrointestinal tract** revealed a stomach and intestine free of stasis, of normal wall thickness, acceptable curvilinear mural detail, and peristaltic activity. Small and large intestine demonstrated normal luminal chyme and stool consistency respectively. No obstructive or overt infiltrative disease was noted. No associated abnormal lymphatic activity was noted.



PATIENT

Fiona Liebowitz

SPECIES

Canine

BREED

Mixed

SEX

Spayed Female

AGE

5 Years

WEIGHT

42.8 lbs

INTERPRETED BY

Eric Lindquist, DMV,
DABVP (CFM), Cert.
IVUSS

IMAGING PERFORMED BY

Vicent Ravancho, CVT

HOSPITAL NAME

Animal Hospital of
Sussex County

REFERRING VET

Dr. Lovell

INVOICE

72451

DATE

12/9/25

Pancreas

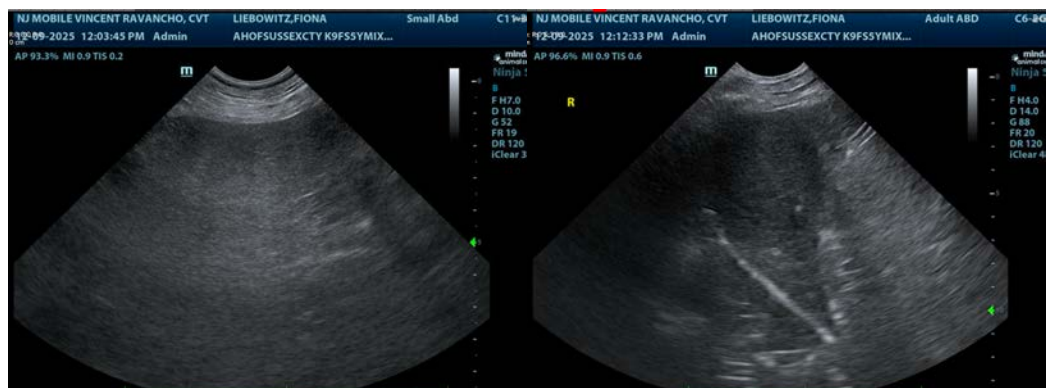
The base and limbs of the **pancreas** were observed to be largely isoechoic to surrounding omental fat. Pancreatic duct and capsular contour were acceptably normal and parenchyma respected normal curvilinear patterns. No overt evidence of active inflammatory or neoplastic disease was noted.

ULTRASONOGRAPHIC FINDINGS

- Structurally unremarkable abdomen and liver. Non-specific ALT elevations, likely reactive hepatopathy.
- Mildly enlarged, folded spleen.

INTERPRETATION OF THE FINDINGS & FURTHER RECOMMENDATIONS

The hepatic clinical sonographic presentation is most consistent with Reactive Hepatopathy which is the most common cause of liver enzyme elevation in dogs and cats. The presumption is that gut and other organ antigen stimuli may be causing a low-grade immune response through portal system with which the liver is reacting to causing low-grade enzyme elevations. US-guided FNA could be performed to assess if low grade lymphoplasmacytic inflammation is present that would support this theory. If FNA is performed, please ask the cytologist to emphasize the primary inflammatory cell type. Empirical treatment measures to address this issue can include diet change to hydrolyzed diet, probiotics, deworming, nutraceuticals (SAME, Actigall...), dental exam and cleaning, and potentially antibiotics such as Clavamox. Metronidazole and Tylosin have traditionally been utilized for this purpose but new studies show that both these antibiotics can disrupt the normal intestinal bacterial flora (intestinal dysbiosis) for weeks and up to 4-6 months. Therefore, Metronidazole and Tylosin should be utilized as a last resort if other efforts have not been effective and sonographic organ appearance remains benign.





PATIENT

Fiona Liebowitz

SPECIES

Canine

BREED

Mixed

SEX

Spayed Female

AGE

5 Years

WEIGHT

42.8 lbs

INTERPRETED BY

Eric Lindquist, DMV,
 DABVP (CFM), Cert.
 IVUSS

IMAGING PERFORMED BY

Vicent Ravancho, CVT

HOSPITAL NAME

Animal Hospital of
 Sussex County

REFERRING VET

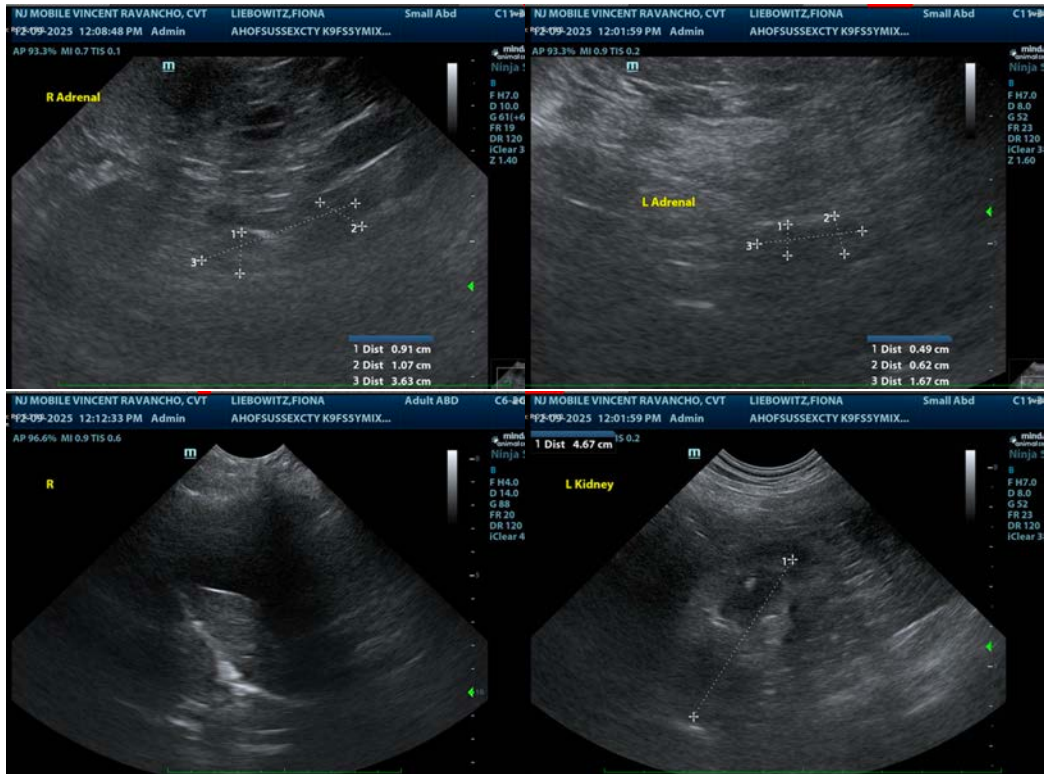
Dr. Lovell

INVOICE

72451

DATE

12/9/25



The information and recommendations provided are based on the images presented by the referring veterinarian/sonographer. No evaluation can be communicated regarding pathology that was not visible in the image/video clips provided.

Thank you for this referral. If the clinical or image interpretation does not parallel your findings or if I can be of any further assistance please contact me.

Eric Lindquist, DMV, DABVP(CFM), Cert. IVUSS,
 CEO, Owner, Founder -- SonoPath.com
info@SonoPath.com