



PATIENT

Boo Boo Hatheway

SPECIES

Canine

BREED

Toy Poodle

SEX

Spayed female

AGE

10 years

WEIGHT

11 lbs

INTERPRETED BY

Eric Lindquist, DMV
DABVP, Cert. IVUSS

IMAGING PERFORMED BY

Marie Roderiques

HOSPITAL NAME

Cape Coral Pet Vet

REFERRING VET

Dr. Vickers

INVOICE

69454

DATE

12/9/25

PRESENTING CLINICAL SIGNS

History: Urinary incontinence per owner.

ULTRASONOGRAPHIC EXAMINATION

Urinary System

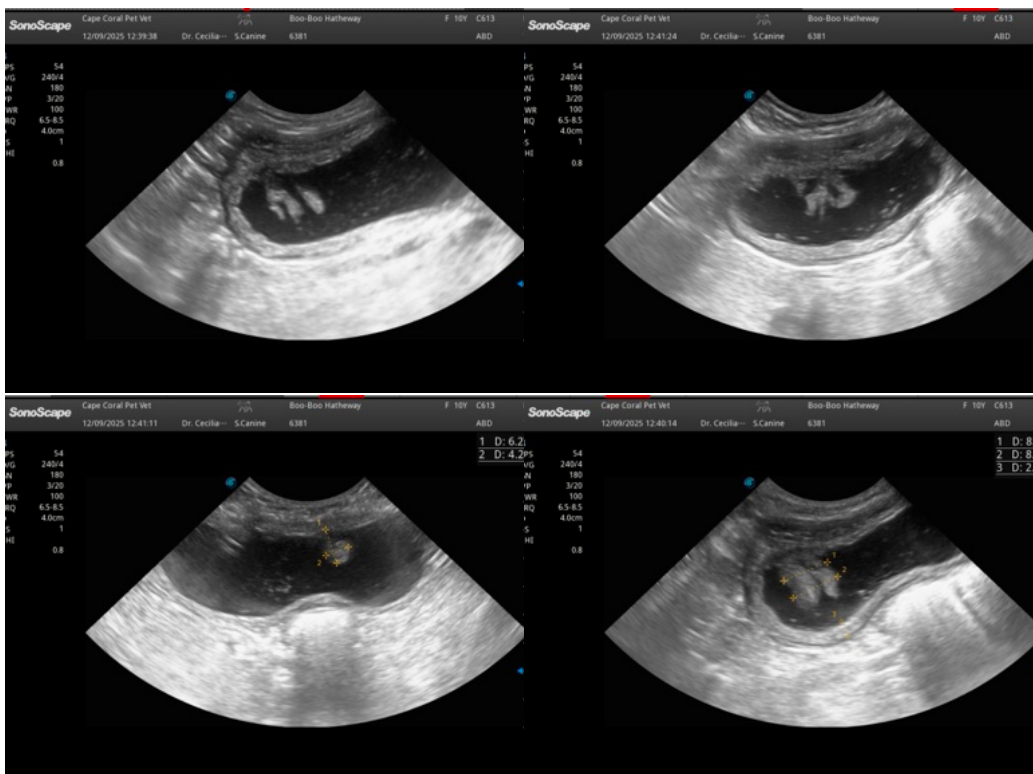
The **urinary bladder** revealed ventral apical wall thickening that measured up to 1.0 cm with polyp that measured 0.88 x 0.85 cm. A minor amount of suspended debris was noted.

ULTRASONOGRAPHIC FINDINGS

Polypoid bladder changes. Polypoid cystitis versus carcinoma are the primary concerns.

INTERPRETATION OF THE FINDINGS & FURTHER RECOMMENDATIONS

I recommend BRAF testing in this patient with cytospin of free catch urine sample and cystoscopy would all be indicated with surgical exploratory with expectations and resection of the ventral apical bladder wall. Culture and histopathology are indicated.





PATIENT

Boo Boo Hatheway

SPECIES

Canine

BREED

Toy Poodle

SEX

Spayed female

AGE

10 years

WEIGHT

11 lbs

INTERPRETED BY

Eric Lindquist, DMV
DABVP, Cert. IVUSS

IMAGING PERFORMED BY

Marie Roderiques

HOSPITAL NAME

Cape Coral Pet Vet

REFERRING VET

Dr. Vickers

INVOICE

69454

DATE

12/9/25

The information and recommendations provided are based on the images presented by the referring veterinarian/sonographer. No evaluation can be communicated regarding pathology that was not visible in the image/video clips provided.

Thank you for this referral. If the clinical or image interpretation does not parallel your findings or if I can be of any further assistance please contact me.

Eric Lindquist, DMV, DABVP (CFM), Cert. IVUSS, CEO of SonoPath.com

info@SonoPath.com