



PATIENT PRESENTING CLINICAL SIGNS

PATIENT Stella Backer **HISTORY:** Dog presented with urging to urinate. Healthy otherwise. Bloodwork in October was WNL. Urine culture pending.

SPECIES

Canine

ULTRASONOGRAPHIC EXAMINATION OF THE ABDOMEN

Urinary System

BREED

Neapolitan Mastiff

The **urinary bladder** presented chronic cystitis pattern with polypoid changes. The pelvic urethra was mildly thickened, yet uniform. There was no evidence of mineralization noted.

SEX

Spayed Female

The **kidneys** revealed largely normal size and structure, corticomedullary definition and ratio (cortex 1/3 of medulla) were essentially maintained with some age-related loss of curvilinear patterns regarding the capsule and C/M junction. The cortices presented largely uniform texture with some increased echogenicity expected for this age patient. Medullary structure differed distinctly from that of the cortex and no evidence of pelvic dilation was present. Anechoic cysts were noted and measured 3.0 cm in the medial cortex of the right kidney.

AGE

9 years

WEIGHT

109 lbs

Adrenal Glands

Both **adrenal glands** were visualized and recognized as having normal shape, size, position and echogenicity for this breed. The phrenic vasculature, glandular echogenicity and detail were unremarkable. Capsule, cortex, and medullary definition were normal for this age patient. The right adrenal gland measured 1.6 cm at the cranial pole and 0.8 cm at the caudal pole. The left adrenal gland measured 0.7 cm at the caudal pole and 0.6 cm at the cranial pole.

INTERPRETED BY

Eric Lindquist, DMV
DABVP, Cert. IVUSS

IMAGING PERFORMED BY

Dr. Leal

Spleen

The **spleen** presented a smooth homogeneous parenchyma hyperechoic to liver and renal cortical parenchyma. The capsule was smooth without noticeable expansion or deviation from within the spleen or adjacent pathology. The splenic vasculature demonstrated normal volume without signs of congestion or thrombosis. No sonographic evidence of acute or chronic inflammatory, neoplastic, or infarctual changes was noted.

HOSPITAL NAME

Blairstown AH

REFERRING VET

Dr. Leal

Liver

The **liver** images submitted revealed subjectively normal liver size, contour, and structure. Parenchymal echogenicity was naturally coarse and hypoechoic to the spleen. The hepatic veins were mildly dilated if the patient was sedated for the sonogram this would be normal. The gallbladder presented acceptably thin walls with primarily anechoic content. The cystic and common bile ducts were normal. No pathological hepatic lymphadenopathy was evident. No overt structural evidence of inflammatory, infiltrative or regenerative pathology was evident.

INVOICE

94442

DATE

12/9/21



PATIENT

Gastrointestinal

Stella Backer

Examination of the **gastrointestinal tract** revealed a stomach and intestine free of stasis, of normal wall thickness, acceptable curvilinear mural detail, and peristaltic activity. There was retention of ingesta in the stomach. Small and large intestine demonstrated normal luminal chyme and stool consistency respectively. No obstructive or overt infiltrative disease was noted. No associated abnormal lymphatic activity was noted.

SPECIES

Canine

BREED

Pancreas

Neapolitan Mastiff

The base and limbs of the **pancreas** were observed to be largely isoechoic to surrounding omental fat. Pancreatic duct and capsular contour were acceptably normal and parenchyma respected normal curvilinear patterns. No overt evidence of active inflammatory or neoplastic disease was noted.

SEX

Spayed Female

ULTRASONOGRAPHIC FINDINGS

AGE

9 years

Cystitis, urethritis pattern with a mild potential for underlying neoplasia.

Right renal cyst, appears benign.

WEIGHT

109 lbs

INTERPRETATION OF THE FINDINGS & FURTHER RECOMMENDATIONS

A cystoscopy is warranted. Culture and sensitivity and treatment for urinary tract infection is indicated over the next 3-4 weeks with a recheck sonogram.

INTERPRETED BY

Eric Lindquist, DMV
DABVP, Cert. IVUSS

IMAGING PERFORMED BY

Dr. Leal

HOSPITAL NAME

Blairstown AH

REFERRING VET

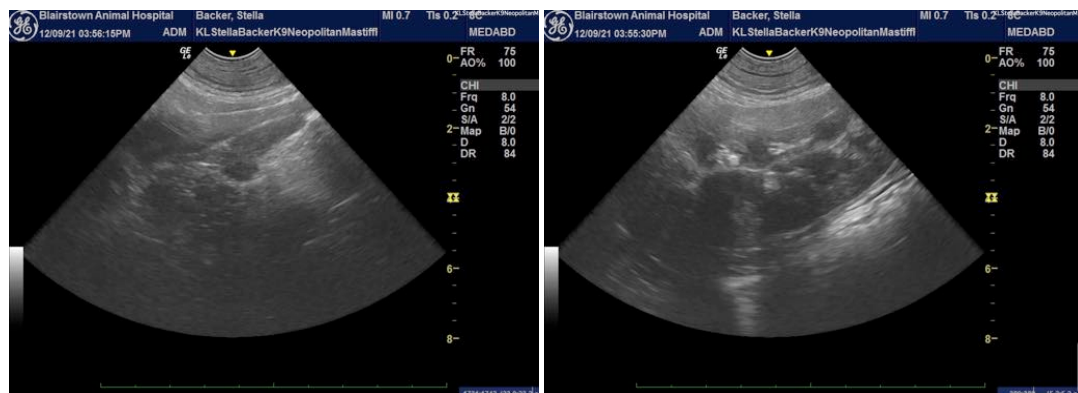
Dr. Leal

INVOICE

94442

DATE

12/9/21





PATIENT

Stella Backer

SPECIES

Canine

BREED

Neapolitan Mastiff

SEX

Spayed Female

AGE

9 years

WEIGHT

109 lbs

INTERPRETED BY

Eric Lindquist, DMV
DABVP, Cert. IVUSS

IMAGING PERFORMED BY

Dr. Leal

HOSPITAL NAME

Blairstown AH

REFERRING VET

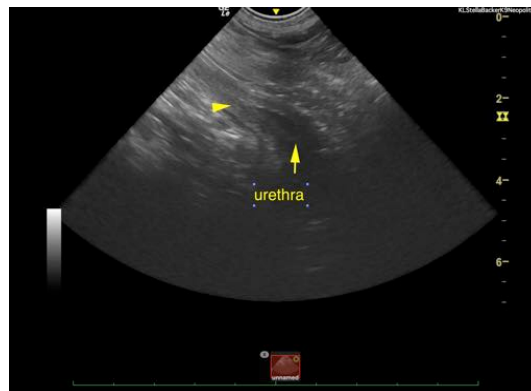
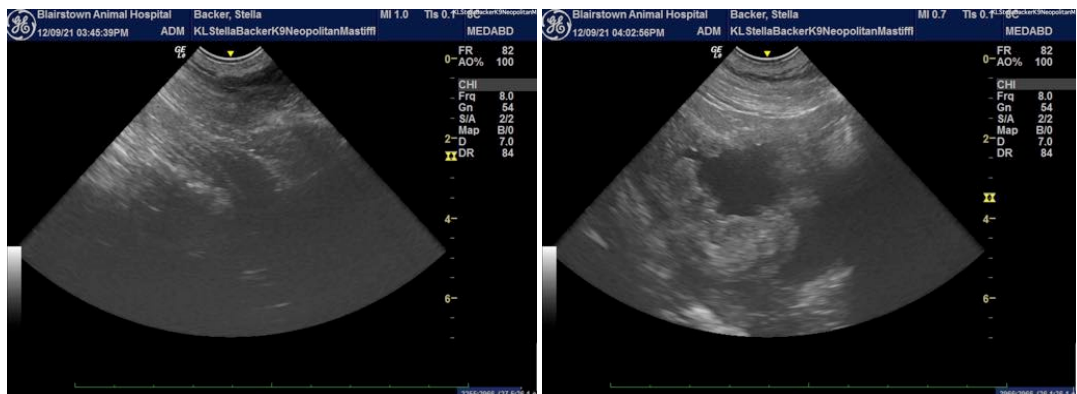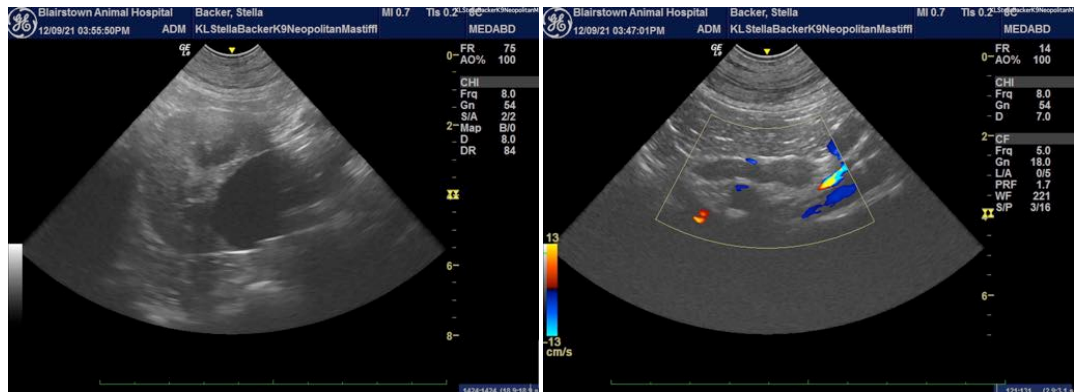
Dr. Leal

INVOICE

94442

DATE

12/9/21



The information and recommendations provided are based on the images presented by the referring veterinarian. No evaluation can be communicated regarding pathology that was not visible in the image/video clips provided.

Thank you for this referral. If the clinical or image interpretation does not parallel your findings or if I can be of any further assistance please contact me.



PATIENT

Eric Lindquist, DMV, DABVP, Cert. IVUSS, CEO of SonoPath.com
info@SonoPath.com

Stella Backer

SPECIES

Canine

BREED

Neapolitan Mastiff

SEX

Spayed Female

AGE

9 years

WEIGHT

109 lbs

INTERPRETED BY

Eric Lindquist, DMV
DABVP, Cert. IVUSS

**IMAGING
PERFORMED BY**

Dr. Leal

HOSPITAL NAME

Blairstown AH

REFERRING VET

Dr. Leal

INVOICE

94442

DATE

12/9/21