



**PATIENT PRESENTING CLINICAL SIGNS**

Phoebe Douma lethargy, anorexia, hypoglycemic. R/O pyometra vs other. On enrofloxacin and PenG  
Abnormal PE/Chem/CBC/UA Results: glucose 42, tbili 0.4, ccreat 1.8, T4 low 0.5. CBC wnl

**SPECIES ULTRASONOGRAPHIC EXAMINATION OF THE ABDOMEN**

Canine

**Urinary System**

**BREED**

Mixed

The **bladder** in this patient was mildly thickened with slight echogenic mural changes. No calculi or masses were noted. Slight micropolypoid changes were noted. This is a frequent finding in older animals and may be linked to a history of chronic urinary tract infection or active urinary tract infection. Urinalysis would be recommended with culture if any evidence of inflammatory sediment is present. The region of the trigone and visible pelvic urethra were normal.

**SEX**

Intact Female

The **kidneys** revealed largely normal size and structure, corticomedullary definition and ratio (cortex 1/3 of medulla) were essentially maintained with some age-related loss of curvilinear patterns regarding the capsule and C/M junction. The cortices presented largely uniform texture with some increased echogenicity expected for his age patient. Medullary structure differed distinctly from that of the cortex. The right kidney measured 4.46 cm with slight pyelectasia noted. The left kidney measured 3.64 cm.

**AGE**

11 Years

**Adrenal Glands**

**WEIGHT**

8.3 Pounds

Both **adrenal glands** were visualized and recognized as having normal shape, size, position and echogenicity for this breed. The phrenic vasculature, glandular echogenicity and detail were unremarkable. Capsule, cortex, and medullary definition were normal for this age patient. The left adrenal gland measured 1.8 cm x 0.66 cm at the caudal pole and 0.61 cm at the cranial pole. The right adrenal gland measured 1.63 cm x 0.44 cm at the caudal pole and 0.74 cm at the cranial pole.

**INTERPRETED BY**

Eric Lindquist, DMV  
DABVP, Cert. IVUSS

**Spleen**

**IMAGING PERFORMED BY**

Diane McFadden

The **spleen** presented a smooth homogeneous parenchyma hyperechoic to liver and renal cortical parenchyma. The capsule was smooth without noticeable expansion or deviation from within the spleen or adjacent pathology. The splenic vasculature demonstrated normal volume without signs of congestion or thrombosis. No sonographic evidence of acute or chronic inflammatory, neoplastic, or infarctual changes were noted.

**HOSPITAL NAME**

Andover AH

**Liver**

**REFERRING VET**

Dr. Hummel

The **liver** images from right and left intercostal as well as subcostal views revealed subjectively normal liver size, contour, and structure. Some age-related parenchymal remodeling was noted but likely not clinically significant at this time. Vascular and biliary tracts were of normal volume and no evidence of congestion was noted. The gallbladder presented some dependent debris with essentially normal contour. The cystic and common bile ducts were normal. No overt evidence of active inflammatory, infiltrative or regenerative pathology was noted but should be paired with current or past LE elevations regarding any clinical significance to this presentation. The hepatic lymph nodes were unremarkable.

**INVOICE**

33353

**Gastrointestinal**

The **stomach** was filled with anechoic fluid. The small intestine and colon were unremarkable.

**DATE**

12/9/21

**Pancreas**

Minor heterogeneous **pancreatic** changes noted. Chronic active inflammation suspected, low-grade.



**PATIENT**

*Other*

Phoebe Douma

The uterus was particularly thickened in this patient, hypoechoic and irregular. Periserosal inflammatory pattern noted. The remainder of the uterus presented microcystic changes in both horns. The uterus at maximum width measured 1.3 cm. Slight free fluid noted around the uterine horns, and reactive mesentery.

**SPECIES**

Canine

**ULTRASONOGRAPHIC FINDINGS**

**BREED**

Mixed

- Chronic metritis with hyperplasia pattern – open pyometra likely.
- Concurrent pancreatitis/gastritis

**SEX**

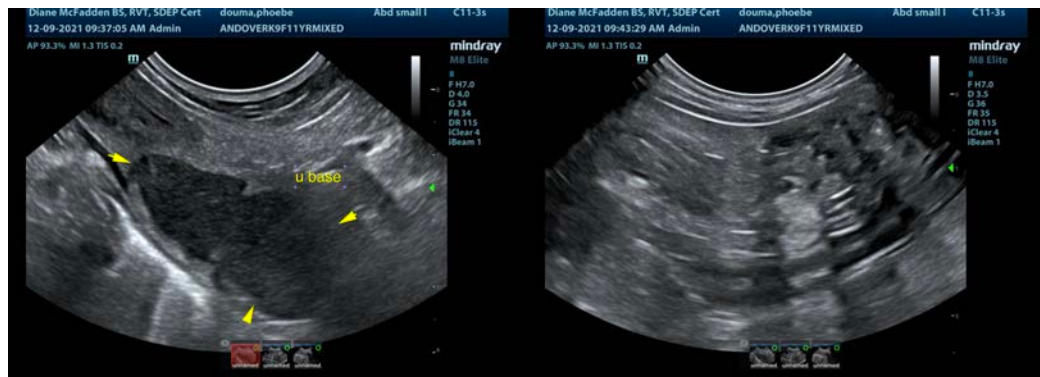
Intact Female

**INTERPRETATION OF THE FINDINGS & FURTHER RECOMMENDATIONS**

IV fluid support and ovariohysterectomy recommended. The cause of hypoglycemia is unclear and may be owing to sepsis. No obvious evidence of insulinoma noted, yet could not be completely ruled out, as these can be extremely small lesions. There is a mild potential for uterine neoplasia in this patient. The ovariohysterectomy should be performed to the level of the cervix, and biopsy of the base of the uterus is indicated.

**AGE**

11 Years



**WEIGHT**

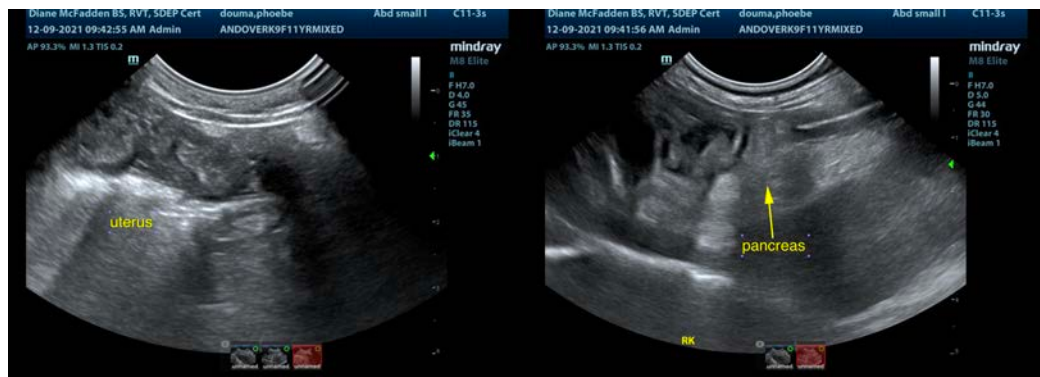
8.3 Pounds

**INTERPRETED BY**

Eric Lindquist, DMV  
DABVP, Cert. IVUSS

**IMAGING PERFORMED BY**

Diane McFadden



**HOSPITAL NAME**

Andover AH

**REFERRING VET**

Dr. Hummel

**INVOICE**

33353

**DATE**

12/9/21



**PATIENT**

Phoebe Douma

**SPECIES**

Canine

**BREED**

Mixed

**SEX**

Intact Female

**AGE**

11 Years

**WEIGHT**

8.3 Pounds

**INTERPRETED BY**

Eric Lindquist, DMV  
DABVP, Cert. IVUSS

**IMAGING PERFORMED BY**

Diane McFadden

**HOSPITAL NAME**

Andover AH

**REFERRING VET**

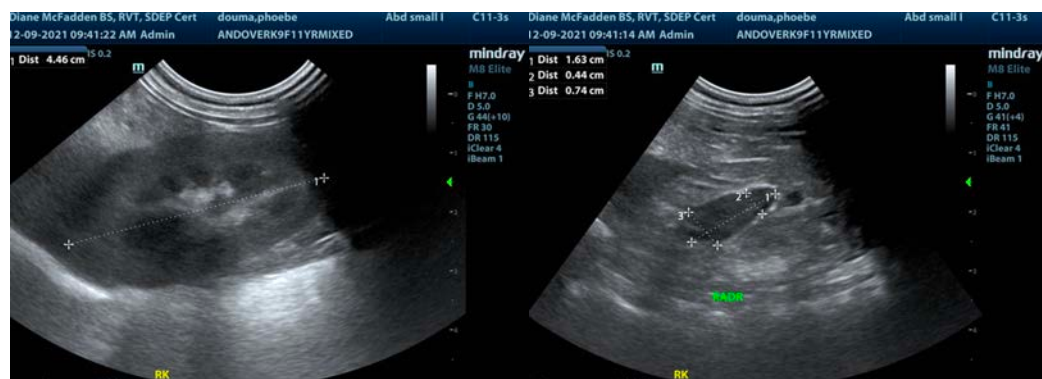
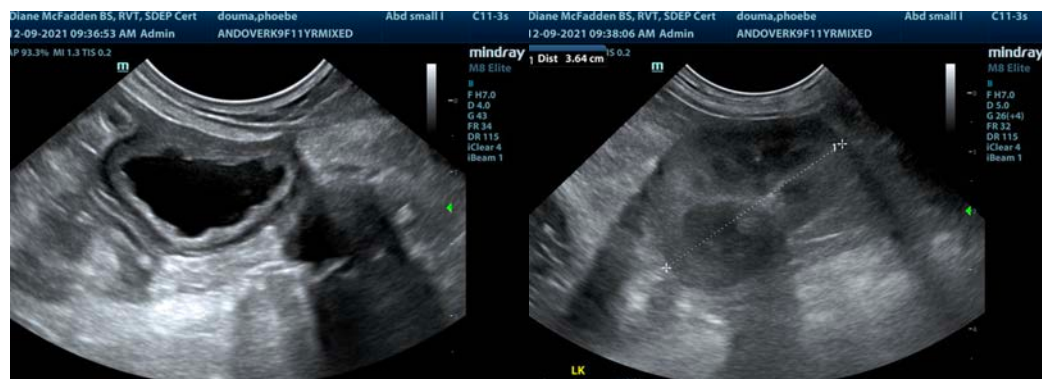
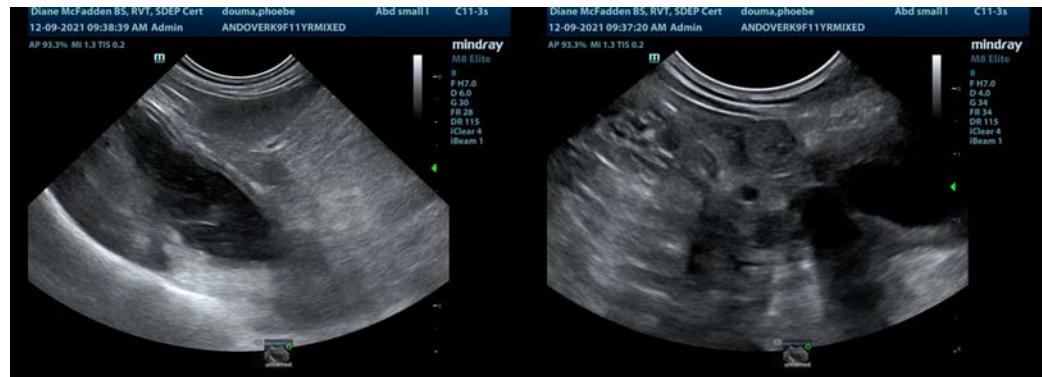
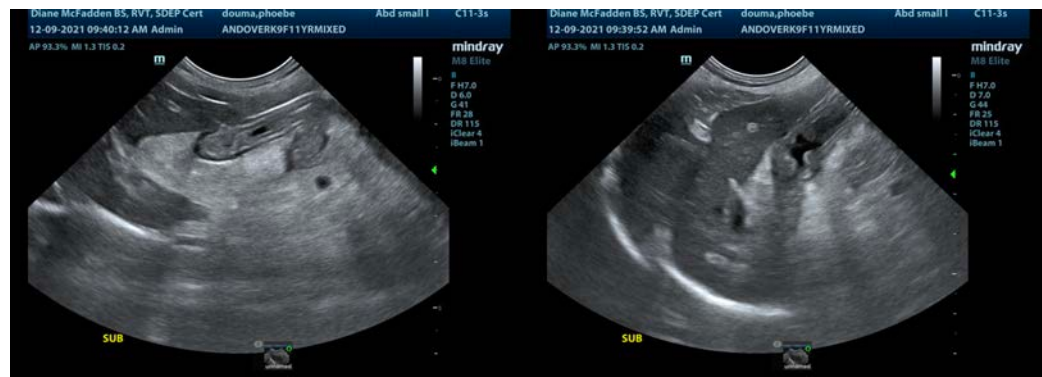
Dr. Hummel

**INVOICE**

33353

**DATE**

12/9/21





**PATIENT**

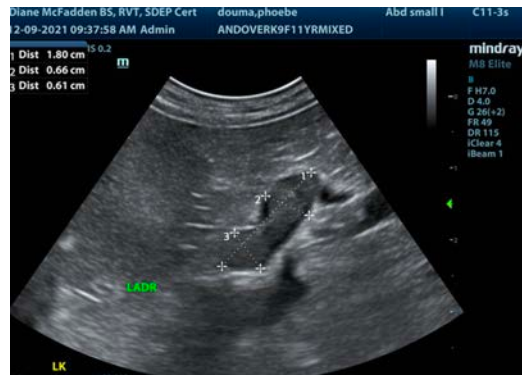Phoebe Douma

**SPECIES**

Canine

**BREED**

Mixed



**SEX**

Intact Female

The information and recommendations provided are based on the images presented by the referring veterinarian. No evaluation can be communicated regarding pathology that was not visible in the image/video clips provided.

**AGE**

11 Years

Thank you for this referral. If the clinical or image interpretation does not parallel your findings or if I can be of any further assistance please contact me.

**WEIGHT**

8.3 Pounds

**Eric Lindquist, DMV, DABVP, Cert. IVUSS, CEO of SonoPath.com**  
[info@SonoPath.com](mailto:info@SonoPath.com)

**INTERPRETED BY**

Eric Lindquist, DMV  
DABVP, Cert. IVUSS

**IMAGING PERFORMED BY**

Diane McFadden

**HOSPITAL NAME**

Andover AH

**REFERRING VET**

Dr. Hummel

**INVOICE**

33353

**DATE**

12/9/21