



PATIENT

Kurumi Pearce

SPECIES

Canine

BREED

Shih Tzu

SEX

Spayed Female

AGE

16 years

WEIGHT

12.6 lbs

INTERPRETED BY

Eric Lindquist, DMV
DABVP, Cert. IVUSS

IMAGING PERFORMED BY

Dr. Preston

HOSPITAL NAME

All Creatures AH SH

REFERRING VET

Dr. Preston

INVOICE

94463

DATE

12/9/21

PRESENTING CLINICAL SIGNS

History: Previous history of adrenal mass and mildly elevated liver enzymes. Liver enzymes have increased in past 4 months: August 2021 now ALT 159 506 ALP 731 1283 AST 33 75 GGT 15 9

ULTRASONOGRAPHIC EXAMINATION OF THE ABDOMEN

Urinary System

The **urinary bladder**, trigone, and pelvic urethra presented normal thicknesses and normal tone. The ureters were not visible which is normal. No uroliths or sediment were visualized and anechoic urine was present. No evidence of inflammatory or neoplastic changes was noted. Ureteral papillae were normal.

The left **kidney** revealed significant polycystic changes and moderate degenerative pattern. The left kidney measured 3.0 cm with 1.4 cm of embedded pelvic calculi. The right kidney revealed similar polycystic changes with calculi. The right kidney measured 3.0 cm.

Adrenal Glands

The left **adrenal gland** was visualized and recognized as having normal shape, size, position and echogenicity for this breed. The phrenic vasculature, glandular echogenicity and detail were unremarkable. Capsule, cortex, and medullary definition were normal for this age patient. The left adrenal gland measured 0.6 cm. The region of the right adrenal gland was unremarkable.

Spleen

The **spleen** presented a smooth homogeneous parenchyma hyperechoic to liver and renal cortical parenchyma. The capsule was smooth without noticeable expansion or deviation from within the spleen or adjacent pathology. The splenic vasculature demonstrated normal volume without signs of congestion or thrombosis. No sonographic evidence of acute or chronic inflammatory, neoplastic, or infarctual changes was noted.

Liver

The **liver** was uniformly swollen with minor, excessive gallbladder debris and over distension with dependent and suspended bile without evidence of overt mucocele formation. However, excessive sludge was present. The liver presented coarse architecture with mildly increased portal markings and subtle, mixed echogenic changes. This is consistent with vacuolar hepatopathy and some level of remodeling and history of inflammatory component. There was no overt suspicion of neoplasia.

Gastrointestinal

Examination of the **gastrointestinal tract** revealed a stomach and intestine free of stasis, of normal wall thickness, acceptable curvilinear mural detail, and peristaltic activity. Small and large intestine



PATIENT

Kurumi Pearce

demonstrated normal luminal chyme and stool consistency respectively. No obstructive or overt infiltrative disease was noted. No associated abnormal lymphatic activity was noted.

SPECIES

Canine

Pancreas

The base and limbs of the **pancreas** were observed to be largely isoechoic to surrounding omental fat. Pancreatic duct and capsular contour were acceptably normal and parenchyma respected normal curvilinear patterns. No overt evidence of active inflammatory or neoplastic disease was noted.

BREED

Shih Tzu

ULTRASONOGRAPHIC FINDINGS

SEX

Spayed Female

Polycystic kidneys with calculi.

Benign hepatopathy.

Bladder/urethral sand.

AGE

16 years

INTERPRETATION OF THE FINDINGS & FURTHER RECOMMENDATIONS

The kidneys appear subjectively near end stage. Renal function should be monitored carefully. I am assuming that the right adrenal gland has been removed. However, I most concerned about the renal function in this patient.

WEIGHT

12.6 lbs

INTERPRETED BY

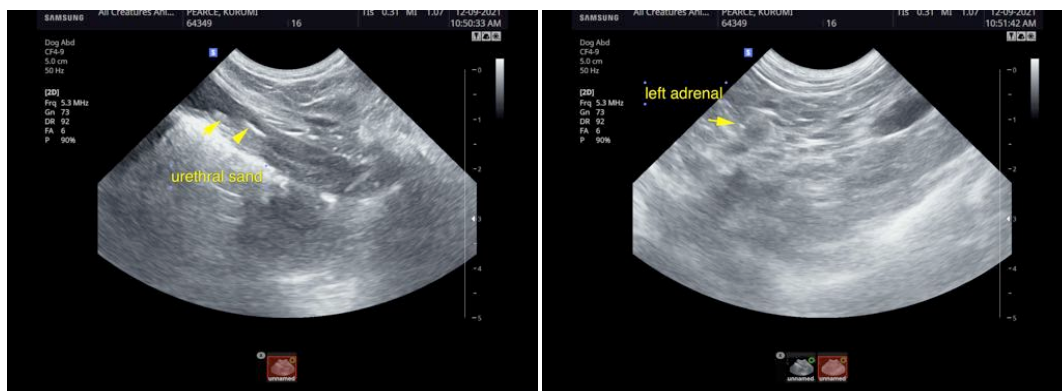
Eric Lindquist, DMV
DABVP, Cert. IVUSS

IMAGING PERFORMED BY

Dr. Preston

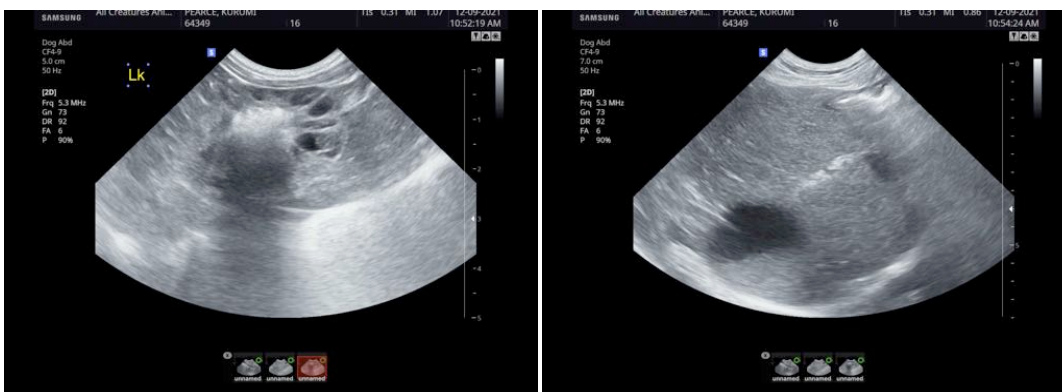
HOSPITAL NAME

All Creatures AH SH



REFERRING VET

Dr. Preston



INVOICE

94463

DATE

12/9/21



PATIENT

Kurumi Pearce

SPECIES

Canine

BREED

Shih Tzu

SEX

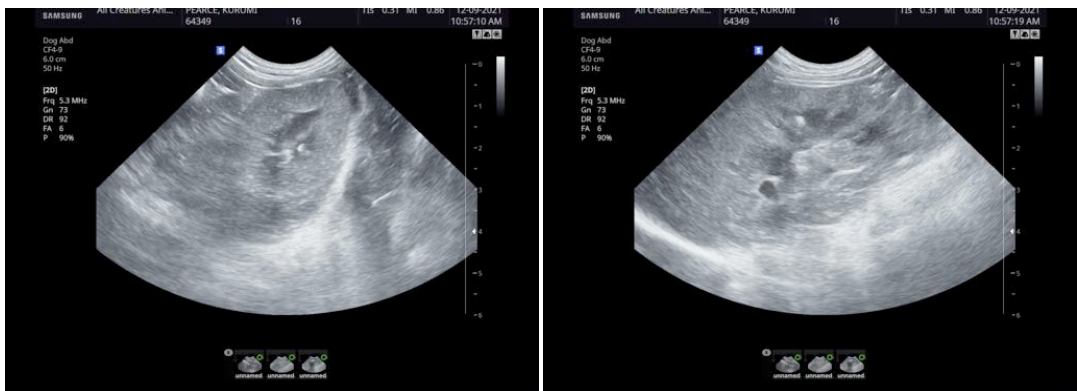
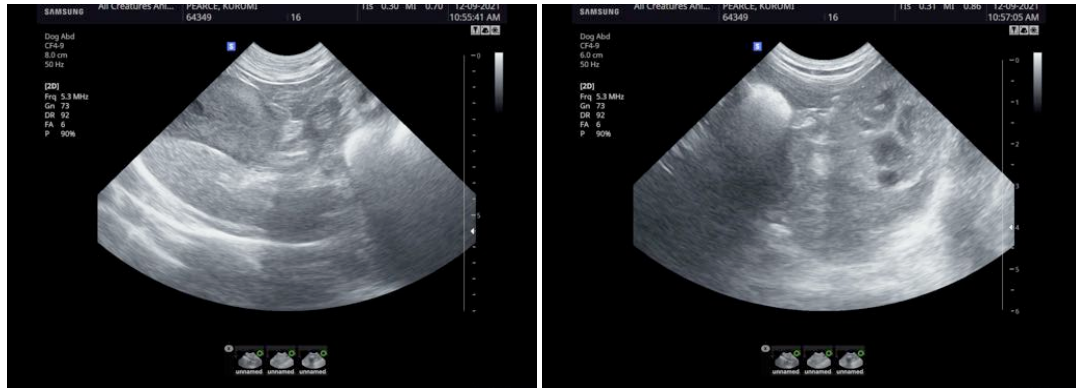
Spayed Female

AGE

16 years

WEIGHT

12.6 lbs



INTERPRETED BY

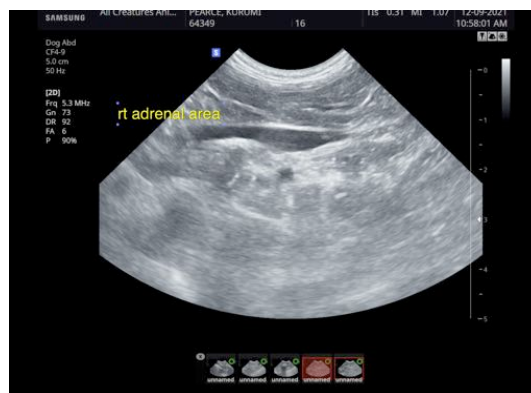Eric Lindquist, DMV
DABVP, Cert. IVUS

IMAGING PERFORMED BY

Dr. Preston

HOSPITAL NAME

All Creatures AH SH



REFERRING VET

Dr. Preston

INVOICE

94463

DATE

12/9/21

The information and recommendations provided are based on the images presented by the referring veterinarian. No evaluation can be communicated regarding pathology that was not visible in the image/video clips provided.

Thank you for this referral. If the clinical or image interpretation does not parallel your findings or if I can be of any further assistance please contact me.



PATIENT

Eric Lindquist, DMV, DABVP, Cert. IVUSS, CEO of SonoPath.com
info@SonoPath.com

Kurumi Pearce

SPECIES

Canine

BREED

Shih Tzu

SEX

Spayed Female

AGE

16 years

WEIGHT

12.6 lbs

INTERPRETED BY

Eric Lindquist, DMV
DABVP, Cert. IVUSS

**IMAGING
PERFORMED BY**

Dr. Preston

HOSPITAL NAME

All Creatures AH SH

REFERRING VET

Dr. Preston

INVOICE

94463

DATE

12/9/21