

**DATE**

12/9/21

**PRESENTING CLINICAL SIGNS**

History: random 6-hour period of very obvious jaundice yesterday in his mucous membranes, normal behavior otherwise.

**PATIENT**

Jackson Klimovitz

Current Medications: Palladia 80mg - MWF x 4 weeks, Piroxicam 10mg - T/TH/Sa/Sun x 5 weeks, Pantoprazole 80mg SID x 5 weeks, Pimobendan 10mg AM, 5mg PM x 4 years, Sucralfate 1gram BID x 4 weeks, Cerenia 80mg PRN.

Lab Results: Attached separately.

Date of Previous IntraPet Ultrasound: 10-28-2021.

Sedation: Not required to complete full diagnostic ultrasound.

Stat Report: Not requested.

**SPECIES**

Canine

**BREED**American Bulldog  
Boxer Mix**SEX**

Neutered male

**AGE**

3/15/09

**WEIGHT**

80 lbs

**INTERPRETED BY**Eric Lindquist, DMV  
DABVP, Cert. IVUSS**IMAGING PERFORMED BY**

Rachel Brillhart RDMS

**HOSPITAL NAME**

Stay Pet Veterinary

**REFERRING VET**

Dr. Klimovitz

**INVOICE**

94453

**ULTRASONOGRAPHIC EXAMINATION OF THE ABDOMEN****Urinary System**

The **urinary bladder**, trigone, and pelvic urethra presented normal thicknesses and normal tone. The ureters were not visible which is normal. No uroliths or sediment were visualized and anechoic urine was present. No evidence of inflammatory or neoplastic changes was noted. Ureteral papillae were normal.

The **kidneys** revealed normal size and structure, corticomedullary definition and ratio for this age. The cortices presented largely uniform texture with normal echogenic relationship to liver and spleen. Medullary structure differed distinctly from the cortex and no evidence of pelvic dilation was present. The capsules were acceptably uniform without significant irregularities. The left kidney measured 7.44 cm. The right kidney measured 6.88 cm.

**Adrenal Glands**

Both **adrenal glands** were visualized and recognized as having normal shape, size, position and echogenicity for this breed. The phrenic vasculature, glandular echogenicity and detail were unremarkable. Capsule, cortex, and medullary definition were normal for this age patient. The left adrenal gland measured 2.24 x 0.56 cm at the caudal pole and 0.62 cm at the cranial pole. The right adrenal gland measured 2.26 x 0.65 cm at the caudal pole and 0.68 cm at the cranial pole.

**Spleen**

The **spleen** revealed multi-focal, hypoechoic nodular changes. The changes are less dramatic compared to the prior sonogram.

**Liver**

The **liver** revealed coarse architecture and minor lacey parenchyma. Slightly increased portal markings were noted. The nodular changes noted on the prior sonogram are no longer present. This is indicative of response to therapy. The gallbladder and common bile duct were unremarkable.

**Gastrointestinal**

Examination of the **gastrointestinal tract** revealed a stomach and intestine free of stasis, of normal wall thickness, acceptable curvilinear mural detail, and peristaltic activity. Small and large intestine demonstrated normal luminal chyme and stool consistency respectively. The mesenteric root lymph node was enlarged and measured 1.88 x 0.85 cm. Sublumbar lymph node was noted and measured 4.9 x 2.3 cm. The lymph node was coarse and heterogenous. This is consistent with partial remission.

### **Pancreas**

The base and limbs of the **pancreas** were observed to be largely isoechoic to surrounding omental fat. Pancreatic duct and capsular contour were acceptably normal and parenchyma respected normal curvilinear patterns. No overt evidence of active inflammatory or neoplastic disease was noted.

### **Thorax**

The thorax revealed a persistent lymph node mass that measured 5.37 x 2.28 cm.

### **ULTRASONOGRAPHIC FINDINGS**

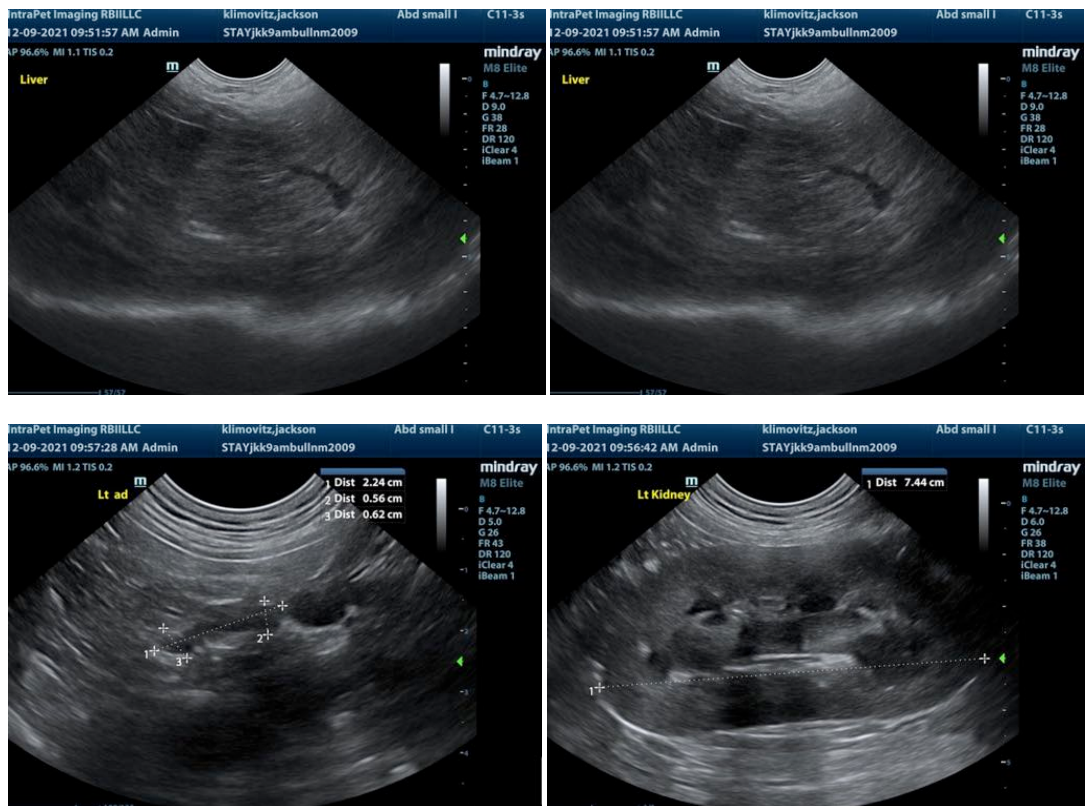
Partial remission presentation with persistent lymphadenopathy.

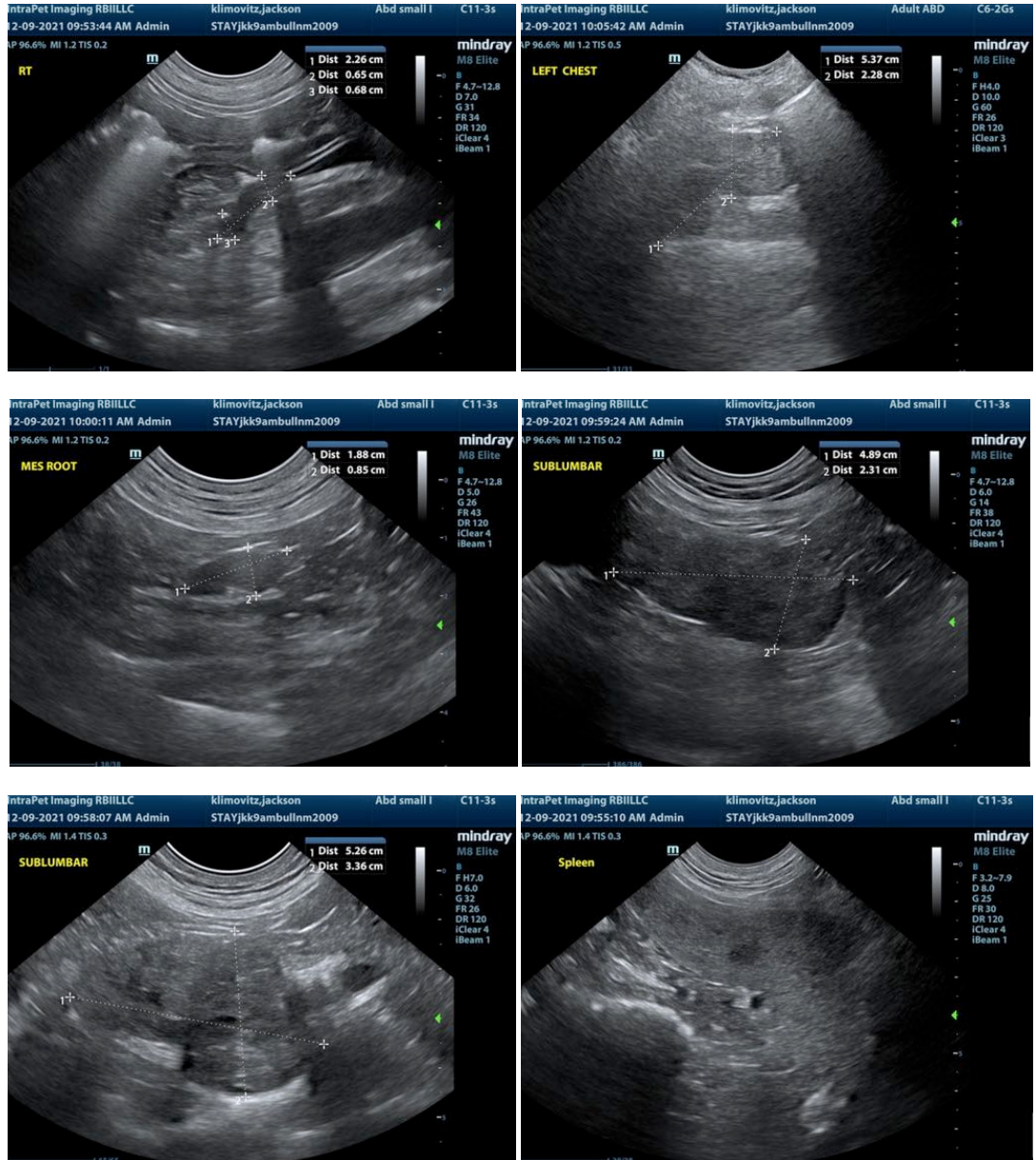
Abdominal and cranial mediastinal lymphadenopathy.

Heterogenous hepatic and splenic patterns, yet significant reduced in disruptive architecture compared to the prior sonogram.

### **INTERPRETATION OF THE FINDINGS & FURTHER RECOMMENDATIONS**

It is recommended to continue with the current therapy.





The information and recommendations provided are based on the images presented by the referring veterinarian. No evaluation can be communicated regarding pathology that was not visible in the image/video clips provided.

Thank you for this referral. If the clinical or image interpretation does not parallel your findings or if I can be of any further assistance please contact me.

**Eric Lindquist, DMV, DABVP, Cert. IVUSS, CEO of SonoPath.com**  
 Eric.Lindquist@SonoPath.com