



PATIENT

Gunner Kappel

SPECIES

Canine

BREED

Basset Hound

SEX

Neutered male

AGE

9 years

WEIGHT

24 kg

INTERPRETED BY

Eric Lindquist, DMV
DABVP, Cert. IVUSS

IMAGING PERFORMED BY

Dr. Jameson

HOSPITAL NAME

Sylvan Lake VC

REFERRING VET

Dr. Jameson

INVOICE

94440

DATE

12/9/21

PRESENTING CLINICAL SIGNS

History: Increased drinking, vomiting on and off, dental disease, shaking on and off. Eating normally at home
Chem: SDMA slightly elevated, SG 1.020, urine normal CBC: RBC high normal

ULTRASONOGRAPHIC EXAMINATION OF THE ABDOMEN

Urinary System

The **urinary bladder**, trigone, and pelvic urethra presented normal thicknesses and normal tone. The ureters were not visible which is normal. No uroliths or sediment were visualized and anechoic urine was present. No evidence of inflammatory or neoplastic changes was noted. Ureteral papillae were normal.

The **kidneys** revealed normal size and structure, corticomedullary definition and ratio for this age. The cortices presented largely uniform texture with normal echogenic relationship to liver and spleen. Medullary structure differed distinctly from the cortex and no evidence of pelvic dilation was present. The capsules were acceptably uniform without significant irregularities. The right kidney measured 5.0 cm. The left kidney measured 5.0 cm.

Adrenal Glands

The **adrenal glands** were not visualized.

Spleen

The **spleen** in this patient was mildly enlarged with uniform parenchyma and was folded upon itself cranially. This is a positional variant and is not pathological. There was no evidence of significant disease.

Liver

The **liver** images from right and left intercostal as well as subcostal views revealed subjectively normal liver size, contour, and structure. Some age-related parenchymal remodeling was noted but likely not clinically significant at this time. Vascular and biliary tracts were of normal volume and no evidence of congestion was noted. The gallbladder presented some dependent debris with essentially normal contour. The cystic and common bile ducts were normal. No overt evidence of active inflammatory, infiltrative or regenerative pathology was noted but should be paired with current or past LE elevations regarding any clinical significance to this presentation. The hepatic lymph nodes were unremarkable.

Gastrointestinal

Examination of the **gastrointestinal tract** revealed a stomach and intestine free of stasis, of normal wall thickness, acceptable curvilinear mural detail, and peristaltic activity. Small and large intestine demonstrated normal luminal chyme and stool consistency respectively. No obstructive or overt infiltrative disease was noted. No associated abnormal lymphatic activity was noted.



PATIENT

Gunner Kappel

Pancreas

SPECIES

Canine

The base and limbs of the **pancreas** were observed to be largely isoechoic to surrounding omental fat. Pancreatic duct and capsular contour were acceptably normal and parenchyma respected normal curvilinear patterns. No overt evidence of active inflammatory or neoplastic disease was noted.

BREED

Basset Hound

ULTRASONOGRAPHIC FINDINGS

Structurally unremarkable abdomen.

SEX

Neutered male

INTERPRETATION OF THE FINDINGS & FURTHER RECOMMENDATIONS

There was no evidence of pathology. Dietary indiscretion, food intolerance/indiscretion, structurally insignificant inflammatory bowel or occult parasitism and occult Addison's are all potentials. Screening for Addison's is warranted given the vague patient's history.

AGE

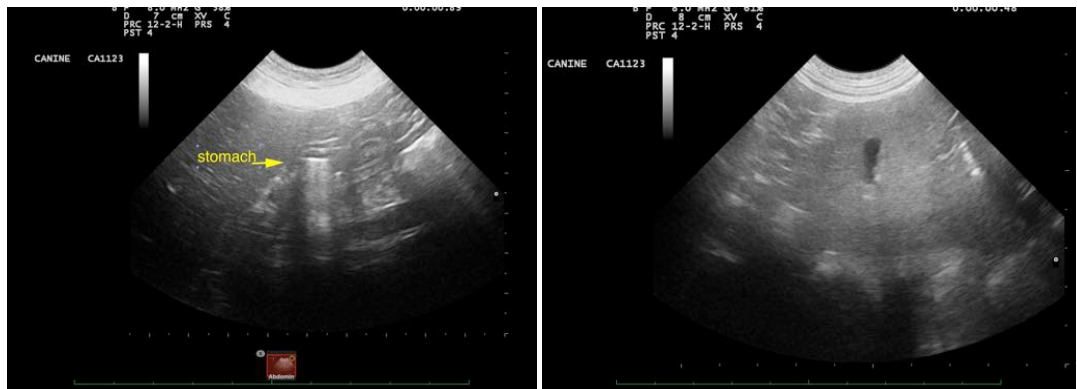
9 years

WEIGHT

24 kg

INTERPRETED BY

Eric Lindquist, DMV
DABVP, Cert. IVUSS

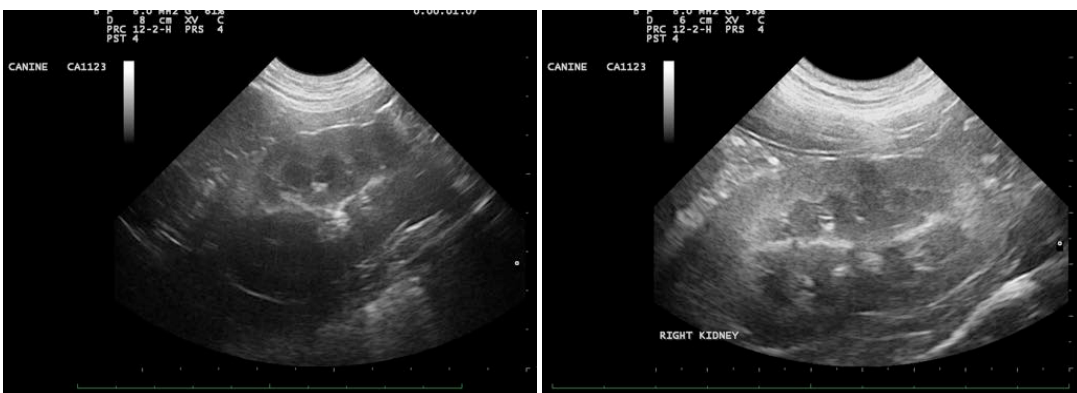

IMAGING PERFORMED BY

Dr. Jameson

HOSPITAL NAME

Sylvan Lake VC



REFERRING VET

Dr. Jameson

INVOICE

94440

DATE

12/9/21



PATIENT

Gunner Kappel

SPECIES

Canine

BREED

Basset Hound

SEX

Neutered male

AGE

9 years

WEIGHT

24 kg

INTERPRETED BY

Eric Lindquist, DMV
DABVP, Cert. IVUSS

**IMAGING
PERFORMED BY**

Dr. Jameson

HOSPITAL NAME

Sylvan Lake VC

REFERRING VET

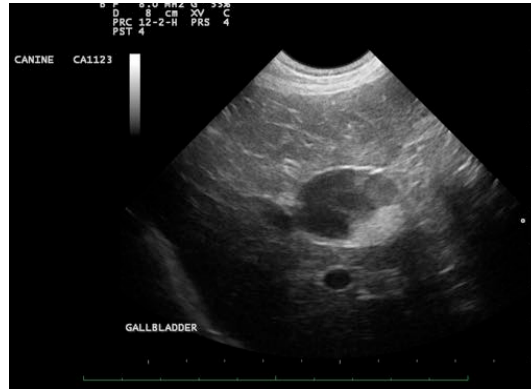Dr. Jameson

INVOICE

94440

DATE

12/9/21



The information and recommendations provided are based on the images presented by the referring veterinarian. No evaluation can be communicated regarding pathology that was not visible in the image/video clips provided.

Thank you for this referral. If the clinical or image interpretation does not parallel your findings or if I can be of any further assistance please contact me.

Eric Lindquist, DMV, DABVP, Cert. IVUSS, CEO of SonoPath.com
info@SonoPath.com