



PATIENT

Gracie Wolfe

SPECIES

Canine

BREED

Lab X

SEX

Spayed Female

AGE

12 Years

WEIGHT

48.8 Pounds

PRESENTING CLINICAL SIGNS

Follow-up echo, last one performed in 2020; mitral/tricuspid/pulmonary insufficiency and mildly decreased contractility. Current meds: Pimobendan 5 mgs BID, enalapril 10 mgs BID, . Due for recheck blood work but NSF on last year's. ECG after last year's echo was WNL.

ULTRASONOGRAPHIC EXAMINATION OF THE HEART

CANINE CARDIAC PARAMETERS	MR VMAX (m/s)	TR VMAX (m/s)	LA/AO (Boon method)	LA/AO (Heart Base; Swe)	FS (%)	EF (%)	EPSS (cm)
NORMAL PARAMETER	4.5-5.5	<2.7	1.3	<1.6	28-40	40-100	<0.6
PATIENT			1.2	1.2	18	39	0.54
CANINE CARDIAC PARAMETERS	HR (BPM)	AV VMAX (m/s)	PV MAX (m/s)	BODY WEIGHT (kg)	LA 2D short axis Base view (cm)	LVIDd Avg; 2D and m-mode short axis (cm)	LVIDs Avg; 2D and m-mode short axis (cm)
NORMAL PARAMETER	50-100	0.7-1.7	0.7-1.6				
PATIENT		0.9	0.85		3.58	3.2	

INTERPRETED BY

Eric Lindquist, DMV
DABVP, Cert. IVUS

IMAGING PERFORMED BY

Kelly Vazquez

HOSPITAL NAME

Midland Park VH

REFERRING VET

Dr. John Shokoff

INVOICE

33374

DATE

12/9/21

Cardiac Presentation

The cardiac presentation in this patient revealed a 3.05 cm x 2.2 cm hypoechoic heart base mass that appeared to infiltrate around the aorta and pulmonary outflow. Contractility was subnormal. Internal chamber volumes were unremarkable. Mitral insufficiency was present with peripheral jet. No pericardial or pleural effusion noted. Trivial pulmonic insufficiency present. Tricuspid insufficiency also noted. No hepatic vein dilation present.

ULTRASONOGRAPHIC FINDINGS

- Heart Base mass – suspect chemodectoma/aortic body tumor

INTERPRETATION OF THE FINDINGS & FURTHER RECOMMENDATIONS

No specific therapy warranted in this patient at this time. However, blood pressure measurements are recommended. These are typically slow growing masses, and this is a new development compared to the prior sonogram. The valvular disease is compensated on the current protocol.



PATIENT

Gracie Wolfe

SPECIES

Canine

BREED

Lab X

SEX

Spayed Female

AGE

12 Years

WEIGHT

48.8 Pounds

INTERPRETED BY

Eric Lindquist, DMV
DABVP, Cert. IVUS

IMAGING PERFORMED BY

Kelly Vazquez

HOSPITAL NAME

Midland Park VH

REFERRING VET

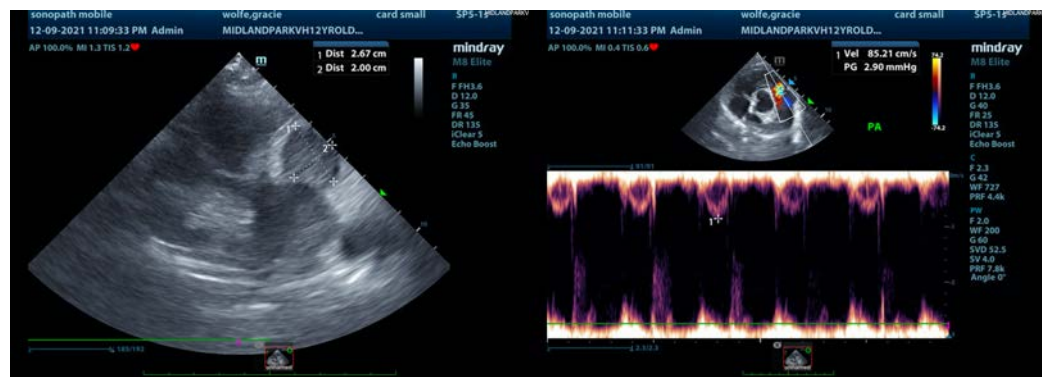
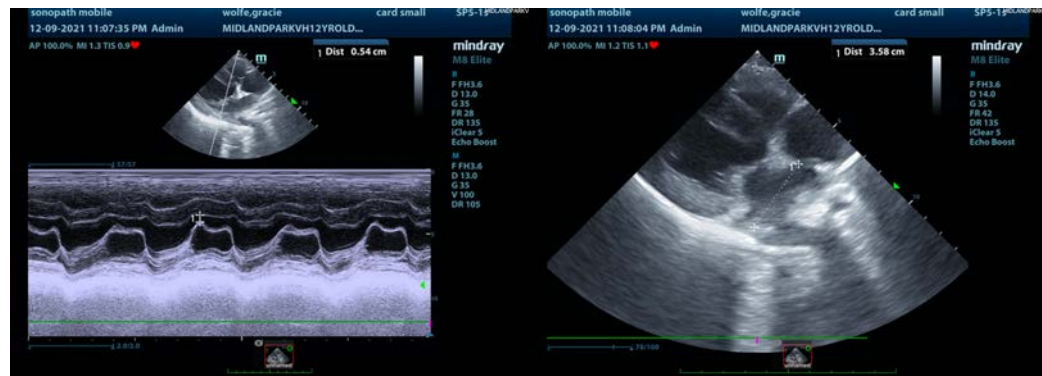
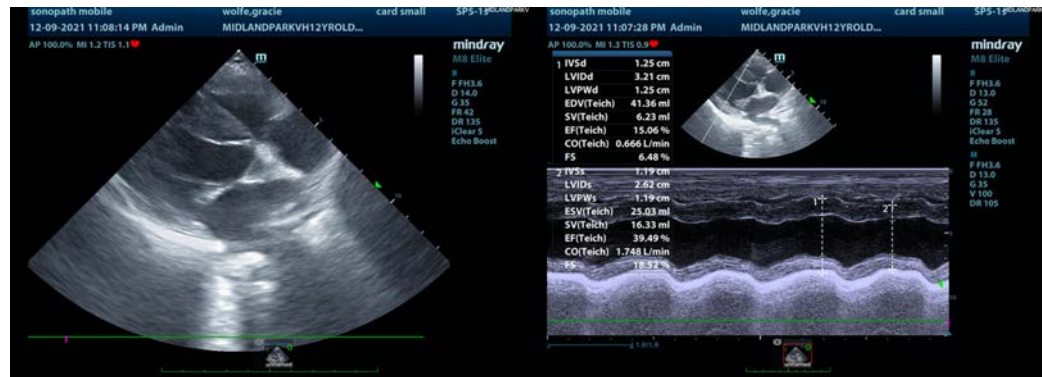
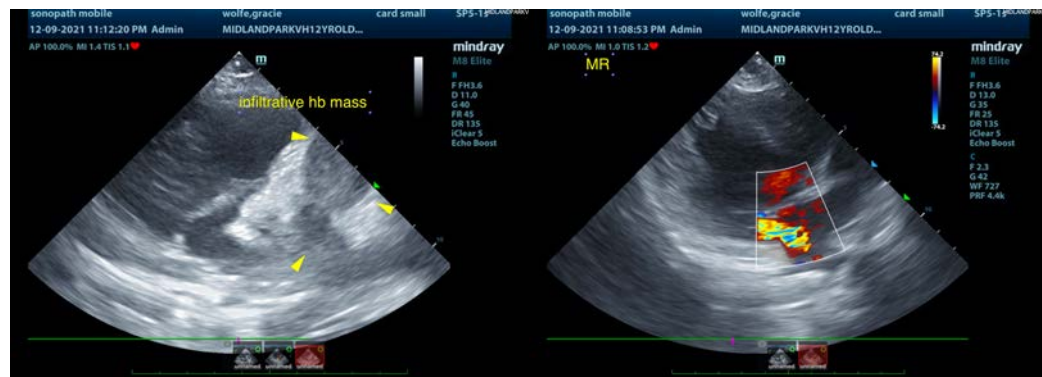
Dr. John Shokoff

INVOICE

33374

DATE

12/9/21





PATIENT

Gracie Wolfe

SPECIES

Canine

BREED

Lab X

SEX

Spayed Female

AGE

12 Years

WEIGHT

48.8 Pounds

INTERPRETED BY

Eric Lindquist, DMV
DABVP, Cert. IVUSS

**IMAGING
PERFORMED BY**

Kelly Vazquez

HOSPITAL NAME

Midland Park VH

REFERRING VET

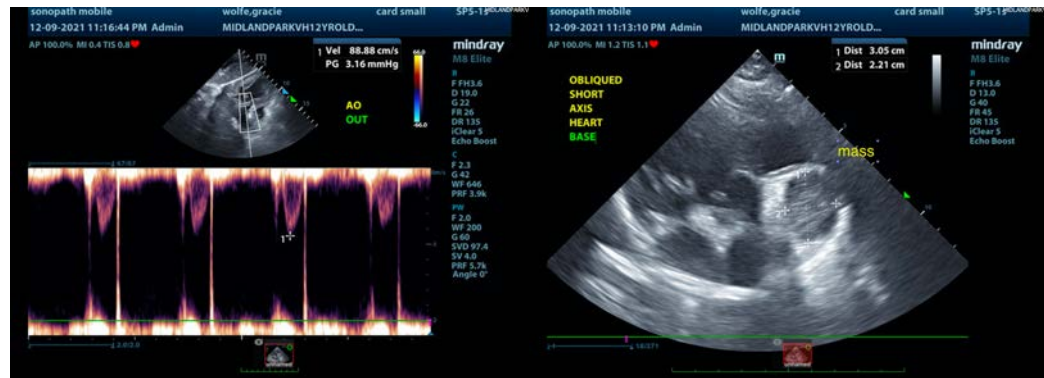
Dr. John Shokoff

INVOICE

33374

DATE

12/9/21



The information and recommendations provided are based on the images presented by the referring veterinarian. No evaluation can be communicated regarding pathology that was not visible in the image/video clips provided.

Thank you for this referral. If the clinical or image interpretation does not parallel your findings or if I can be of any further assistance please contact me.

Eric Lindquist, DMV, DABVP, Cert. IVUSS, CEO of SonoPath.com
info@SonoPath.com