



**PATIENT**

**PRESENTING CLINICAL SIGNS**

Ellie Sosely

History: Littermate Dx w/renal dysplasia. Persistently low SG

**SPECIES**

Canine

**ULTRASONOGRAPHIC EXAMINATION OF THE ABDOMEN**

**Urinary System**

**BREED**

Shepherd Mix

The **urinary bladder**, trigone, and pelvic urethra presented normal thicknesses and normal tone. The ureters were not visible which is normal. No uroliths or sediment were visualized and anechoic urine was present. No evidence of inflammatory or neoplastic changes was noted. Ureteral papillae were normal.

**SEX**

Female

The uterus was uniform with no evidence of pathology. The uterus measured 0.5 cm. The ovaries were uniform and measured 0.5 cm each.

**AGE**

6 months

The **kidneys** revealed normal size and structure, corticomedullary definition and ratio for this age. The cortices presented largely uniform texture with normal echogenic relationship to liver and spleen. Medullary structure differed distinctly from the cortex and no evidence of pelvic dilation was present. The capsules were acceptably uniform without significant irregularities. The right kidney measured 6.83 cm. The left kidney measured 6.36 cm.

**WEIGHT**

47 lbs

**Adrenal Glands**

Both **adrenal glands** were visualized and recognized as having normal shape, size, position and echogenicity for this breed. The phrenic vasculature, glandular echogenicity and detail were unremarkable. Capsule, cortex, and medullary definition were normal for this age patient. The right adrenal gland measured 1.73 x 1.05 cm at the cranial pole and 0.59 cm at the caudal pole. The left adrenal gland measured 2.34 x 0.34 cm at the cranial pole and 0.58 cm at the caudal pole.

**INTERPRETED BY**

Eric Lindquist, DMV  
DABVP, Cert. IVUSS

**IMAGING PERFORMED BY**

Shari Reffi, CVT

**Spleen**

The **spleen** presented a smooth homogeneous parenchyma hyperechoic to liver and renal cortical parenchyma. The capsule was smooth without noticeable expansion or deviation from within the spleen or adjacent pathology. The splenic vasculature demonstrated normal volume without signs of congestion or thrombosis. No sonographic evidence of acute or chronic inflammatory, neoplastic, or infarctual changes was noted.

**HOSPITAL NAME**

Rockaway

**REFERRING VET**

Dr. Kahn

**Liver**

The **liver** images submitted revealed subjectively normal liver size, contour, and structure. Parenchymal echogenicity was naturally coarse and hypoechoic to the spleen. Vascular and biliary tracts were of normal volume with no evidence of congestion. The gallbladder presented acceptably thin walls with primarily anechoic content. The cystic and common bile ducts were normal. No pathological hepatic lymphadenopathy was evident. No overt structural evidence of inflammatory, infiltrative or regenerative pathology was evident.

**INVOICE**

94442

**DATE**

12/9/21



**PATIENT**

**Gastrointestinal**

Ellie Sosely

The **stomach** was filled with progressively shadowing ingesta. Foreign matter is possible if the patient was n.p.o. at the time of the sonogram. The small intestine and colon were unremarkable.

**SPECIES**

Canine

**Pancreas**

**BREED**

Shepherd Mix

The base and limbs of the **pancreas** were observed to be largely isoechoic to surrounding omental fat. Pancreatic duct and capsular contour were acceptably normal and parenchyma respected normal curvilinear patterns. No overt evidence of active inflammatory or neoplastic disease was noted.

**SEX**

Female

**ULTRASONOGRAPHIC FINDINGS**

Structurally unremarkable abdomen.

**AGE**

6 months

**INTERPRETATION OF THE FINDINGS & FURTHER RECOMMENDATIONS**

There was no evidence of congenital disease or cause of isosthenuria. Partial water deprivation test is recommended to assess the ability to concentrate.

**WEIGHT**

47 lbs

**INTERPRETED BY**

Eric Lindquist, DMV  
DABVP, Cert. IVUSS

**IMAGING PERFORMED BY**

Shari Reffi, CVT

**HOSPITAL NAME**

Rockaway

**REFERRING VET**

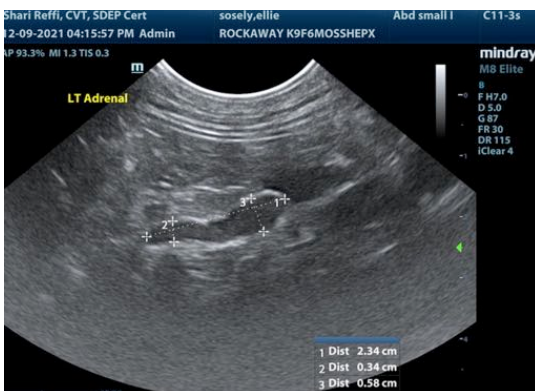
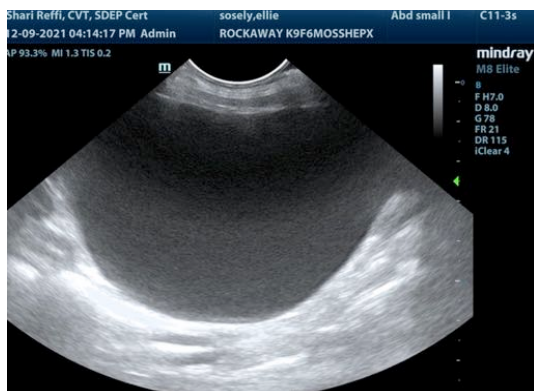
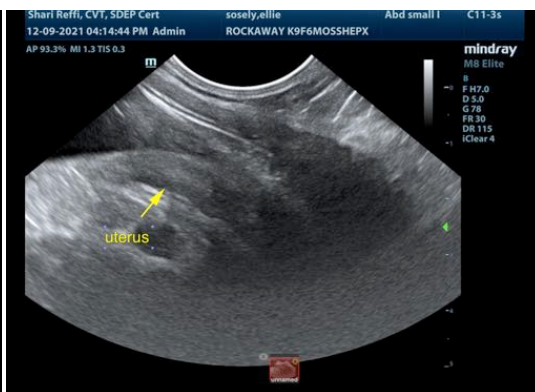
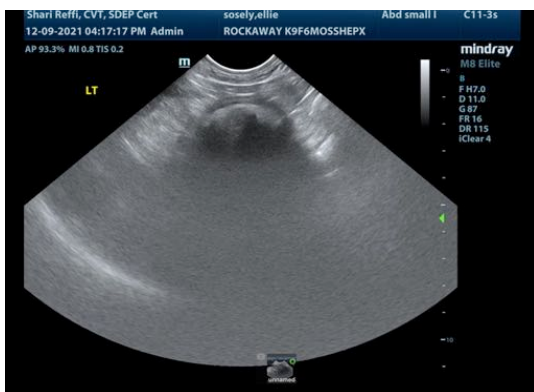
Dr. Kahn

**INVOICE**

94442

**DATE**

12/9/21





**PATIENT**

Ellie Sosely

**SPECIES**

Canine

**BREED**

Shepherd Mix

**SEX**

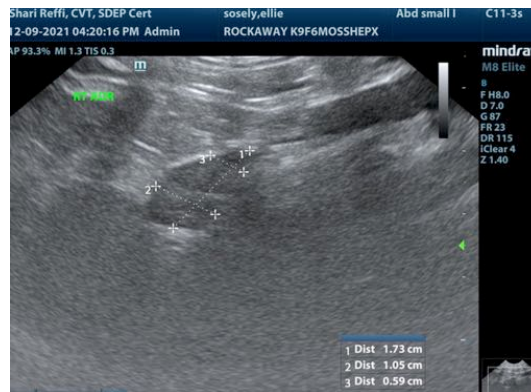
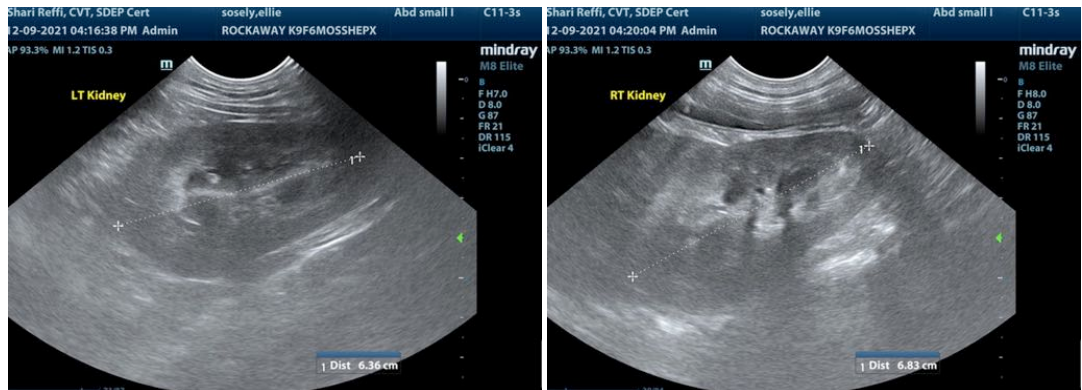
Female

**AGE**

6 months

**WEIGHT**

47 lbs



**INTERPRETED BY**

Eric Lindquist, DMV  
DABVP, Cert. IVUSS

**IMAGING PERFORMED BY**

Shari Reffi, CVT

**HOSPITAL NAME**

Rockaway

**REFERRING VET**

Dr. Kahn

**INVOICE**

94442

**DATE**

12/9/21

The information and recommendations provided are based on the images presented by the referring veterinarian. No evaluation can be communicated regarding pathology that was not visible in the image/video clips provided.

Thank you for this referral. If the clinical or image interpretation does not parallel your findings or if I can be of any further assistance please contact me.

**Eric Lindquist**, DMV, DABVP, Cert. IVUSS, CEO of SonoPath.com  
Info@SonoPath.com